

The Guidebook to Molar Endodontics

Ove A. Peters
Editor

 Springer

مرکز تخصصی پروتزهاک دندان

هاک دنت

طراحی و ساخت انواع پروتزهای دندانی بویژه ایمپلنت

برگزار کننده دوره های آموزشی تخصصی و جامع دندانسازی و...

با ما همراه باشید...

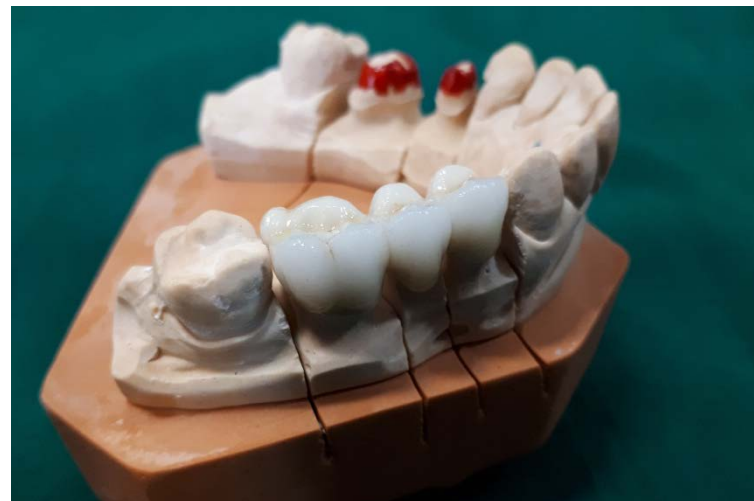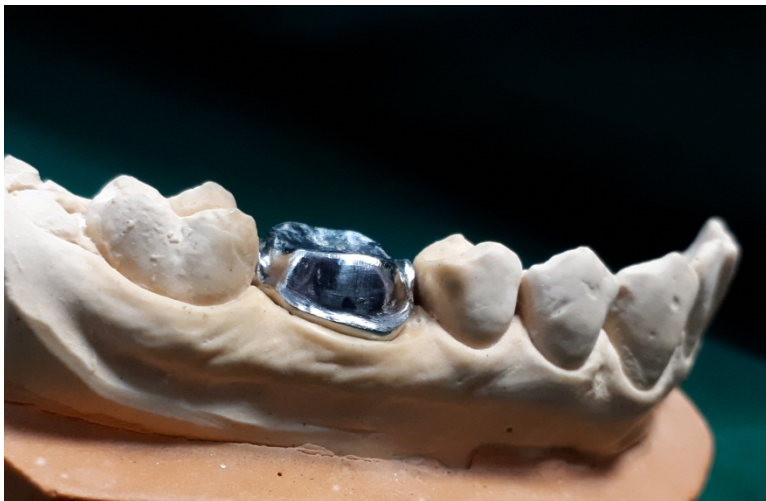WWW.HIGHDENT.IR



@highdent



@highdent



Ove A. Peters
Editor

The Guidebook to Molar Endodontics

Editor

Ove A. Peters
Department of Endodontics
University of the Pacific Arthur A. Dugoni School of Dentistry
San Francisco
California
USA

ISBN 978-3-662-52899-0 ISBN 978-3-662-52901-0 (eBook)
DOI 10.1007/978-3-662-52901-0

Library of Congress Control Number: 2016958572

© Springer-Verlag Berlin Heidelberg 2017

This work is subject to copyright. All rights are reserved by the Publisher, whether the whole or part of the material is concerned, specifically the rights of translation, reprinting, reuse of illustrations, recitation, broadcasting, reproduction on microfilms or in any other physical way, and transmission or information storage and retrieval, electronic adaptation, computer software, or by similar or dissimilar methodology now known or hereafter developed.

The use of general descriptive names, registered names, trademarks, service marks, etc. in this publication does not imply, even in the absence of a specific statement, that such names are exempt from the relevant protective laws and regulations and therefore free for general use.

The publisher, the authors and the editors are safe to assume that the advice and information in this book are believed to be true and accurate at the date of publication. Neither the publisher nor the authors or the editors give a warranty, express or implied, with respect to the material contained herein or for any errors or omissions that may have been made.

Printed on acid-free paper

This Springer imprint is published by Springer Nature
The registered company is Springer-Verlag GmbH Berlin Heidelberg

Preface

Dear reader:

You may think, “Why another textbook on endodontics?” and you are absolutely right to ask that question. The purpose of this book is in my view a bit different from a typical textbook, and hopefully this becomes apparent when you read it.

Historically, the intention of a guidebook, according to several dictionaries that I consulted, was to give information to travelers. Regardless of whether you are a seasoned clinician or a beginner, you may want to travel deeper into molar endodontics, and this book intends to give you support in your decision-making and execution of the treatment plan.

The idea for this book was born out of several pertinent findings in discussions with endodontists, residents, general dentists, and fellow faculty members:

- Do we teach molar endodontics sufficiently to dental students or should they take additional training to perform this procedure?
- Are modern technological developments, such as the use of the operating microscope or cone beam computed tomography (CBCT), essential to successful molar endodontics?
- Is avoiding a gross mistake as important as doing the little things right in achieving success?

The latter question came to the forefront when I considered the use of checklists for clinical procedures [1]. While it would be dangerous to oversimplify endodontics, it surely helps to step back occasionally and make sure that the right thing is done. Better yet, one would like to use clinical evidence whenever available to support the course of action.

This is the reason that each chapter in this book has a number of references but also one key citation that can help to directly address a clinical quandary. With this comes the need to reevaluate the standard of practice periodically to include new and pertinent information.

This task would be insurmountable if it were not for my coauthors who were each responsible for a chapter in this book; I cannot thank each of them enough. From a clinical standpoint, there are several key principles that can be cited for procedural success in root canal therapy. The term “procedural success” is in my view related to what the clinician can do to promote best patient-related outcomes.

It is my impression that outcomes in endodontics are discussed more and more in a broader sense beyond the treatment of apical periodontitis; this is helpful so that we are not primarily focusing on radiographically confirmed resolution of apical bone defects but considering other outcomes that are relevant for our patients [2].

At a time where CBCT permits real-time imaging of apical conditions, without clearly defining what a normal periradicular space looks like, an assessment of our strategies is in order. I happen to believe the next step in this diagnostic paradigm will be molecular tests for pulpal and periapical conditions.

Obviously, the practice of dentistry varies from country to country, continent to continent, perhaps based on fee schedules and educational systems. This prompted me to solicit the help of well-educated clinician-researchers with diverse backgrounds for each of the central issues discussed in this book, ranging from molar anatomy over diagnosis and clinical treatment to outcome assessment, retreatment, and surgery.

It is my hope that you will enjoy the text as much as the supporting material in bullet points and images and, ultimately, go on to travel the road to successful molar endodontics.

San Francisco, CA, USA

Ove A. Peters, DMD, MS, PhD

References

1. Gawande A. The checklist manifesto: how to get things right. New York: Metropolitan Books; 2009.
2. Azarpazhooh A, Dao T, Ungar WJ, Da Costa J, Figueiredo R, Krahn M, Friedman S. Patients' values related to treatment options for teeth with apical periodontitis. J Endod. 2016;42:365–70.

Acknowledgments

At this point, I must thank all involved in my career for their interest and enthusiasm for root canal treatment and all other aspects of endodontology; specifically, I am grateful for the guidance and support from my mentors Dr. Fred Barbakow, Dr. Harold Goodis, and Dr. Alan Gluskin.

I am greatly indebted to my coauthors and editors—their invaluable contributions made this book possible.

Most importantly, I would like to express my gratitude to my parents who started me in life with their attitude of hard work, curiosity, and support for whatever new project I came up with. Last but not least, my thanks go to my wife Christine. She is not only an educator and endodontist in her own right but also my favorite line editor; this book would not have been possible without her understanding and practical help.

Contents

1 Molar Root Canal Anatomy	1
Frank Paqué	
2 Diagnosis in Molar Endodontics	27
David E. Witherspoon and John D. Regan	
3 Local Anesthesia	75
John M. Nusstein	
4 Vital Pulp Therapy for Permanent Molars	93
Lars Bjørndal	
5 Molar Access	117
Frank C. Setzer and Helmut Walsch	
6 Shaping, Disinfection, and Obturation for Molars	133
Ove A. Peters and Ana Arias	
7 Considerations for the Restoration of Endodontically Treated Molars	169
Julian G. Leprince, Gaetane Leloup, and Chloé M.F. Hardy	
8 The Outcome of Endodontic Treatment	207
Thomas Kvist	
9 Nonsurgical Root Canal Retreatment	233
Elio Berutti and Arnaldo Castellucci	
10 Endodontic Microsurgery for Molars	269
Enrique M. Merino	
Index	293

Contributors

Ana Arias, DDS, MS, PhD Conservative Dentistry, School of Dentistry, Complutense University, Madrid, Spain

Elio Berutti, MD, DDS Department of Endodontics, University of Turin, Turin, Italy

Lars Bjørndal, PhD Section of Cariology and Endodontics, Department of Odontology, Faculty of Health and Medical Sciences, University of Copenhagen, Copenhagen, Denmark

Arnaldo Castellucci, MD, DDS University of Naples Federico II, Naples, Italy, University of Cagliari, Cagliari, Italy

Private Practice, Florence, Italy

Chloé M.F. Hardy, DDS School of Dentistry, Cliniques Universitaires Saint Luc – Université catholique de Louvain, Brussels, Belgium

Thomas Kvist, PhD, DDS Department of Endodontology, Institute of Odontology, The Sahlgrenska Academy, University of Gothenburg, Gothenburg, Sweden

Gaetane Leloup, DDS, PhD School of Dentistry, Cliniques Universitaires Saint Luc – Université catholique de Louvain, Brussels, Belgium

Julian G. Leprince, DDS, PhD School of Dentistry, Cliniques Universitaires Saint Luc – Université catholique de Louvain, Brussels, Belgium

Enrique M. Merino, MD, DDS European University, Madrid, Spain, Complutense University, Madrid, Spain

Private Practice, Leon, Spain

John M. Nusstein, DDS, MS Division of Endodontics, The Ohio State University College of Dentistry, Columbus, OH, USA

Frank Paqué, DMD, MSc Department of Preventive Dentistry, Periodontology and Cariology, University of Zurich Center for Dental Medicine, Zurich, Switzerland

Private Practice, Zurich, Switzerland

Ove A. Peters, DMD, MS, PhD Department of Endodontics, University of the Pacific, Arthur A. Dugoni School of Dentistry, San Francisco, CA, USA

John D. Regan, BDentSc, MA, MSc, MS, FICD Department of Endodontics, Texas A&M, University Baylor College of Dentistry, Dallas, TX, USA
North Texas Endodontic Associates, Plano, TX, USA

Frank C. Setzer, DMD, PhD, MS Department of Endodontics, Penn Dental Medicine, Philadelphia, PA, USA

Helmut Walsch, DMD, PhD, MS Department of Endodontics, Penn Dental Medicine, Philadelphia, PA, USA

Private Practice, Munich, Germany

David E. Witherspoon, BDS, MS, MFA, FICD Department of Endodontics, Texas A&M University Baylor College of Dentistry, Dallas, TX, USA
North Texas Endodontic Associates, Plano, TX, USA

Molar Root Canal Anatomy

1

Frank Paqué

Abstract

Detailed understanding of root and root canal anatomy is the main prerequisite for successful molar endodontics. Besides typical three-rooted and two-rooted configurations for maxillary and mandibular teeth, respectively, there are specific variations such as merged roots, additional roots, and completely different shapes such as the C-shaped molars. Adding complexity, frequently small accessory canals are found that can contribute to periapical pathosis.

Guiding Reference

Stropko JJ. Canal morphology of maxillary molars: clinical observations of canal configurations. *J Endod.* 1999;25:446–50.

This clinical study on first and second maxillary molars treated over an 8-year period was made in an attempt to determine the percentage of second mesiobuccal (MB2) canals that could be located routinely. 1732 maxillary molars were treated and overall, the MB2 canal was found in about 73% first molars, 51% second molars, and 20.0% third molars. It occurred as a separate canal in about 55% of first molars, 45.646% of second molars, and joined in all third molars. However, as the operator became more experienced, scheduled sufficient clinical time, routinely employed the dental operating microscope, and used specific instruments adapted for microendodontics, MB2 canals were located in about 93% of first molars and 60% in second molars.

F. Paqué, DMD, MSc
Department of Preventive Dentistry, Periodontology and Cariology,
University of Zurich Center for Dental Medicine, Zurich, Switzerland
Private Practice, Rennweg 58, 8001 Zurich, Switzerland
e-mail: frank.paque@zzm.uzh.ch

1.1 Introduction

A central goal of cleaning and shaping procedures in endodontics is to obtain a debrided root canal system that is in its entirety free of microbiota and debris. Therefore, detailed knowledge about root canal anatomy prior to any access to the root canal system is absolutely mandatory [1]. Moreover, complex root canal anatomy in molar roots should be expected in every single case. Root and root canal anatomy directly impacts practice and procedures for access cavity preparation, canal shaping and obturation, and in fact most procedures in molar endodontics (see Chaps. 5, 6, 7, 9, and 10 in this book).

It is well established that intraradicular microflora is the main cause for developing, or persisting, apical periodontitis [2]. Unfortunately, the intraradicular infection mainly consists not of planktonic bacteria but of well-organized biofilms. The bacteria in biofilms show a higher pathogenicity compared to their planktonic counterparts [3]. More than 400 different bacterial species were found in root canal systems of teeth with necrotic pulps [4]. Interactions between different species within endodontic biofilms lead to enhanced stress resistance [5]. Their location within complex molar root canal configurations makes complete eradication of endodontic biofilms virtually impossible; even reducing the microbial burden below a biologically acceptable threshold demands careful canal debridement. It is safe to say that in depth understanding of root canal anatomy is of utmost importance for successful molar endodontics.

1.2 Components of the Root Canal System and Classifications

In roots with round cross-sectional shapes, the number of root canals corresponds in most cases to the number of roots. However, an oval shaped root may have more than one canal [1]. The immense complexity of molar canal configurations is based on a wide range of root canal curvatures, different root canal sections, different accessory canals, fins, and isthmuses. Different attempts of classification contributed to a deeper understanding of root canal anatomy. There are numerous classifications for anatomical variations in root canals. Weine and coworkers [6] examined in a laboratory study the mesiobuccal roots of maxillary molars and classified these into four and later into five types as shown in Fig. 1.1.

A more detailed classification is recommended to more accurately describing the internal root canal configurations of individual molar roots. One of the most commonly used classifications is the one by Vertucci [7] with eight different canal morphologies (Fig. 1.2a).

However, if there are more than two canals within one root, this classification again is limited. Gulabivala et al. [8] further developed this classification to additional nine morphology types. Especially for describing the root canal formation of the mesial root in mandibular molars types 1, 2, and 3 of this classification is meaningful (Fig. 1.2b).

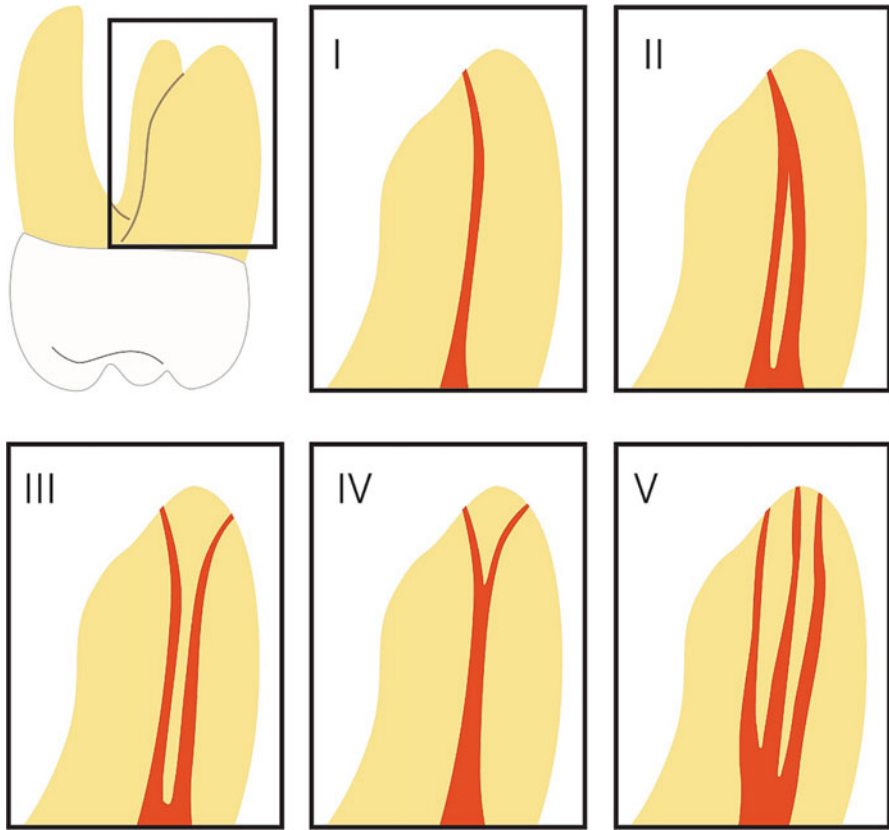


Fig. 1.1 Classification of multiple canals in one root by Weine et al. [6]. The original classification of four types was later expanded to the five configurations shown

Another research group [9] extended Vertucci's classification with additional 14 configurations examining 2800 extracted human teeth. These further developments contribute to the understanding of substantial complexity in root canal configuration.

1.3 Complexity of Root Canal Systems

As Vertucci [1] stated, a root with a tapering canal and a single foramen is the exception rather than the rule. Great complexity of root canal anatomy can be found at every level of the root canal space. It is the result of tooth development mainly after eruption of the tooth to the oral cavity and apical closing [10] due to the apposition of secondary dentin. The primary apposition of root dentin has determined the external shape of the root, and therefore the internal shape will be the very similar: if the external shape is round, the canal will also be round; if the external shape is long oval or kidney shaped, the canal will be long oval or kidney shaped too.

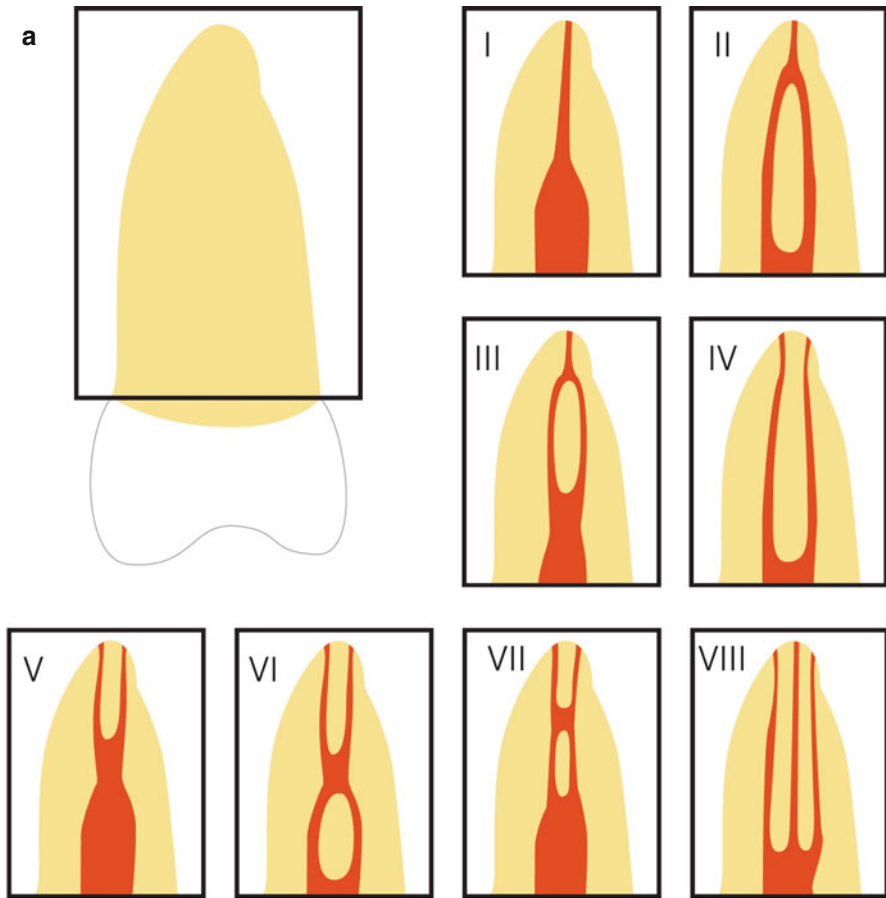


Fig. 1.2 Expanded root canal classifications by Vertucci [7] (eight types) (a) and by Gulabivala et al. [8] (seven types) (b)

Kidney-shaped roots, like in mandibular molars, mainly develop two root canals (Fig. 1.3).

For example, in mandibular first and second molars the root canal systems were completely defined at 30–40 years of age [10]. Various intercanal communications can still remain and represent one main component of complex root canal anatomy (Fig. 1.3). Others are wide ranges of root canal curvatures, different root canal cross sections, accessory canals, secondary canals, lateral canals, furcation canals, fins and multiple apical foramina, and so-called apical deltas.

More than two decades ago when rotary Nickel-Titanium instruments were introduced to the endodontic market, root canal curvatures have been stated as one of the most common endodontic complexity [11]. With the further development of these instruments and the experience gained by the practitioners, the difficulties of shaping even severely curved root canals have mainly been overcome over the past

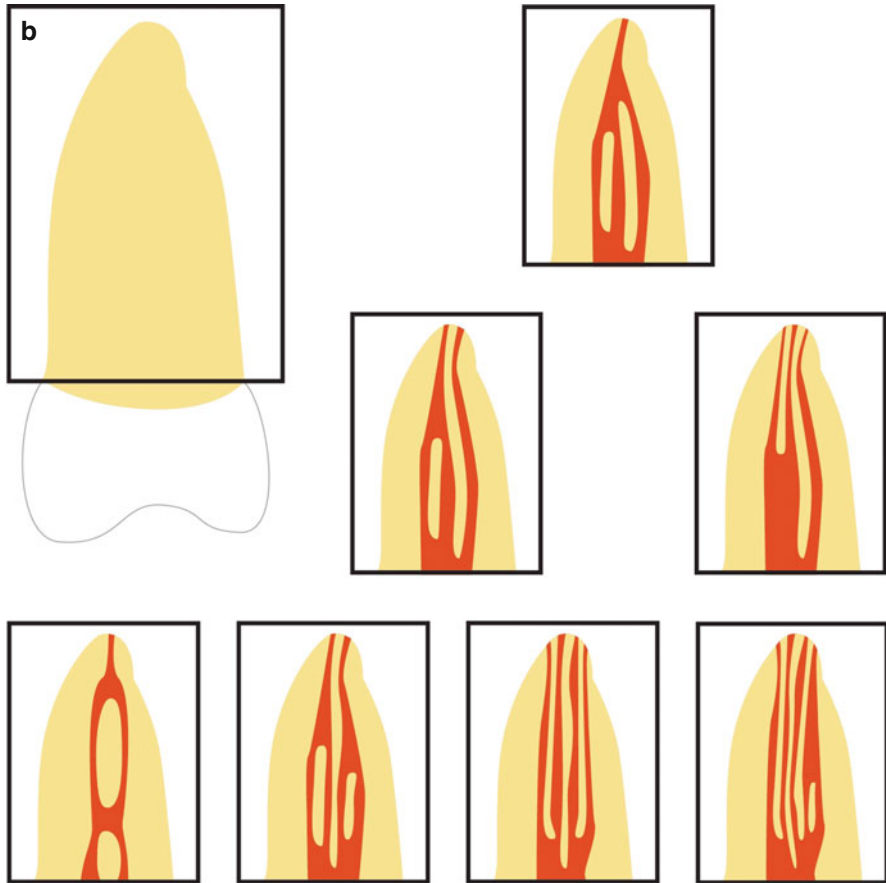


Fig. 1.2 (continued)

few years (Fig. 1.4). Taking into consideration that complex root canal systems require proper cleaning and disinfection, the main challenge remains to debride the spaces of the root canal system that cannot be reached by mechanical instrumentation. Especially in mandibular and maxillary molars, the above-mentioned components of complex root canal anatomy are a common finding. In a literature review about tooth survival after nonsurgical root canal treatments [12], the tooth type or specifically nonmolar teeth were found to significantly increase tooth survival.

1.4 The Anatomy of Maxillary Molars

A sufficient root canal treatment in maxillary molars is based on an optimal access to and preparation of all existing root canals. The goal of the treatment is to present the existing anatomy as comprehensive as possible and to widen the root canal system to

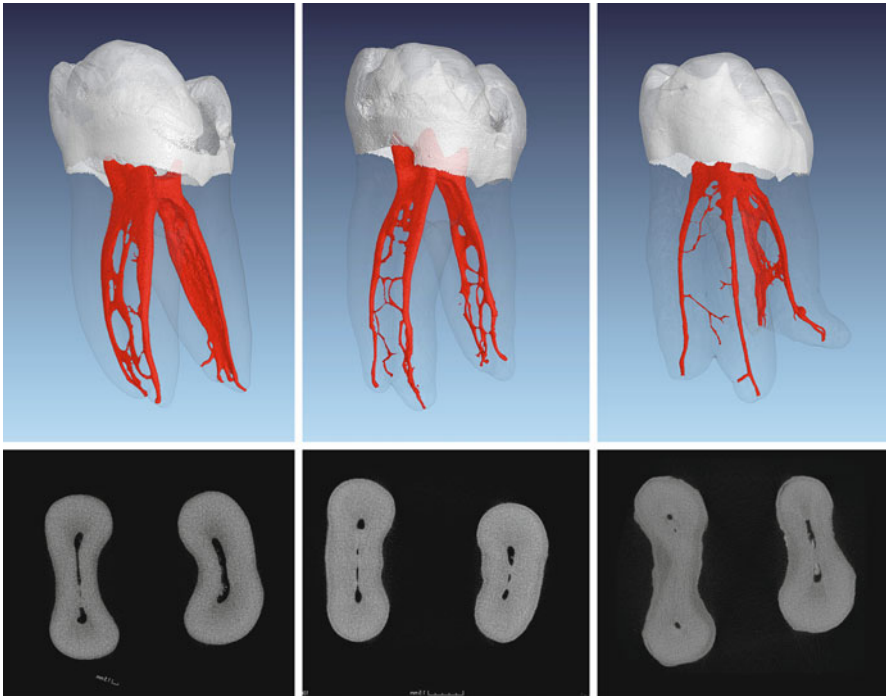


Fig. 1.3 Micro-computed tomography images of extracted teeth from patients of different ages. Three-dimensional reconstructions and corresponding cross sections from the middle third of the roots are shown. Images from *left to right*: extracted tooth of a young-aged, middle-aged, and older patient, respectively. Note the width of the main canals and the number and size of various ramifications and communications

enable a sufficient disinfection and filling. The anatomy of maxillary molars is very complex and the root canal treatment of this particular group of teeth represents a major challenge for dentists [1]. Carabelli documented the particular anatomy of maxillary molars as early as 1844 [13]. Numerous subsequent publications discussed the complexity of maxillary molar anatomy; most often the mesiobuccal root and the occurrence of a second mesiobuccal (MB2) canal have been in the main focus. In 1917, Walter Hess [14] presented the anatomical complexities with multitude of branches and accessory canals by illustrating in detail the number and formation of root canals. He was the first to relate age and gender of the patients to root canal complexity.

Many studies have shown the anatomy of the upper first molar and especially the presence of a MB2 canal using different techniques [15]. Failures in root canal treatment of this tooth type are often based on untreated MB2 canals [6, 16]. The clinical prevalence of the MB2 canal in maxillary first molars and in second molars is reported up to 93% and 60%, respectively [17].

Results from laboratory micro-computed tomography (micro-CT) studies are of special interest for molar anatomy, because this technique allows a three-dimensional presentation and analysis of the root canal system without damaging the tooth

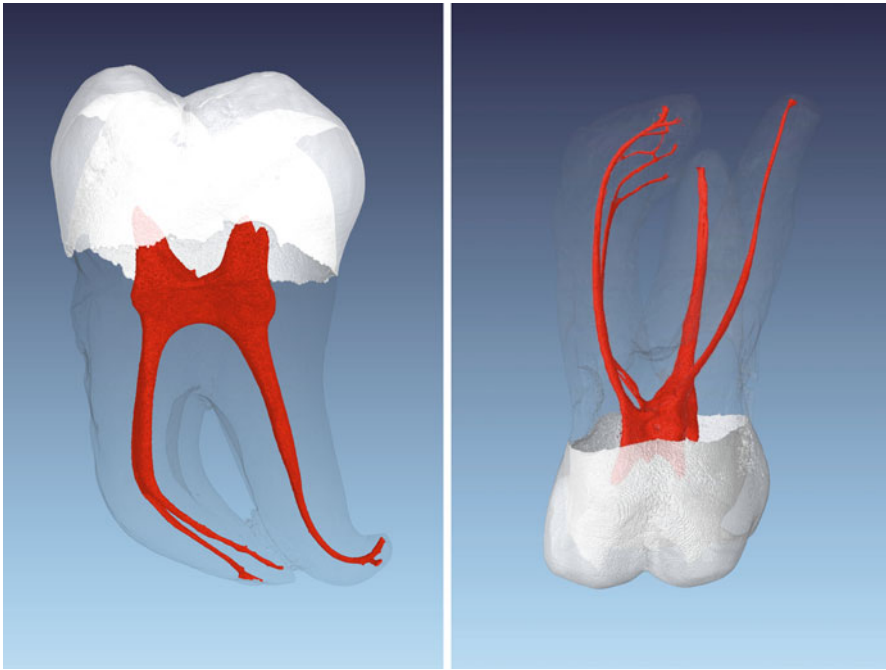


Fig. 1.4 Micro-computed tomography images of an extracted mandibular and a maxillary molar. Note the severe canal curvatures in both roots of the mandibular molar and in the MB root of the maxillary molar

structures [18]. Due to modern treatment methods like the use of dental microscopes, options for a successful therapy of difficult root canal anatomies have significantly improved [19]. The location of MB2 canals during root canal treatment of maxillary molars is much more likely by applying the dental microscope and through the use of specialized tools than without [17].

The first maxillary molar is the most voluminous of all teeth: it has four pulp horns and the pulp chamber has usually a rhomboid cross-sectional shape [1]. The second maxillary molar in principle is of similar shape (Fig. 1.5a). However, the pulp chamber is often more long oval, sometimes it is ribbon shaped (Fig. 1.5b).

A maxillary first molar has typically three separate roots and in only about 4% of the cases just two roots are found. Two or more merged roots occur in about 5% of all cases. The presence of four roots is extremely rare [15]. In second maxillary molars, merging of roots is much more common. Interestingly, the distobuccal (DB) root canal in second maxillary molars is often difficult to negotiate because an S-shaped DB root is a quite common finding.

Cleghorn et al. [15] evaluated laboratory studies from the years 1914 to 2004 in a literature review of the anatomy of the first maxillary molar. The occurrence of a MB2 was reported to range from 25 to 96%. Pooled data of 21 studies gave an overall prevalence of roughly 60%.

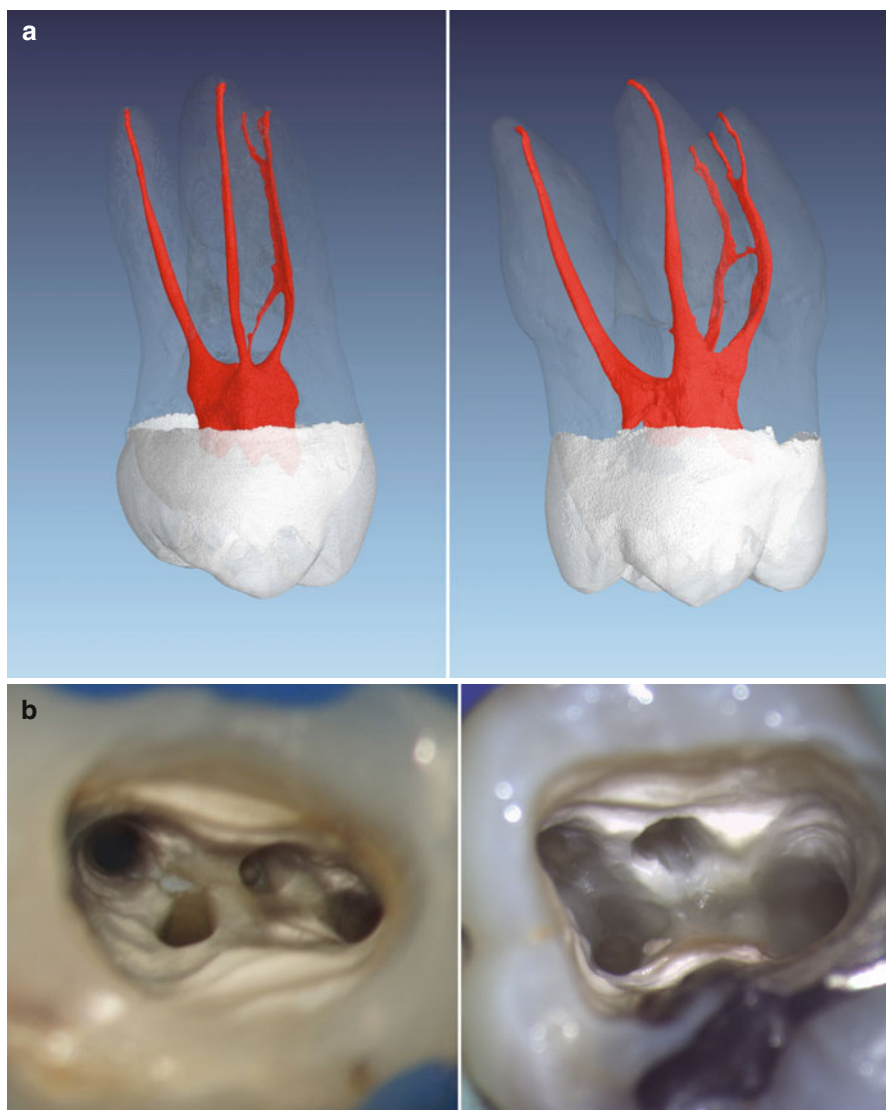


Fig. 1.5 (a) Micro-computed tomography images of an extracted first (*right*) and second maxillary molar (*left*). Note the in general similar shape but the overall smaller volume of the second maxillary molar. Typically, the buccal roots of the second maxillary molar seem to be fused. (b) Clinical images of cases after preparation of all canals in a first (*right*) and second (*left*) maxillary molar with rotary instruments. The access cavities provide an overview of all four canal orifices. Note the ribbon-shaped pulpal floor in the second maxillary molar, the entrance of MB2 is located very close to the palatal orifice, a common finding in these kinds of teeth

It should be taken into consideration that literature data from laboratory studies on the prevalence of the MB2 canals are subject to strong variations due to differences in the experimental design. Thoroughly studying the description of the methods used in these publications is an absolute requirement if someone wants to rely on the found percentages of MB2 canals. Properly designed histological and micro-CT studies could be seen as a gold standard when examining the prevalence of the MB2 canal in extracted teeth. Considering such studies, a prevalence of more than 90% MB2 canals in the first and more than 55% MB2 canals in the second maxillary molars should be accepted as clinical reality. Figure 1.6 shows the clinical negotiation of MB2 in a retreatment case with corresponding CBCT imaging.

This division of the mesiobuccal root canal can take place at different levels and initiate various configurations. Again, it is the result of the apposition of secondary dentin after the formation of the mesiobuccal root. After root formation, the cross section of the mesiobuccal canal resembles a kidney shape with a larger buccal and a smaller palatal part. This explains the smaller diameter of the MB2 canal after the deposition of secondary dentin [20]. Neaverth and coworkers found the prevalence of a second mesiobuccal canal in under 20-year-olds significantly lower than in an age group of 20–40-year-old patients [21].

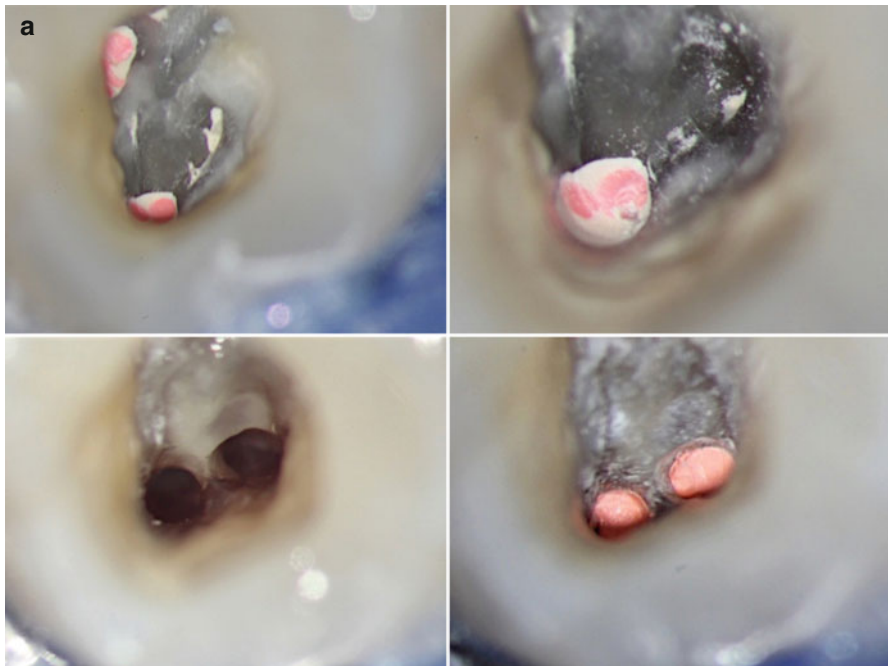


Fig. 1.6 (a) Clinical image during endodontic retreatment of a first maxillary molar with untreated MB2. The location identification of MB2, the access, preparation, and also filling of the canal system after retreatment of MB1 is shown. (b) Corresponding CBCT scan prior to retreatment of the first maxillary molar is shown in (a). Note the unprepared and unfilled MB2 depicted in different slices of the original dataset (*arrows*)

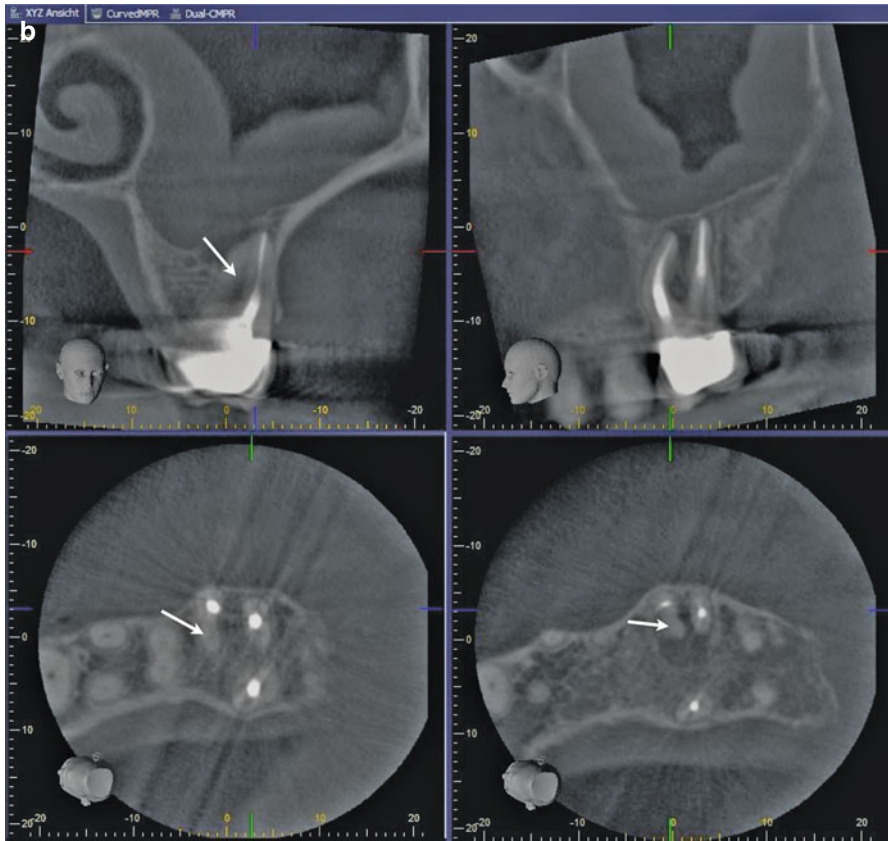


Fig. 1.6 (continued)

Due to the secondary dentin apposition, a third mesiobuccal (MB3) root canal could develop (Fig. 1.7). Most often, two of the three canals join somewhere on their travel to the apex (Fig. 1.7a). In the literature, three mesiobuccal root canals have been described to occur up to 7% in first maxillary molars [22].

If there are two or more MB root canals, the location on the pulp chamber floor varies greatly; however, the orifice of MB2 is consistently located mesial to or directly on a line between the MB1 and the palatal orifices within about 3.5 mm palatally and 2 mm mesially from the MB1 orifices [23] (Fig. 1.5b).

Very often, the orifice of the MB2 canal is covered by a mesial shelf of dentin, which then needs to be removed to reveal access to this canal (see Chaps. 5 and 6). Below this ledge, the canal path leads toward mesiopalatal before curving back to the center and apically.

This makes the insertion or the negotiation of these canals very challenging. By removing these obstructions and carefully tracking the canal structure toward mesial and apical using ultrasonic tips or long-shank round burs (“troughing or countersinking”), a straight access to the MB2 canal is possible. It could be necessary to extend troughing 0.5–3 mm deep, which risks perforating the pulpal floor toward the furcation area [24]. During initial instrumentation and shaping of MB2 canals, there is the risk of

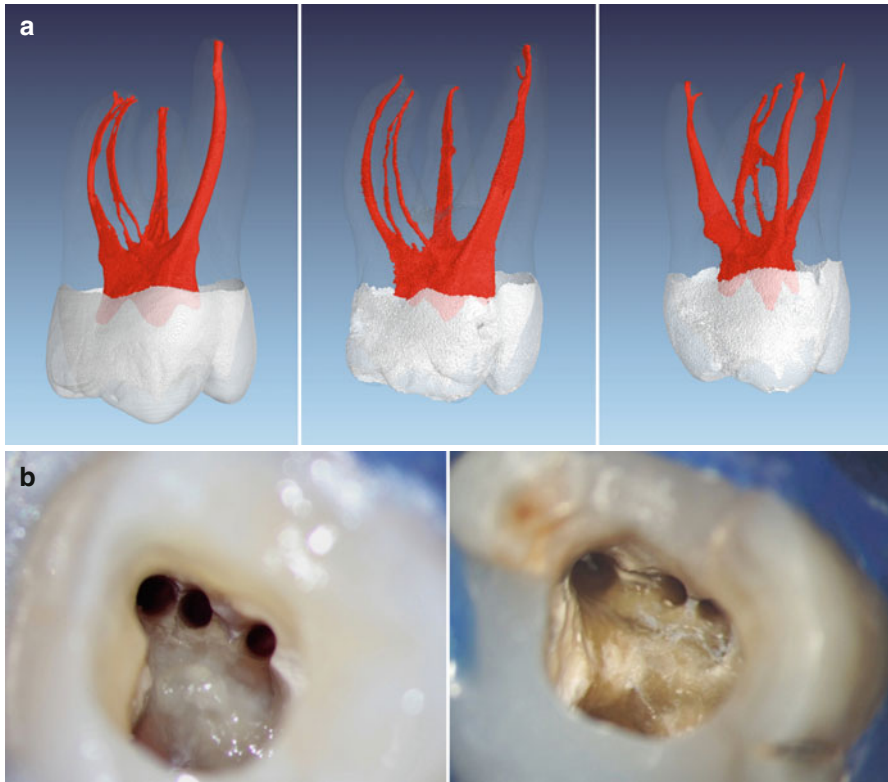


Fig. 1.7 (a) Micro-computed tomography images of three extracted first maxillary molars with three mesiobuccal root canals. Note that two of the extracted teeth show MB2 and MB3 joining on their travel to the apex (*left and middle*), while one of the extracted teeth shows a separate portal of exit (*right*). (b) Two clinical examples showing the mesiobuccal aspect of access cavities after preparation of three mesiobuccal root canals with rotary instruments

a strip-perforation because of the cross-sectional shape of the MB root (Fig. 1.8). A brushing movement toward the mesial aspect of the root is recommended [24].

Once we successfully manage to initially instrument the canal, a further challenge could be to reach the apical foramen in MB2 canals because of two reasons. First, these canals are often very narrow and curved. Second, the chance to encounter a Vertucci class V, VI, or VII in MB root systems is not uncommon (Fig. 1.2a). It remains a challenge for the clinician to recognize a deviation of the MB2 canal in the middle or apical third to the palatal aspect and to successfully prepare such deviations.

According to Vertucci [7], distobuccal roots of maxillary molars show one canal in 100% of the cases. Other authors described the occurrence of a second distobuccal canal in first maxillary molars with an incidence of 1.6–9.5%. However, in up to 98% of these cases, the two canals merge in one apical foramen and only 2% show two or more canals at the apex of the distobuccal root [15].

A rather rare variation of first maxillary molars is the C-shaped canal system, which is formed from merged distobuccal and palatal roots with a prevalence of 0.1% [25, 26].

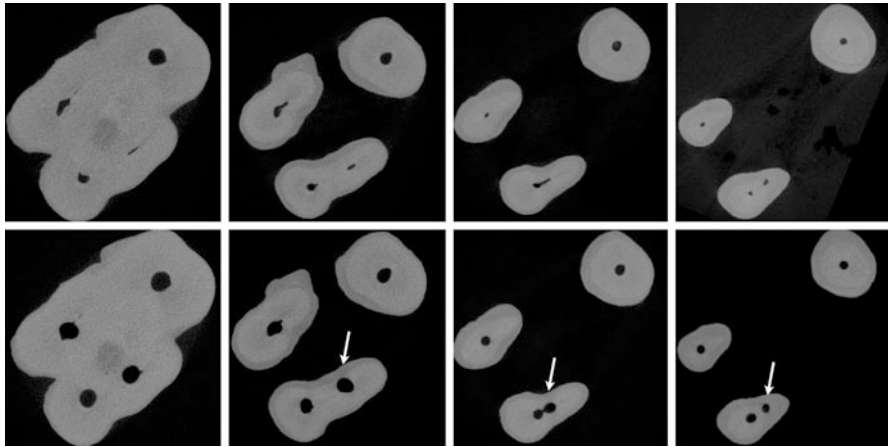


Fig. 1.8 Cross-sectional micro-computed tomography images of an extracted first maxillary molar before (*upper panel*) and after (*lower panel*) preparation with rotary instruments on four different root levels. Note the shape of the mesiobuccal root and limited radicular wall thickness before and after preparation (*arrows*)

1.5 The Anatomy of Mandibular Molars

The mandibular molars, in particular the mandibular first molar, are the most frequently endodontically treated teeth. Their treatment offers a variety of anatomical challenges. These complexities include multiple canals, isthmuses, lateral canals, and apical ramifications. Additionally, the distal dentinal wall of the mesial root is thin and known as the so-called danger zone [27, 28] (Fig. 1.9).

Harris et al. [28] scanned 22 first molars using micro-CT and showed that 1.5 mm below the furcation in the mesial root radicular wall thickness toward the furcation was smallest with values of 0.81–1.22 mm. Comparable results were obtained by others [29] showing an average dentin thickness of 1.2–1.3 mm measured also 1.5 mm beneath the furcation area.

Using the data from Harris et al. [28] regarding the pulp chamber floor, the shortest and longest distance between the orifices of the mesial canals averaged between about 1.4 and 3 mm. All scanned teeth in that study showed a single distal canal openings at the measured level 1.5 mm coronal to the furcation area, while there are two canals more apical more frequently [30]. The buccolingual dimension of the distal canal was about 2 mm. The average tangential distance from the mesial to the distal canals beneath the pulpal floor was about 4.5 mm.

1.5.1 Additional Roots in Mandibular Molars

In the Caucasian population, the majority of mandibular molars have two roots. An additional root is described as an exception. The presence of an additional distolingual root (*radix entomolaris*, Fig. 1.10) in mandibular first molars was observed and has been described occasionally [31].

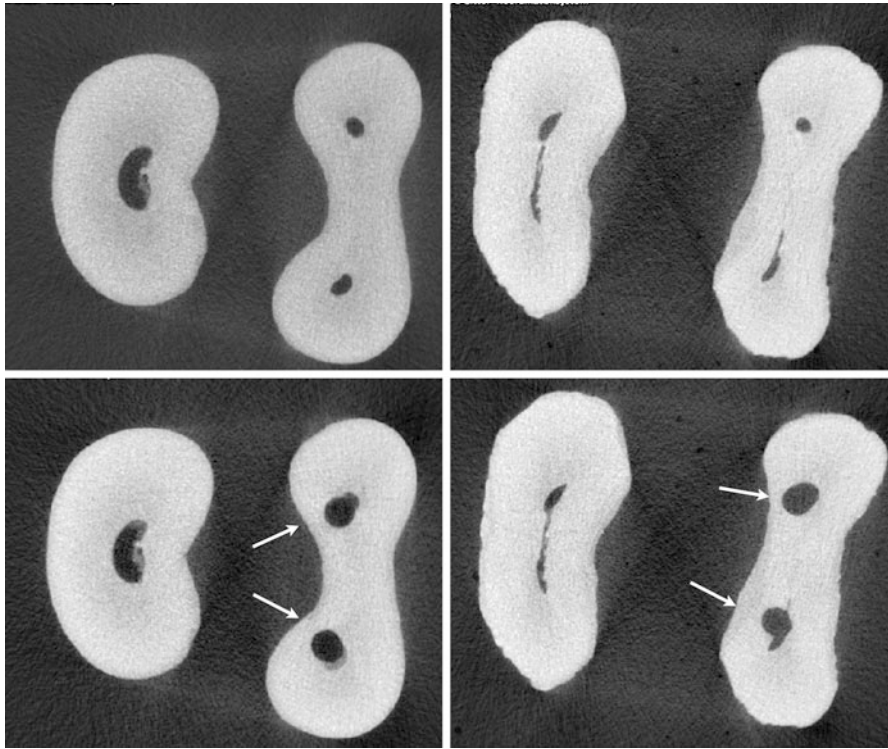
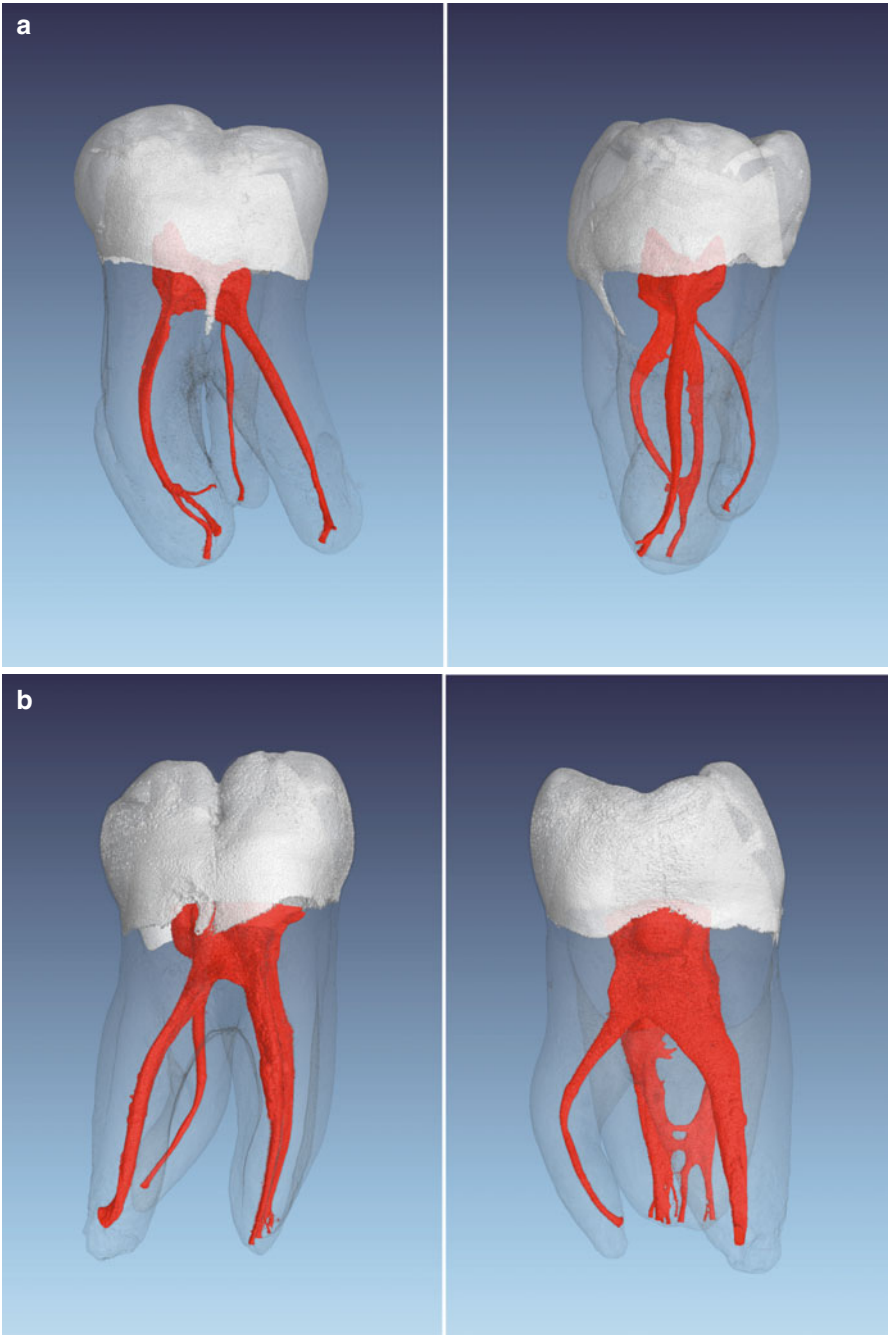


Fig. 1.9 Cross-sectional micro-computed tomography images of two extracted first mandibular molars before (*upper panel*) and after (*lower panel*) preparation with rotary instruments at a root level called the danger zone. Note the kidney shape of the mesial roots and radicular wall thickness before and after preparation (*arrows*)

An additional distolingual root was mentioned first by Carabelli in 1844 [13]. In a review, Abella et al. [32] described a frequency of 14.4% regarding distolingual roots in mandibular first molars. There was an association to specific ethnic populations. The additional root was found more frequently in populations with Mongolian origin, like Chinese, Inuit, and Native Americans [32]. Cantatore et al. [33] determined frequencies between 5% and more than 30% in a population with Mongolian origin. Gu et al. [34] found an occurrence of 32% in a Chinese population.

Gender-specific differences in the prevalence of an additional root were not recognized. The distolingual root is described either as separate or as partially merged into the other root. The distolingual root was classified according to their root curve in the buccolingual plane [32]:

- Type I: A straight root
- Type II: An initial curvature with a subsequent straight course
- Type III: An initial curvature in the coronal third of the root canal, followed by a second curvature in the middle portion, which proceeds to the apex (Fig. 1.10)



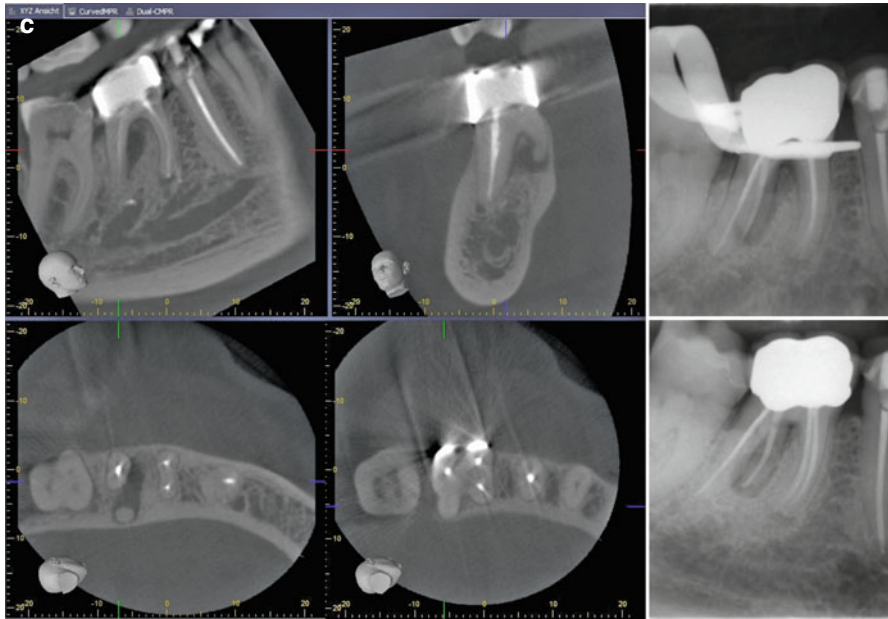


Fig. 1.10 (continued)

The radix entomolaris is usually smaller than the distobuccal root and has in general a larger angle and a smaller radius of curvature. This makes the preparation of these canals often a difficult task (Fig. 1.10c).

Three-rooted mandibular first molars exhibit usually four separate root canals and accessory canals in the mesial and DB root are found quite often [35]. The most common canal configuration was Vertucci type I for the distal root and Vertucci type IV for the mesial root [32, 35]. A recommended method for identifying a radix entomolaris was described as applying a mesio-eccentric (25°) periapical radiograph or a CBCT [32]. The conventional triangular access cavity should be modified to a trapezoidal shape in the presence of radix entomolaris to facilitate a straight access to the mostly curved root [31]. The average distance between the distolingual and the distobuccal canal opening was 2.93 mm and the average distance between the distolingual and mesiolingual canal opening was 2.86 mm [34]. The

Fig. 1.10 (a) Micro-computed tomography images of an extracted first mandibular molar with a radix entomolaris configuration (*left* in clinical view, *right* in approximal view). Note the root canal curvature in the approximal view. (b) Another example of micro-computed tomography images of an extracted first mandibular molar with a radix entomolaris (*left* in clinical view, *right* in approximal view). Note the root canal curvature in the approximal view. (c) Clinical retreatment case showing CBCT images of an untreated radix entomolaris with periapical pathosis. The patient was in severe pain at the first office visit. After negotiation and preparation of the untreated root, the patient was free of any symptoms

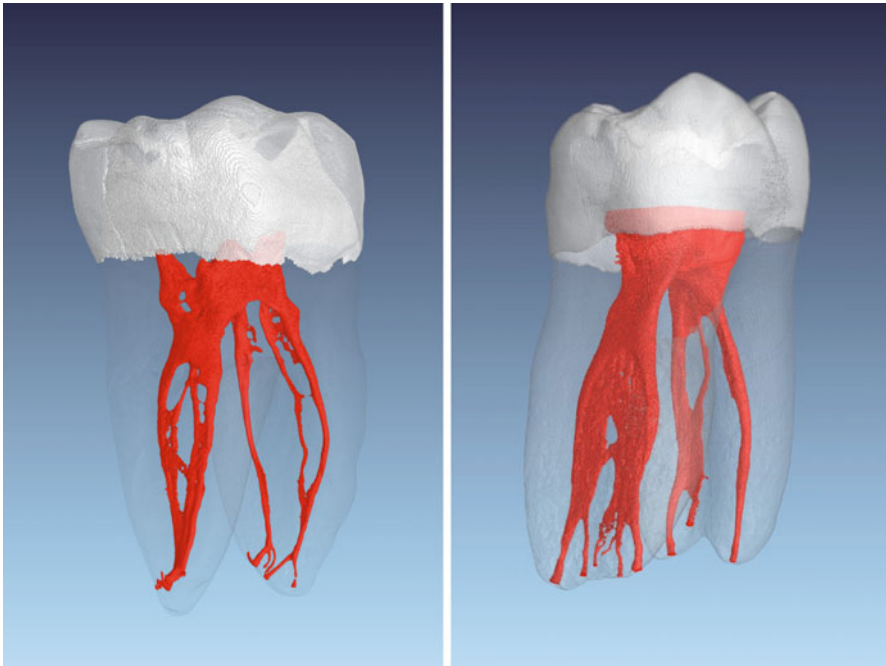


Fig. 1.11 Micro-computed tomography images of two extracted first mandibular molars with complex distal root canal anatomy. Note the various intercanal communications and the severe curvature to the distal aspect in the apical portion (*left*) and six portals of exits (*right*)

mesiobuccal, mesiolingual, and the distobuccal canal exhibited a more oval canal shape, whereas the distolingual canal revealed a relatively round canal shape [35]. The occurrence of an additional mesiobuccal root is called radix paramolaris. The frequency of a radix paramolaris is described with less than 0.5% [33].

1.5.2 Additional Root Canals

Three canals were reported in about 61%, four canals in 36%, and more than five canals only in approximately 1% [33]. In a systematic review [36] as well as reported earlier by Vertucci [7], the type IV configuration is the most frequently encountered canal configuration in the mesial root of first mandibular molars followed by type II. However, newer data generated by micro-CT showed even more complicated canal anatomy in mesial roots of mandibular first molars [28]. In about 9% of the studied teeth, even four canals were observed in some root sections of the mesial root.

In the distal root of mandibular first molars, type I configuration dominated (63%), followed by types II (15%) and IV (12%) [36]; again micro-CT studies showed a more complex image [30] (Fig. 1.11).

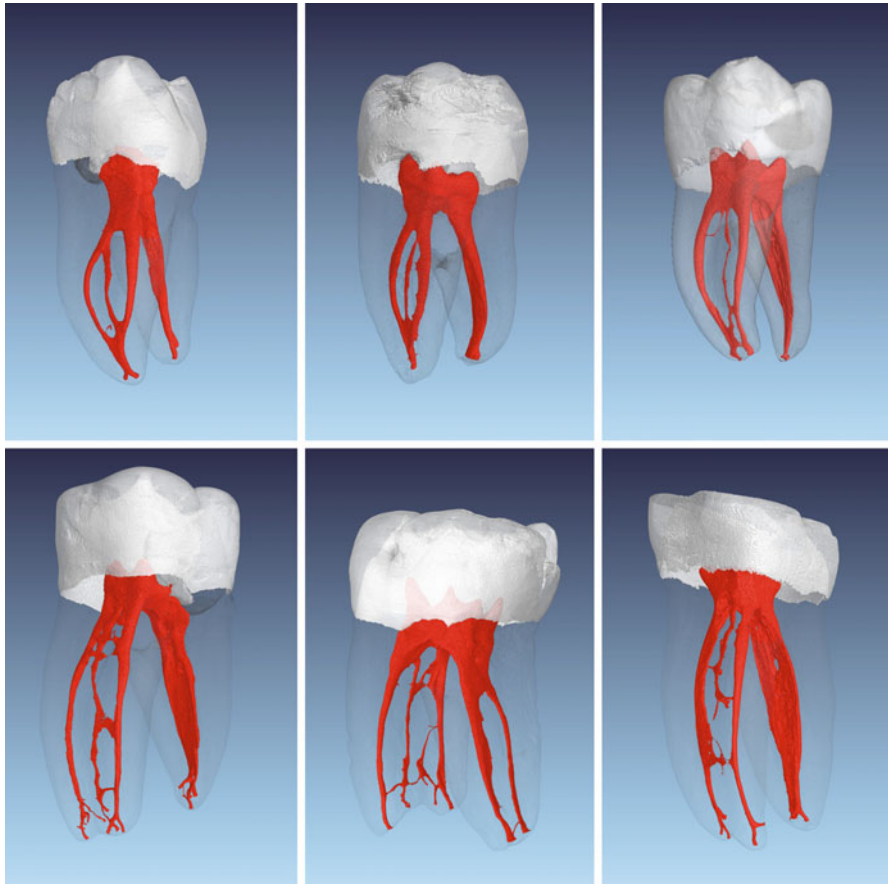


Fig. 1.12 Micro-computed tomography images of six extracted mandibular molars with middle mesial root canals. In the *upper panel*, middle mesial root canals are merging into one of the main canals. In the *lower row*, middle mesial root canals show separate portals of exit. Note the portal of exit in the middle portion of the root in the example depicted *lower right*

1.5.3 Middle Mesial Root Canals

A so-called “middle mesial” root canal in mesial roots of mandibular molars has been described as an additional canal between the mesiobuccal and the mesiolingual canal, which occurs in the development of the root [10]. Middle mesial canals were found with a frequency of 1–15 % [1]. With enhancement of clinically available detection methods (i.e., the use of the dental microscope) [37] and troughing the dentin between the two main mesial root canals up to 2 mm [38], in a recent study, a prevalence of up to 22 % was found (Fig. 1.12).

However, the age of the patients at the time of extraction during in vitro study [38] is not known; thus, the results may not be representative to the adult population

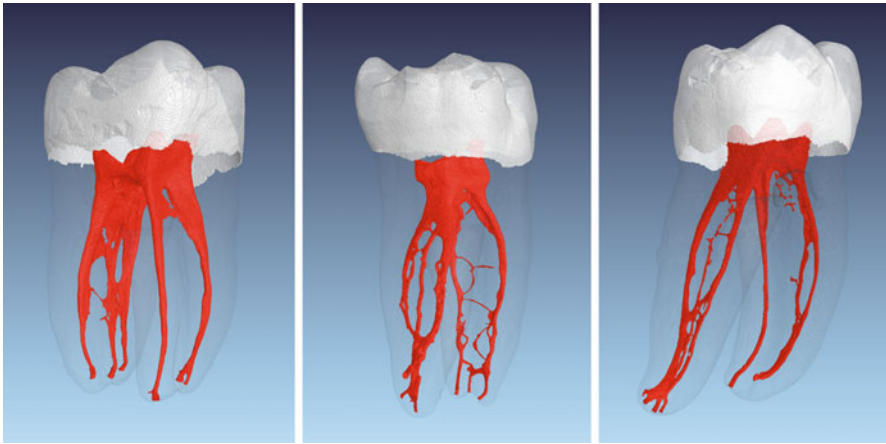


Fig. 1.13 Micro-computed tomography images of three extracted mandibular molars with middle distal root canals

of various stages of life. An age-related incidence of negotiable middle mesial root canals was indeed described by Nosrat et.al. [39]. They found about 33 % middle mesial canals in patients ≤ 20 years old, 24 % in patients 21–40 years old, and 4 % in patients >40 years old. The occurrence of middle mesial canals in mandibular molars is not only age-related but also related to different populations. In a micro-CT study of extracted teeth, 22 % middle mesial canals could be found in a Brazilian population, whereas only 15 % middle mesial canals were identified in a Turkish population [40].

Regarding the identification of accessory mesial canals in the mandibular first molar, there was a statistically significant difference when comparing the use of a dental microscope or CBCT with the use of a digital radiography and clinical inspection only. A good agreement between the dental microscope and the CBCT could be demonstrated. Digital radiography and clinical inspection without magnification support were not as precise as the use of the dental microscope or as the CBCT [41].

1.5.4 Middle Distal Root Canals

Three root canals in the distal root of mandibular molars might also occur (Fig. 1.13). However, the prevalence is described in a range of 0.2–3 % [42].

1.5.5 Accessory, Lateral Canals, and Apical Ramifications

Accessory and lateral canals connect the pulp space to the periodontium. An accessory canal represents a junction of the main pulp canals or the pulp chamber, which communicates with the root surface. A lateral canal is an accessory canal located in

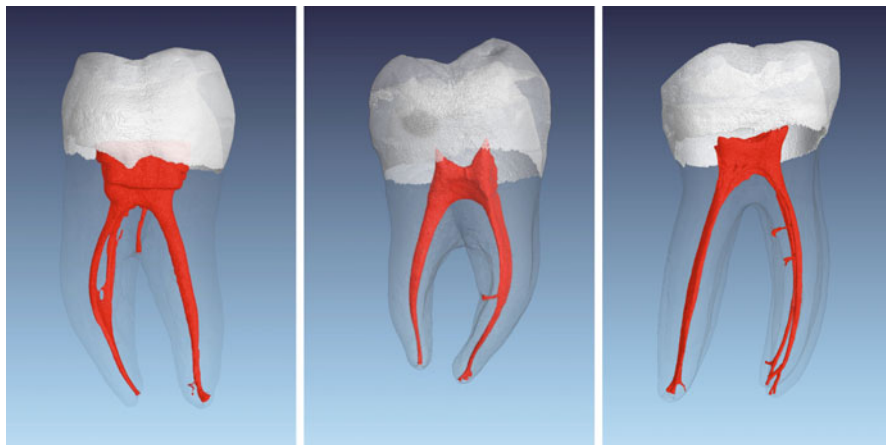


Fig. 1.14 Micro-computed tomography images of three extracted mandibular molars with accessory and lateral canals at different levels

the coronal or middle third of the root, usually branching off from the main canal (Fig. 1.14) [43]. In total, 73.5% of accessory canals were found in the apical third, 11.4% in the middle third, and 6.3% in the coronal third of the root [7]. Accessory canals were also found in intraradicular regions at bi- or trifurcations of teeth with more than one root and were then called furcation canals [44].

According to Vertucci [43], accessory canals in mandibular first molars occur in three different types:

- A single furcation canal runs from the pulp chamber to the interradicular region in 13% of all cases.
- In 23%, a lateral canal extends from the coronal third of a root canal into the furcation. The lateral canal starts in 80% of these cases from the distal root.
- In 10% of all cases, teeth have both a lateral and a furcation canal.

The diameter of furcation canal openings was determined by Vertucci and Williams [44] using a scanning electron microscope. The diameter ranged from 4–720 μm , while the number of these canals ranged from 0 to more than 20 per tooth. Foramina, on both the pulp chamber floor and the furcation surface, occurred in the mandibular first molars in 32% and the second mandibular molars in 24%. In maxillary molars, an incidence of 36% in first and 12% in second molars could be found, respectively. In case of necrotic, infected pulp space, these canals could contribute to periapical pathosis in the furcation area of multirooted teeth.

Harris et al. [28] labeled openings in the apical 0.5 mm, which appeared clearly separated from the main canal, as ramifications. All other branches were designated as lateral canals. On average, almost four such openings were found in the apical 0.5 mm in the mesial root of mandibular first molars, while distal roots had 3.4 openings on average. The typical exit point of lateral canals in the mesial roots was

2.2 mm coronal from the apex, with almost 80 % of lateral canals leaving the root within the apical 3 mm of the root. About 90 % of lateral canals left the distal root in the apical 3 mm of the root. These data are in line with the results of a report by Kim and Kratchman [45]. This has relevance for surgical endodontics, namely, for the rule of threes: when resecting the apical 3 mm of the root, most of the lateral canals and apical ramifications are removed (see Chap. 10 in this book).

1.5.6 C-Shaped Canal Systems

A so-called C-shaped canal system is described as an anatomical variation [25]. Mostly the distal root canal is connected to one of the mesial root canals. A high prevalence of roots with C-shaped canals in mandibular second molars was found in an Asian population [43], with a range from about 14 to 50 %. Cooke and Cox [46] were the first to report on C-shaped canal configurations [26]. Although most C-shaped canals occur in the second mandibular molars, C-shaped canals were also occasionally observed in first molars. Instead of various individual openings, pulp chambers of C-shaped molars showed a curved opening of a 180° circle or more into the canal system. Instead of the full arc, semicolon-type shapes are also seen.

Coronoapically, C-shaped molars showed extensive anatomical variations, which can be divided into two groups:

- A single curved C-shaped canal from the canal entrance to the apex
- Three or more distinct canals below the usual C-shaped opening

C-shaped molars with a single, wide canal are the exception. According to Vertucci [43], most commonly presented is type 2 of the C-shaped canals with individual orifices but having C-shaped connections.

A more detailed description of C-shaped roots in mandibular second molars has been published using micro-CT on extracted teeth from China [25, 26, 47, 48]. The cross-sectional canal shape was analyzed using 0.5 mm slices toward the apex and divided on each level into the following five categories: (C1) a continuous C-shaped contour without separation or division; (C2) a semicolon-shaped canal as a result of an interruption of the C-shape; (C3) two or three separate canals, which are connected by an isthmus; (C4) a single round or oval canal; and (C5) no canal lumen could be observed [25] (Fig. 1.15). The majority of the extracted molars showed the

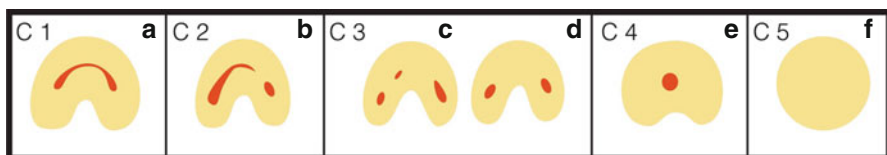


Fig. 1.15 Schematic diagrams cross-sectional canal shapes (a–f) within a mandibular molar with typical C-shaped configurations, C1–3 according to Fan et al. [25, 26]. Note C4 with a single canal and C5 where no canal lumen is observed, usually close to the apex

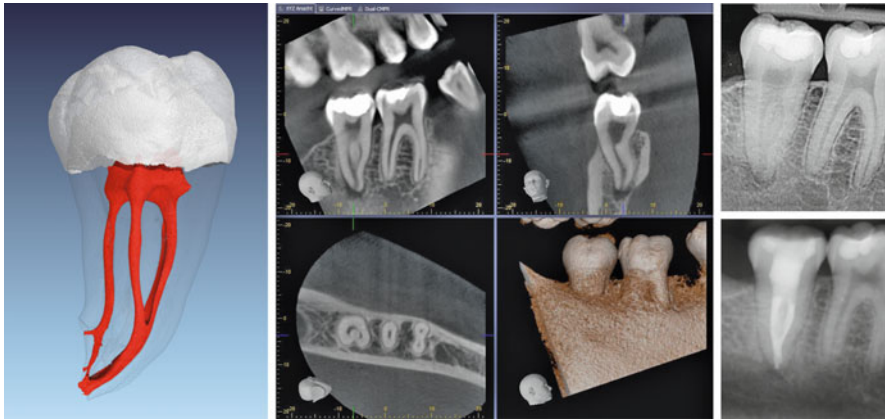


Fig. 1.16 Micro-computed tomography image of an extracted second mandibular molar with C-shaped canal configuration (*left*). CBCT (*middle*) and X-rays before and after treatment (*right*) of a similar clinical case

C1 configuration at the canal entrance. On the travel toward the apical third, the configuration C1, C2, and C3 were most commonly seen. The categories C4 and C5 were mostly observed in the apical region of the teeth.

The three-dimensional geometry of mandibular second molars was described as the following [48]: the merging type showing one major canal before exiting at the apical foramen was found in about 33%; the symmetrical type was present in roughly 39% and was described with separate mesial and distal canals; and a symmetry of the canals from the buccal-lingual view. In about 29%, the asymmetrical type was found representing mesial and distal canals with a large isthmus from the distal aspect across the furcation area (Fig. 1.16).

Finally a classification of the morphology of the pulp chamber floor in C-shaped molars has been described [47]. Of the 44 teeth with C-shaped root canal systems, almost 90% had a peninsula-like floor while about 18% had a continuous C-shaped opening and were classified as type I. Type II was described as having a narrow dentinal band as a connection between the buccal wall and the peninsula-like floor of the pulp chamber floor, dividing the groove into one or two mesial and a distal opening. Type II was found in about 36% of the teeth. In 32% of the cases, a large mesiobuccal-distal and a small mesiolingual orifice was formed by a dentin fusion between the peninsula-like floor and the mesial pulp chamber wall (type III). Type IV had no C-shaped pulpal floor showing a distal and an oval or two round mesial openings and was present in 13.6%. The authors concluded that most mandibular molars with C-shaped root canal systems also show a C-shaped pulpal floor.

1.5.7 Isthmi and Intracanal Communications

An isthmus was defined as a narrow bandlike communication between two root canals, comprising pulp tissue [49]. Mannocci et al. [50] highlighted the variability

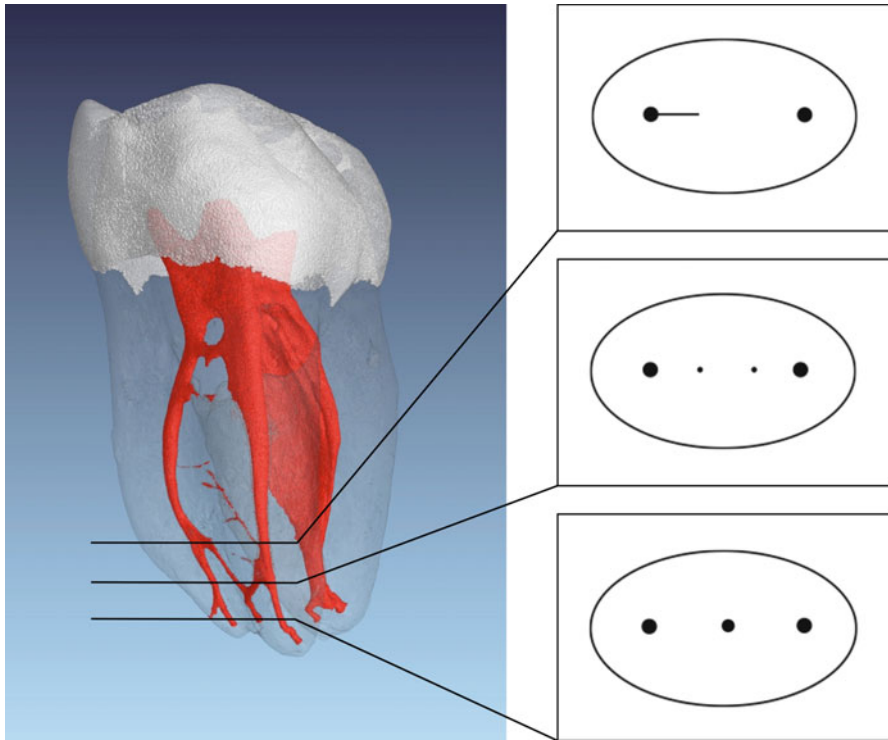


Fig. 1.17 Micro-computed tomography image of an extracted first mandibular molar with an obvious isthmus between the mesial main canals. The *right panel* illustrates different canal configurations at each section's plane; depending on the section plane during apical surgery of the mesial root, there is a chance that isthmus would have been missed completely

and frequency of isthmi in mesial roots of mandibular molars using the micro-CT technology. An isthmus in mandibular molars was found in about 17% of teeth at 1 mm coronal to the apex and in roughly 37% at 2 mm coronal to the apex. About half of teeth showed isthmi at 3 mm, one-third each had an isthmus at 4 mm and 5 mm from the apex, respectively. However, the data was evaluated using horizontal slides and the use of micro-CT data allows a more accurate three-dimensional analysis (Fig. 1.17). This was done by Fan et.al. [51] and gave a better three-dimensional understanding of intracanal communications in mesial roots of mandibular molars. The following classifications were made: type I: complete thin connection between two canals; type II: separate, thin, but incomplete connection between the two canals; type III: mixed, an incomplete isthmus exists above or below a complete isthmus; type IV: needlelike connection: close needlelike connection between two canals.

The authors found a prevalence of isthmi in 85% in the coronal 5 mm from the apex of mesial roots of mandibular molars [51] and there was a significant difference of the isthmus types detected in the first and second molars. Mesial roots in

first molars showed mostly type II and III isthmi, while in the mesial roots of second molars type I dominated [51].

In summary, molar anatomy is complex, with defined basic morphologies and multiple variations. Third molars are not typically root canal-treated, their anatomy may add another layer of complexity to the detailed illustration above. Therefore, in planning a molar root canal treatment, clinicians should:

- Have an understanding of possible anatomic variations of the tooth in question
- Obtain all relevant clinical impressions and images, including periapical radiographs, bitewings, cone beam CT scans
- Use magnification during the procedure
- Be ready to expect the unexpected in molar anatomy, both for the number of canals and their individual configuration

References

1. Vertucci FJ, Haddix JE. Tooth morphology and access cavity preparation. In: Cohen S, Hargreaves KM, editors. *Pathways of the pulp*. 10th ed. St. Louis: Mosby; 2011. p. 136–222.
2. Nair P. On the causes of persistent apical periodontitis: a review. *Int Endod J*. 2006;39:249–81.
3. Jhahharia K, Parolia A, Shetty K, Mehta L. Biofilm in endodontics: a review. *J Int Soc Prev Community Dent*. 2015;5:1–12.
4. Siqueira J, Rôças I. Exploiting molecular methods to explore endodontic infections: part 2 – redefining the endodontic microbiota. *J Endod*. 2005;31:488–98.
5. Lee K, Periasamy S, Mukherjee M, Xie C, Kjelleberg S, Rice S. Biofilm development and enhanced stress resistance of a model, mixed-species community biofilm. *ISME J*. 2014;8:894–907.
6. Weine FS, Healey HJ, Gerstein H, Evanson L. Canal configuration in the mesiobuccal root of the maxillary first molar and its endodontic significance. *Oral Surg Oral Med Oral Pathol*. 1969;28:419–25.
7. Vertucci FJ. Root canal anatomy of the human permanent teeth. *Oral Surg Oral Med Oral Pathol*. 1984;58:589–99.
8. Gulabivala K, Aung TH, Alavi A, Ng YL. Root and canal morphology of Burmese mandibular molars. *Int Endod J*. 2001;34:359–70.
9. Sert S, Bayirli G. Evaluation of the root canal configurations of the mandibular and maxillary permanent teeth by gender in the Turkish population. *J Endod*. 2004;30:391–8.
10. Peiris H, Pitakotuwage T, Takahashi M, Sasaki K, Kanazawa E. Root canal morphology of mandibular permanent molars at different ages. *Int Endod J*. 2008;41:828–35.
11. Buchanan LS. Curved root canals: treating the most common endodontic complexity. *Dent Today*. 1992;11(34):6–8.
12. Ng Y, Mann V, Gulabivala K. Tooth survival following non-surgical root canal treatment: a systematic review of the literature. *Int Endod J*. 2010;43:171–89.
13. Carabelli G. *Systematisches Handbuch der Zahnheilkunde*. Wien: Baumüller und Seidel; 1844.
14. Hess W. *Zur Anatomie der Wurzelkanäle des menschlichen Gebisses mit Berücksichtigung der feineren Verzweigungen am Foramen apikale*. Universität Zürich; 1917.
15. Cleghorn B, Christie W, Dong C. Root and root canal morphology of the human permanent maxillary first molar: a literature review. *J Endod*. 2006;32:813–21.

16. Wolcott J, Ishley D, Kennedy W, Johnson S, Minnich S, Meyers J. A 5 yr clinical investigation of second mesiobuccal canals in endodontically treated and retreated maxillary molars. *J Endod.* 2005;31:262–4.
17. Stropko JJ. Canal morphology of maxillary molars: clinical observations of canal configurations. *J Endod.* 1999;25:446–50.
18. Peters OA, Laib A, Rueggsegger P, Barbakow F. Three-dimensional analysis of root canal geometry by high-resolution computed tomography. *J Dent Res.* 2000;79:1405–9.
19. Carr G, Murgel C. The use of the operating microscope in endodontics. *Dent Clin North Am.* 2010;54:191–214.
20. Eskoz N, Weine FS. Canal configuration of the mesiobuccal root of the maxillary second molar. *J Endod.* 1995;21:38–42.
21. Neaverth EJ, Kotler LM, Kaltenbach RF. Clinical investigation (in vivo) of endodontically treated maxillary first molars. *J Endod.* 1987;13:506–12.
22. Park J, Lee J, Ha B, Choi J, Perinpanayagam H. Three-dimensional analysis of maxillary first molar mesiobuccal root canal configuration and curvature using micro-computed tomography. *Oral Surg Oral Med Oral Pathol Oral Radiol Endod.* 2009;108:437–42.
23. Gorduysus MO, Gorduysus M, Friedman S. Operating microscope improves negotiation of second mesiobuccal canals in maxillary molars. *J Endod.* 2001;27:683–6.
24. Kulild JC, Peters DD. Incidence and configuration of canal systems in the mesiobuccal root of maxillary first and second molars. *J Endod.* 1990;16:311–7.
25. Fan B, Cheung G, Fan M, Gutmann J, Bian Z. C-shaped canal system in mandibular second molars: part I – anatomical features. *J Endod.* 2004;30:899–903.
26. Fan B, Cheung G, Fan M, Gutmann J, Fan W. C-shaped canal system in mandibular second molars: part II – radiographic features. *J Endod.* 2004;30:904–8.
27. Abou-Rass M, Frank AL, Glick DH. The anticurvature filing method to prepare the curved root canal. *J Am Dent Assoc.* 1980;101:792–4.
28. Harris S, Bowles W, Fok A, McClanahan S. An anatomic investigation of the mandibular first molar using micro-computed tomography. *J Endod.* 2013;39:1374–8.
29. Berutti E, Fedon G. Thickness of cementum/dentin in mesial roots of mandibular first molars. *J Endod.* 1992;18:545–8.
30. Filpo-Perez C, Bramante CM, Villas-Boas MH, Hungaro Duarte MA, Versiani MA, Ordinola-Zapata R. Micro-computed tomographic analysis of the root canal morphology of the distal root of mandibular first molar. *J Endod.* 2015;41:231–6.
31. De Moor R, Deroose C, Calberson F. The radix entomolaris in mandibular first molars: an endodontic challenge. *Int Endod J.* 2004;37:789–99.
32. Abella F, Patel S, Durán-Sindreu F, Mercadé M, Roig M. Mandibular first molars with distolingual roots: review and clinical management. *Int Endod J.* 2012;45:963–78.
33. Cantatore G, Castellucci A, Berutti E. Missed anatomy: frequency and clinical impact. *Endod Top.* 2009;15:3–31.
34. Gu Y, Lu Q, Wang H, Ding Y, Wang P, Ni L. Root canal morphology of permanent three-rooted mandibular first molars – part I: pulp floor and root canal system. *J Endod.* 2010;36:990–4.
35. Gu Y, Zhou P, Ding Y, Wang P, Ni L. Root canal morphology of permanent three-rooted mandibular first molars: part III – an odontometric analysis. *J Endod.* 2011;37:485–90.
36. de Pablo O, Estevez R, Péix Sánchez M, Heilborn C, Cohenca N. Root anatomy and canal configuration of the permanent mandibular first molar: a systematic review. *J Endod.* 2010;36:1919–31.
37. de Carvalho M, Zuolo M. Orifice locating with a microscope. *J Endod.* 2000;26:532–4.
38. Karapinar-Kazandag M, Basrani B, Friedman S. The operating microscope enhances detection and negotiation of accessory mesial canals in mandibular molars. *J Endod.* 2010;36:1289–94.
39. Nosrat A, Deschenes R, Tordik P, Hicks M, Fouad A. Middle mesial canals in mandibular molars: incidence and related factors. *J Endod.* 2015;41:28–32.
40. Versiani M, Ordinola-Zapata R, Keleş A, Alcin H, Bramante C, Pécora J, et al. Middle mesial canals in mandibular first molars: a micro-CT study in different populations. *Arch Oral Biol.* 2016;61:130–7.

41. de Toubes K, Côrtes M, Valadares M, Fonseca L, Nunes E, Silveira F. Comparative analysis of accessory mesial canal identification in mandibular first molars by using four different diagnostic methods. *J Endod.* 2012;38:436–41.
42. Kottoor J, Sudha R, Velmurugan N. Middle distal canal of the mandibular first molar: a case report and literature review. *Int Endod J.* 2010;43:714–22.
43. Vertucci FJ. Root canal morphology and its relationship to endodontic procedures. *Endod Top.* 2005;15:3–31.
44. Vertucci FJ, Williams RG. Furcation canals in the human mandibular first molar. *Oral Surg Oral Med Oral Pathol.* 1974;38:308–14.
45. Kim S, Kratchman S. Modern endodontic surgery concepts and practice: a review. *J Endod.* 2006;32:601–23.
46. Cooke HG, Cox FL. C-shaped canal configurations in mandibular molars. *J Am Dent Assoc.* 1979;99:836–9.
47. Min Y, Fan B, Cheung GS, Gutmann JL, Fan M. C-shaped canal system in mandibular second molars part III: the morphology of the pulp chamber floor. *J Endod.* 2006;32:1155–9.
48. Gao Y, Fan B, Cheung GS, Gutmann JL, Fan M. C-shaped canal system in mandibular second molars part IV: 3-D morphological analysis and transverse measurement. *J Endod.* 2006;32:1062–5.
49. Weller RN, Niemczyk SP, Kim S. Incidence and position of the canal isthmus. Part 1. Mesiobuccal root of the maxillary first molar. *J Endod.* 1995;21:380–3.
50. Mannocci F, Peru M, Sherriff M, Cook R, Pitt Ford TR. The isthmuses of the mesial root of mandibular molars: a micro-computed tomographic study. *Int Endod J.* 2005;38:558–63.
51. Fan B, Pan Y, Gao Y, Fang F, Wu Q, Gutmann JL. Three-dimensional morphologic analysis of isthmuses in the mesial roots of mandibular molars. *J Endod.* 2010;36:1866–9.

Diagnosis in Molar Endodontics

2

David E. Witherspoon and John D. Regan

Abstract

Developing a diagnosis is, in essence, a process in information gathering. This information is gathered from the patient's history of pain, trauma or restorative procedures, clinical examinations, results of clinical tests, and radiographic examination of the teeth and the surrounding tissues. The diagnostic process begins with a patient interview and review of the medical history, dental history, and pain history. A thorough patient and pain assessment interview will often enable a clinician to differentiate between odontogenic and non-odontogenic pain. Non-odontogenic pain will often become chronic and debilitating in nature. Furthermore, this pain can be further exacerbated by incorrect or unnecessary treatments frequently resulting in the establishment of chronic pain pathways.

An accurate diagnosis is crucial for arriving at an appropriate treatment choice: no treatment, medication, vital pulp therapy, nonsurgical root canal treatment, surgical root canal treatment, extraction, or referral. Pulpal and periradicular testing should always be carried out to establish an accurate diagnosis. Ultimately, the clinician must answer two critical questions before progressing to treatment of a tooth: one is the tooth restorable and, two, what is the periodontal prognosis for the tooth.

D.E. Witherspoon, BDS_c, MS, MFA, FICD (✉) • J.D. Regan, BDentSc, MA, MSc, MS, FICD
Department of Endodontics, Texas A&M University Baylor College of Dentistry,
Dallas, TX, USA

North Texas Endodontic Associates, 5800 Coit Rd. Suite 200, Plano, TX, USA
e-mail: dewspoon@ntendo.com

Guiding Reference

Newton CW, Hoen MM, Goodis HE, Johnson BR, McClanahan SB. Identify and determine the metrics, hierarchy, and predictive value of all the parameters and/or methods used during endodontic diagnosis. *J Endod.* 2009;35(12):1635–44.

Diagnosis is the art and science of identifying divergence from health and its cause. Inherent in this process is the identification of a condition by comparing the symptoms of all (or other) pathologic processes that may produce the signs and symptoms. It is impossible to directly test dental pulp; therefore, all information elicited must be interpreted indirectly from the patient response to a stimulus placed externally to the tissue. Generally, pulp tests are more valid in determining teeth that are free of disease but less effective in identifying teeth with pulp disease. Diagnostic tests include thermal and electric pulp testing, palpation, percussion, bite test, and radiographic examination/interpretation. Testing in general should be carried out as follows: (1) test teeth that are not suspected to be pulpally involved before testing the suspected tooth (baseline patient response), (2) duplicate the symptoms, (3) correlate finding (signs and symptoms), and (4) place stimulus on the middle third of the facial surface of the tooth to be tested. In the final analysis, the tests used in endodontic methods are based on qualitative response.

2.1 Introduction

Developing a diagnosis is a process in information gathering, from the patient's history of pain, experience of trauma or restorative procedures, clinical examinations, results of clinical tests, and radiographic examination of the teeth and the surrounding soft and hard tissue structures. The diagnostic process should lead to answers for four critical questions prior to rendering treatment:

- Can the pathological process be identified and treated?
- Is the tooth restorable?
- What is the periodontal prognosis of the tooth?
- What is the operator skill level required to complete the treatment successfully?

It is necessary that the dentist takes a systematic approach to answer each of these four questions in all cases. An accurate diagnosis is crucial for arriving at an appropriate treatment choice: no treatment at all, medication, vital pulp therapy, nonsurgical root canal treatment, surgical root canal treatment, extraction, or referral. Essential to establishing a correct diagnosis is the cumulative data from the patient examination and testing. These are reliable forecasters of pulpal disease in approximately 85 % of cases [1].

2.2 Patient Interview

The diagnostic process begins with a patient interview (Box 2.1). There are several critical aspects to the patient interview; these include the chief complaint, history of the chief complaint, medical history, and dental history.

2.3 Chief Complaint

A chief complaint is the reason a patient seeks care. It is important for the patients to express this in their own words and for this to be recorded. A clear understanding of a patient's motivation for seeking care and of their expectations will help alleviate confusion and avoid breakdown in the dentist–patient relationship. It should be noted that a patient could possibly have additional dental disease that they are not seeking care for at that particular appointment. Once a patient's chief complaint has been managed, it is incumbent upon the dentist to make a patient aware of the potential for additional problems.

2.4 History of the Chief Complaint

Several important aspects of the diagnostic process can be elicited from the history of a patient's chief complaint. As the Victorian physician Sir William Osler once said, "If you listen to your patients, they will tell you their diagnosis." While it is essential to have the patient complete a written medical questionnaire, it is important to follow this up with an oral interview. A study has indicated that the questionnaire medical history was significantly deficient in 4.25 % of cases [2].

Box 2.1: Patient Interview

Chief complaint	Complaint in patient's own words
Medical history	Medical causes of symptoms
	Medical condition: complexity in managing a patient
	Psychological condition: complexity in managing a patient
Dental history	Undiagnosed medical condition
	Recent dental treatment
	Dental trauma
Patient history	Pain scale
	Characterization
	Temperature sensitive
	Percussion sensitive
	Reproducible
	Location
	Duration

There are three principle components to the history of a chief complaint:

- Dental history
- Medical history
- Pain history

With regard to the pain history, this aspect of the interview should be directed at identifying the presence or absence of pain, the nature (constant or intermittent pain) and quality of pain if present, and the region of the pain. A thorough assessment of pain is essential in differentiating between odontogenic and non-odontogenic pain. Various pain qualities and characteristics can help delineate between these two origins of pain. Thus, information that relates to pain is essential. It should include the ability to localize to a specific tooth; spontaneous pain; provoking factors (tenderness to hot, cold, sweet, sour, chewing); interference with sleep; relieving factors (use and effect of drugs; ice water); character of pain (sharp, dull, throbbing, irradiating); duration of pain; referred or radiating pain; a feeling that the tooth is extruded; presence of swelling and possible relationship to pain; fever; malaise; presence of pus; impaired mouth opening. A visual analog pain scale or a pain rating scale is useful in establishing a patient's level of pain. It is also valuable in establishing a baseline that can subsequently be used to refer back to in assessing the degree to which the pain has been alleviated. It should be recalled that pain of pulpal origin is more likely to be described as sharp and lingering whereas pain from the periradicular origin is more frequently described as dull pain.

2.5 Dental History

It important to enquire if a patient has had any recent dental treatment or injuries. A "broken tooth" as a result of caries can frequently result in a near pulp exposure or pulpal exposure proper.

2.6 Medical History

There are no medical conditions that are contraindicatory to the provision of endodontic treatment. There are, however, conditions that require consultation with the patient's other health care providers and additional management during endodontic treatment. The major purpose of a medical history is fourfold:

- To rule out possible systemic or medical causes for the patients symptoms.
- To identify medical conditions that might increase the complexity of managing a patient.
- To identify a psychological condition that might increase the complexity in managing a patient.
- To potentially identify undiagnosed medical conditions that would increase the complexity of the treatment.

A patient medical history should be updated regularly and include a patient's vital signs and a review of systems. This is considered standard of care.

2.7 Odontogenic Versus Non-odontogenic Pain

It is important for the clinician to identify developing non-odontogenic pain as early as possible in the development of the process. Frequently, such pain will become chronic and debilitating in nature. Furthermore, this pain can be further exacerbated by incorrect or unnecessary treatments, often resulting in the establishment of chronic pain pathways. The site of pain is where the patient feels the pain and this can differ dramatically from the source of pain. The source is the structure from which the pain actually originates. Pain with distinctive sites and sources of pain are known as heterotopic pain [3]. Heterotopic pain can be separated into three types [4]:

- Central pain
- Projected pain
- Referred pain

Two aspects are thus important in the management of these conditions: one is to establish a correct diagnosis as soon as possible and the second is the importance of avoiding unnecessary treatment. The aim, from the perspective of this chapter, is not to establish a diagnostic schematic for all pain in the facial region, but rather to provide the practicing clinician with an approach to the diagnostic process that will facilitate two things. Firstly, it allows the clinician to differentiate between odontogenic and non-odontogenic pain. Secondly, if it is odontogenic in origin, it provides the clinician with a process to either establish the pain as endodontic in origin; that is, pulpal pathology or secondary to pulpal pathology with additional periradicular pathology (Box 2.2). It is important to realize that pain of endodontic origin can at times be extremely intense and debilitating; it is typically short in duration (weeks

Box 2.2: Characterization of Pain

Tooth pain	Non-tooth pain
Temperature sensitivity	Chronic
Percussion tender	Stabbing
Deep	Shooting
Dull	Burning
Aching	Multiple locations
Sharp	Absent of obvious pathology
Specific	Headache
Throbbing	Trigger points/zones
Reproducible	Altered by psychological stress
Unilateral	

as opposed to months or years) that will either become focused on a particular tooth or dissipate only to return at a later date.

Pain, when present, is obviously an indicator of some form of disease. Pain in the mid and lower facial regions can be confusing for patients and they are often unsure as to whether they should consult a doctor or dentist. By far, one of the most common causes of pain in the mid and lower face is pain of dental origin. Epidemiologic studies indicate that toothache is the prevalent form of pain in the orofacial region, with approximately 12–14% of the population reporting a history of toothache in the preceding 6-month period [5]. Odontogenic pain usually results from either one of two structures associated with the tooth; the pulpal or periodontal tissues. Analysis of patients attending dental practices and hospitals for emergency treatment of pain in the facial region show that the more common causes of this pain are acute periapical periodontitis, irreversible pulpitis, reversible pulpitis, pericoronitis, and dentine hypersensitivity [6]. These disorders of the teeth typically cause toothache and/or pain in the orofacial region. Classic headache, as such, is an infrequent symptom associated with tooth pathology. However, pain from the teeth can be referred and can cause a diffuse type headache. Klausen et al. [1] reported a particular combination of signs and symptoms that are distinctly associated with pulpal degeneration in approximately 85% of cases. The signs and symptoms included constant pain, sensitivity to temperature changes, an extruded feeling in the tooth, impaired mouth opening, mobility, and tenderness to palpation in the apical area. These signs and symptoms in various combinations were highly accurate predictors of odontogenic disease. Temperature sensitivity was highly indicative of pulpitis; on the other hand, pain due to apical periodontitis is often associated with digital pressure or percussion tenderness. In a similar study using a descriptor survey, patients could be correctly classified into one of three diagnostic categories in approximately 90% of cases [6]. The important keys to differentiating between odontogenic and non-odontogenic pain are severity, location, quality, and duration. Notably, pain of pulpal or periodontal pathology secondary to pulpal pathology should resolve completely with local anesthesia. Pain that does not resolve following the administration of local anesthetic should raise a very strong suspicion of pain of non-odontogenic origin.

One of the hallmarks in differentiating odontogenic and non-odontogenic pain is its chronicity. It should be noted that few dental causes of pain are truly chronic in nature. However, given its high prevalence, it needs to be considered in all patients who report a history of chronic pain or who report a change in their symptoms of chronic pain, which are not expected from the main condition. Chronic orofacial pain patients will frequently have seen several health care providers in an effort to treat their pain. In 100 consecutive patients referred to oral and maxillofacial surgeons for pain assessment that was not due to odontogenic causes, patients had frequently seen more than three practitioners in an effort to resolve their symptoms; 44% had either extractions or endodontic treatment in an unsuccessful attempt to treat their orofacial pain [7]. In patients referred to an endodontic specialty practice, 88% of patients had solely an endodontic problem, 9% had an endodontic problem plus a separate orofacial pain problem, and 2.2% primarily had a non-tooth-related problem [7]. It was concluded that tooth pain is the most common type of orofacial pain for which patients seek dental treatment.

It is useful for the individual dentist to develop a system or checklist [8] to help with the diagnostic process. One approach is to attempt to classify craniofacial pain into one of several categories. These include neurovascular, neuropathic, muscular, intracranial pathology, referred from other pathological conditions, local pathology, and those that do not fit into the preceding categories. Understanding the types of pain in these categories will help eliminate them as a possible etiology. Furthermore, by identifying a possible etiological category, the clinician is able to direct the patient to the appropriate specialty to provide a definitive diagnosis. For an extensive review of non-odontogenic orofacial pain, the reader is referred to one of several texts, including *Orofacial Pain: Guidelines for Assessment, Diagnosis and Management* [4, 9, 10]. What follows is a description of the more common cause of non-odontogenic toothache [3].

2.8 Common Source of Non-odontogenic Toothache

2.8.1 Muscular

Temporomandibular pain and muscle disorder pain is reported in approximately 10–15% adults [11]. Approximately 7% of cases referred for endodontic treatment have a myofascial “toothache” [12]. Furthermore, 37% of patients diagnosed with muscular orofacial pain have previously undergone endodontic treatment or tooth extraction in an effort to relieve their pain [7]. Myofascial pain that mimics a toothache is typically described as diffuse, deep, dull, nonpulsating, aching pain that occurs more continuously than pulpal pain. Many of these qualities are, however, similar to pulpal or periradicular pain. Chewing can also exacerbate the symptoms, which may confuse the diagnostic process. Key to differentiating the origin of the pain here is that palpation of the musculature should reproduce pain of myofascial origin while percussion of the teeth should elicit a normal response. Additionally, pulp testing will be normal or fail to reproduce the reported symptoms. Radiographically, the lamina dura may be thickened and the PDL space widened due to increased bruxism and clenching. Typically, muscles that refer pain to the teeth include the masseter, temporalis, medial pterygoid, lateral pterygoid, and the anterior digastric. It can also be associated with emotional stressors.

2.8.2 Sinus or Nasal Structures

Pathology of the nasal and sinus mucosa can frequently present as a toothache emanating typically from the posterior maxillary teeth. About 10% of maxillary sinusitis cases have been diagnosed as having an odontogenic origin [13]. They may or may not be accompanied by additional symptoms consistent with sinus involvement such as nasal congestion or drainage. The hallmarks that generally differentiate these conditions from tooth pain include increased pain sensation when a patient touches their toes, several teeth in the same side in the maxilla that are tender to percussion, pulp testing that have normal responses to thermal or electric pulp tests,; and a lack of radiographic evidence of periradicular pathology.

2.8.3 Neurovascular

Pain of this origin can have qualities of intensity and pulsation comparable to pulpal pain. The patient will frequently complain of “headache” symptoms with “toothache” being a secondary complaint. Three types of headaches fall into this category, migraines, cluster headaches, and tension headaches. The typical referral pattern of neurovascular headache is to the maxillary anterior and premolar teeth. The temporal nature of these types of headaches is also a key factor in differentiating them from tooth pain. The pain is frequently very intense for 4–72 h followed by periods of complete remission. The symptoms are not typically provoked by the usual stimuli of toothache such as hot, cold, and chewing. Thus, pulp testing would typically produce a normal response. Furthermore, radiographic analysis of the teeth in the region of the pain would reveal no obvious pathological change. The use of local anesthetic as a diagnostic aid can be misleading in these patients. The periods of intense headache pain are often associated with photophobia or phonophobia occurring in approximately 60% of patients. This tends to be unilateral. Nausea and vomiting has also been reported in approximately 30% of patients. It has been reported that 36% of patients have had teeth extracted in an attempt to treat the pain [14]. Additionally, the pain may switch from one side to the other between attacks or cluster periods and this is particularly uncommon in pain of tooth origin. However, the short duration of attacks, recurrences, excruciating intensity and pulsatile pain quality found in neurovascular headache make it possible to mistake this source of pain for pulpitis [15]. Approximately, 42% of cluster headache patients have received some form of irreversible dental procedure in an attempt to alleviate their pain [15]. It should be noted that the prevalence of migraine headaches affects about 12.5% of the general population in the United States. It is also the most widespread cause for disability from headache.

2.8.4 Neural

Neuropathic pain is caused as a result of abnormalities associated with the actual neural structure and not from the tissues that are innervated by those neural structures. Thus, there is typically no structural pathology evident. Neuropathic pain that is felt in teeth can be either episodic or continuous. Clinically, episodic neuropathic toothache presents as a severe, shooting, electric-like pain that lasts only a few seconds. Continuous neuropathic pain usually presents as constant, ongoing, and unremitting pain. It can have periods of high and low intensity, but none of total remission [3]. In patients with continuous neuropathic pain, 79% had undergone dental treatment that failed to resolve their pain [16]. Several different forms of neuropathic pain exist and these include neuralgia, neuritis, and neuropathy. The more common types include trigeminal neuralgia, herpetic neuritis, and neuropathy secondary to injury or sensitization of the neural structures.

The classic type of neuralgic pain in the orofacial region is trigeminal neuralgia. Trigeminal neuralgia is characterized by episodic intense sharp shooting unilateral

pain. Stimulating a trigger zone, typically with light touch or airflow, can reproduce the pain. The duration of the pain is up to several minutes and does not occur again until the trigger zone is re-stimulated. A trigger zone can be in any region of the distribution of the nerve and so may be extraoral or intraoral. Demographically, trigeminal neural is usually present in patients 50 years or older; it is also more common in females than males. Although neuralgic pains may closely mimic acute toothache of pulpal origin, pulpal and periradicular testing is normal or not definitively conclusive. There is also a lack of dental pathology present. Additionally, neuralgias rarely wake patients once they are asleep.

Herpetic neuritis typically is not a diagnostic challenge once the skin or mucosal vesicular outbreak occurs. However, prior to vesicular eruption or if the viral infection involves deep neural branch, diagnosis can be more difficult. Key to diagnosis is a history of herpes zoster infection. Additionally, the pain quality is also described as aching, dull, and burning. It should be recalled that burning is not a common descriptor used for pain of tooth origin. Pulpal and periradicular testing is usually normal or not definitively conclusive. There is also a lack of dental pathology. Patients may also exhibit a decreased threshold response to non-noxious stimulation.

2.8.5 Cardiac

Classic cardiac pain usually originates in the sub-sternal region and radiates to the left neck, shoulder, arm, and left mandible. Angina pain can occasionally also mimic dental pain in the left mandible. Patients with pain of a cardiac origin reported the descriptor of “pressure” more often when compared to other pain sources [17]. Critically, this pain will not be intensified by local stimulation of the teeth. Furthermore, pulpal and periradicular tests will be normal and radiographic findings negative. Local anesthesia of the left mandible will not reduce the symptoms. Craniofacial pain is the only symptom in approximately 6% of patient that have cardiac ischemia. One study also reported that bilateral referred craniofacial pain was also observed approximately six times more often than unilateral pain [18]. Additionally, a patient may not necessarily report a medical history of cardiac disease.

2.8.6 Neoplasia

Orofacial pain may be the initial symptom of oral cancer or metastatic disease. According to the National Institute of Health in the United States, approximately 10.5 adults per 100,000 will develop oral cancer [19]. A retrospective case series found that pain was the first clinical sign of oral cancer in 19.2% of cases [6]. A study of neoplasia of the tongue reported that two-thirds of patients with oral cancer reported oral pain within the preceding 6 months of diagnosis [20]. Systemic cancers such as lymphoma and leukemia can have an intraoral presentation that mimics

toothache symptoms. Metastatic neoplasia to the jaw is rare with 1–3 % of all malignant oral neoplasias being metastatic. The common primary sources for the metastases to the oral region are the breast, lung, and kidney. The mandible is the most common location of the metastases, with the molar region being more commonly involved [21]. Although rare, patients with multiple myeloma can develop osseous osteolytic lesions adjacent to teeth. When this occurs, odontogenic pain is common and presents a radiologic diagnostic challenge [22]. In metastatic disease of the jawbones, pain has been reported in 39 % and paresthesias in 23 % of patients [23]. A retrospective case series of metastatic disease in the jaws reported that in 60 % of patients, oral signs and symptoms from a metastatic lesion in the jaw were the first indication of an undiscovered primary malignancy at a distant site [24].

2.8.7 Non-somatoform

The mental health of a patient is important in assessing facial pain. Chronic facial pain can affect a patient's mental health or can lead to an increase in the severity of pain experienced by the patient. Mental health conditions such as depression and anxiety can have a significant effect on their pain experience [11]. Neural markers for fear and anxiety have been shown to increase with chronic pain. Mentally overwhelmed patients show an increased distress and disability from pain. Additionally, a number of studies intimate a significant role of psychological factors such as anxiety and depressive disorders in inexplicable somatic symptoms. The prevalence of nonspecific somatoform symptoms is higher in psychologically distressed patients than in the general population. True psychogenic or somatoform pain is rare and is typically arrived at as a diagnosis by a process of elimination. This is cognitively perceived pain that has no verifiable corporeal basis. The key features of this type of pain are chronic pain from multiple locations that may not be anatomically connected, pain that does not follow anatomical distribution of the peripheral nerves, pain with no identifiable etiology and pain that frequently changes in character. In patients where such a condition is suspected, referral to a psychiatrist should be made.

2.9 Clinical Exam

Broadly speaking, the clinical exam is comprised of an extraoral exam and an intraoral exam.

2.9.1 Extraoral Exam (Box 2.3)

The extraoral exam should begin with a basic observation of the patient during the initial introductory conversation. Several important pieces of information can be gleaned during this time, much of which we do during the course of a conversation

Box 2.3: Extraoral Exam

Asymmetry
Eyes
Cognizant
Facial paralysis
Lymph nodes
Joint sounds
Muscle palpation
Range of opening
Soft tissue damage
Swelling

with any individual. In the dental setting, however, they become more critical. Firstly, patients should be cognizant of their surroundings, fluent in their speech, and be able to understand and make the choices that they are likely to encounter during the examination. Secondly, the patient should be evaluated for any apparent asymmetry, facial paralysis, or facial soft tissue damage including changes in skin tone, discoloration, redness, scarring, or ulceration. If any of these abnormalities exist, they should be pursued with the patient for further clarification. A classic example of this would be an extraoral sinus tract of odontogenic origin. In cases like this, a patient might present a history of unsuccessful medical treatments that can range from drug therapy to surgical intervention.

Palpation of the extraoral soft tissues is useful in determining the extent of the facial swelling and the involvement of lymph nodes. If the initial history is indicative of pain of a muscular origin, then palpation of the muscle of mastication to identify trigger points is appropriate. All patients should be observed for range of motion in jaw opening, joint sounds, and deviation of the mandible to the left or right during opening. A limited jaw opening might not only be indicative of non-odontogenic source of pain, but also could increase the degree of difficulty in delivering endodontic treatment.

The clinician should also be cognizant of nonverbal cues for pain. These include the obvious signs such as crying, facial grimacing; but also include subtler signs such as a clenched jaw, positioning the face or head to avoid stimulating the symptoms. A classic example of this would be the patient that enters the office with a container of ice-cold water that they continue to periodically sip to relieve tooth pain.

2.9.2 Intraoral Exam (Box 2.4)

The intraoral exam should take the approach of all clinical examinations moving from an initial broad examination that gradually becomes more focused on a specific region or problem. This approach will ensure that several important aspects of the clinical exam are not overlooked. It guarantees that the patient's general oral

Box 2.4: Intraoral Exam

Soft tissue assessment	Narrow angle probing
	Mobility
	Periodontal probing
	Periodontal pocketing
	Gingival recession
	Bleeding on probing
Hard tissue assessment	Cuspal biting
	Caries
	Defective restoration
	Excessive wear
	Fractured tooth
Palpation test	Stained tooth
	Apex of teeth
	Muscle of mastication
Pulp test	Cold
	EPT
	Heat
Periradicular test	Percussion
	Central fossa biting
Radiographic assessment	

health is assessed and key elements of the diagnostic process are not neglected. An examination of the patient's hard and soft tissue structures should be made and any abnormalities noted. Once the dentist has ruled out the presence of any serious pathology not related to the patient's chief complaint that requires immediate attention, the intraoral exam can begin to focus on the problem as defined in the patient's chief complaint. This should include an assessment of the immediately adjacent soft and hard tissues, presence of decay, tooth restorability, periodontal apparatus status, and specific tests related to periradicular and pulpal assessment.

2.10 Restorability

It can be said that root canal therapy can be performed on just about any tooth. However, subsequent restoration of the tooth to an ideal form and function is much less certain. Careful consideration should be given to the final restoration as part of the diagnosis and treatment planning steps. It is frustrating for all involved if an endodontically treated tooth is subsequently deemed nonrestorable.

Studies have suggested that the long-term prognosis for an endodontically treated tooth is more dependent on the coronal restoration than on the quality of the endodontic treatment itself [25]. Moreover, it has been demonstrated that loss of the coronal seal will result in a rapid recontamination of the root-canal-treated tooth [26].

In recent years, there has been a major change in philosophy regarding the restoration of endodontically treated teeth (see also Chap. 7 in this book). Researchers and clinicians have begun to realize the importance of respecting the preservation of tooth tissue and the biological properties of the components of the tooth, namely enamel, dentin, and cementum. It can be argued that this pendulum of change may have swung a little too far in the opposite direction with the move toward minimalist canal preparations. In an ideal world, minimal tooth tissue would be removed while achieving all of the goals of debridement, disinfection, and obturation. Four variables could improve the survival rate of endodontically treated teeth [27]. These are:

- Provision of crown restoration after endodontic treatment.
- Maintenance or replacement of mesial and distal proximal contacts.
- That the tooth itself is not an abutment for either a fixed or removable partial denture.
- That the tooth is not a molar tooth.

Before commencing endodontic treatment, the clinician must consider a number of factors regarding the restoration of the tooth.

- Altered physical properties of tooth tissues following endodontic treatment.
- How much dentin will remain following caries and/or restoration removal and access cavity preparation.
- The existence of a fracture/crack and the extent of the fracture/crack.
- What functional demands will be placed on the restored tooth.
- Will it be feasible to ensure that the biologic width can be respected when the new restoration is placed.
- Can an ideal embrasure space and emergence profile be restored or maintained.

Much has been written about the structural integrity and strength of the endodontically treated tooth. It is widely believed that endodontically treated molar teeth are more prone to fracture for a number of reasons:

- Weakening of the tooth due to loss of tooth tissue (especially loss of marginal and transverse ridges) [28]. Photoelastic and finite element analysis studies have demonstrated this fact repeatedly.
- Alteration in the physical properties of the tooth due to the effects of caustic irrigants such as hypochlorite and ethylene diamine tetraacetic acid [16]. It is believed that up to 30% of the ultimate tensile strength of the dentin is provided by the collagen, which undergoes significant changes after root canal treatment.
- Microbial factors: effects of bacteria–dentin interactions [29].
- Restorative factors: effect of post-core restorations.
- Age factors: effect of age changes on dentin [29].

Historically it was believed that the lack of pulpal blood supply renders dentin more brittle due to drying out; however, studies have relegated these theories to the

realms of unsound mistaken beliefs [30, 31]. Instead, the structural integrity of the tooth is compromised as soon as any tooth tissue is removed [32]. In addition, intra-canal irrigants, medicaments, and obturation materials may also play a role in influencing the physical and mechanical properties of dentin.

Endodontically treated molar teeth present the clinician with their own unique set of difficulties. The same principles, which govern the restoration of any tooth, also apply to the restoration of endodontically treated teeth. It is, however, especially important to preserve as much of the remaining tooth tissue and to design the restoration in a way that distributes stress in the most favorable manner. Traumatic occlusion is also well recognized as a source of endodontic failure and steps must be taken to minimize occlusal stresses [33].

It often happens that the tooth requiring endodontic treatment is severely broken down resulting in occlusal and proximal loss of space. This problem can sometimes be addressed by orthodontic treatment, intrusion of the opposing tooth, or recontouring adjacent restorations. A lack of coronal tooth tissue can be managed in a number of ways. If it is possible to encompass the tooth with a cast restoration extending onto solid tooth structure by at least 2 mm then the longevity of the restoration is more predictable; this is called the ferrule effect [34]. In some cases it may be necessary to crown lengthen the tooth in order to achieve this effect. In the absence of sufficient coronal tooth tissue, it may be possible to gain retention from the root. This tends to be more favorable in molar teeth than in other teeth due to the morphology of the teeth. Provision of posts or dowels cannot be routinely recommended especially in molars; rather, the use of the pulp chamber to retain a core is preferable. Further discussion of the techniques and materials will be discussed in the chapter on restoration in this book.

2.11 Endodontic–Periodontic Relationship

It is not surprising that pulpal and periodontal disease processes are closely related considering the close embryological relationship between the tissues. Both tissues are derived from a common mesodermal source. The pulpal precursor, the dental papilla, is separated from the periodontal tissue precursors by the Hertwig's epithelial root sheath. Both diseases have their terminal effects in the periodontal tissues [35]. Simring and Goldberg [36] first described this relationship and coined the term “endo-perio.” Simon et al. then attempted to codify the nature of the diseases and described five distinct categories [37]:

- The primary endodontic lesion
- The primary endodontic lesion with secondary periodontic involvement
- The primary periodontic lesion
- The primary periodontic lesion with secondary endodontic involvement
- The true combined lesion (both lesions present and have joined in periradicular tissues)

Belk and Gutmann [38] suggested a sixth category and called this the “concomitant lesion.” This describes the situation where both endodontic and periodontal

lesions exist but are wholly independent of each other. Establishment of the correct diagnosis is crucial to provision of the correct treatment. This is frequently difficult to establish but especially so in multirrooted teeth for a number of reasons. Molar teeth are morphologically complex and are often difficult to image due to their locations and surrounding structures such as the zygomatic arch on upper teeth and mandibular tori on the lower. They have multiple canal spaces complicating vitality testing; some canal spaces may maintain vitality while others become necrotic. They are associated with more vertical root fractures than anterior and premolar teeth. In addition, molars are frequently heavily restored making interpretation of testing and radiographs more difficult.

A diagnosis is based on taking a thorough history and full clinical exam as stated earlier. When a clinician suspects a possible endodontic–periodontal lesion a complete assessment of the pulpal and periodontal status of the tooth must be established. The essential components of this assessment include:

- History of periodontal symptoms both locally and generally (bleeding, mobility, infections)
- History of dentinal, pulpal, or periapical pain
- Signs and symptoms of pulp/periapical disease
- Periodontal charting
- Radiographic pattern of marginal and periradicular bone loss

Collecting the necessary information at the clinical exam necessitates using the full array of investigative methods and techniques including radiographic examination, vitality testing, periodontal probing, sinus tract tracing, fiber-optic illumination, percussion and palpation, and mobility determination.

Harrington emphasized the importance of detailed diagnostic periodontal probing [39]. His assertion was that a lesion of periodontal origin demonstrates a generalized gradual change in probings as opposed to one of endodontic origin that usually manifests as a precipitous drop or narrow-based probing. Accurate pulpal assessment is essential when periodontal disease is involved. The status of the pulp is crucial in establishing the correct diagnosis in the endo–perio scenario. If the pulp is healthy, then the lesion is totally periodontal in origin. If the pulp is necrotic, the periodontal apparatus has the capacity to regenerate following root canal treatment.

2.12 Sinus Tract

Whenever present, a sinus tract should be traced, especially if the sinus opening is distant from any obvious pathology. The simplest method for tracing a sinus is to utilize a gutta-percha cone, typically a size #30 or greater to avoid buckling of the cone within the tract and giving erroneous impressions of the source (Fig. 2.1). The opening of the sinus tract and gutta-percha cone can be coated with topical anesthetic and introduced into the sinus tract opening or stoma. The gutta-percha cone will progress into the sinus tract toward the offending region of pathology. In the majority

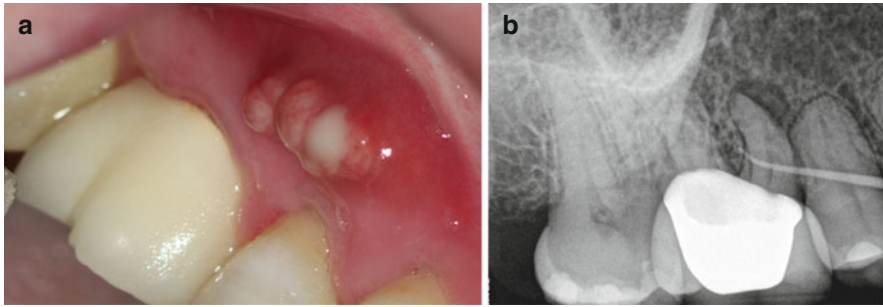


Fig. 2.1 (a) Clinical photography of a sinus tract adjacent to the maxillary second premolar tooth. (b) Radiograph of the same area showing the presence of a gutta-percha tracer in the sinus tract leading toward the periradicular radiolucency associated with the mesial root of the first molar tooth

of cases a coating of topical anesthetic will be sufficient to trace the sinus tract; only occasionally a patient may have to be anesthetized to achieve a successful tracing.

2.13 Diagnostic Tests

Prior to initiating any specific diagnostic tests, it is critical to inform the patient of the nature of the test, what to expect, and how to respond. All diagnostic tests should also be carried out in an order that establishes a base line level of a normal response for each patient. This is best done by first testing a “normal” contralateral tooth. The teeth on either side of the tooth that is primarily expected to be the source of the symptoms should then be tested. Finally, the tooth that is suspected as being the offending tooth should be tested last. As stated, it is imperative that the dentist and patient fully understand how to communicate the results of the test before commencing testing. In the case of thermal testing, a system of defined hand signals is often the most effective method for a patient to communicate their response. Typically, a patient would be directed to raise their hand when they feel the sensation from the stimulus in the tooth, to keep their hand up as long as this sensation lingers, and to lower their hand when the sensation ceases. It is important to advise a patient on differentiating between feeling a thermal change in their mouth and a sensation (pain) in their tooth. The authors feel that there is no place for the use of “test cavities” to determine vitality of a tooth.

2.14 Sensibility Testing: Pulpal Testing

Sensibility testing (thermal and electric) is central to the establishment of a correct pulpal diagnosis. However, all pulp tests have limitations and these must be recognized [40]. A positive response to pulp testing, thermal or electric, only confirms the existence of functional neural tissue. Conventional pulp testing does not indicate the presence of normal healthy pulpal tissue with a normal blood flow. Furthermore, pulp

tests are even less likely able to indicate the degree of health of the pulp. Thus, most pulp tests are only assessing the pulp sensitivity, rather than pulp vitality. Histological studies (specifically silver staining histological studies) have demonstrated that the neural component of the pulp is the last component of the pulp to undergo necrosis. Thus, false positive and false negative responses can and do occur. In general, cold and electric tests appear to be more dependable tests than heat. As a rule, it is important to use a test that will reproduce the patient's symptoms. Thus, if eating or drinking cold food produces or escalates the symptom, then a cold test should be used. Likewise, if hot foods produce or escalate the symptom, then a heat test should be used. Teeth should then be tested in an order that establishes a base line level of a normal response for each patient as described above. Teeth should be tested approximately 15 seconds (s) apart. This gives time for the tooth to respond and allows for a delayed response from a given tooth. In some instances, more time may be needed between testing of individual teeth and waiting to see if symptoms occur in a delayed manner. To perform a pulp test on any given tooth, it should be dried of saliva and the soft tissue retracted with the aid of cotton rolls or a dental mirror. The stimulus should then be applied to the buccal aspect of the mesial cusp or to the cervical region. Teeth that do not respond on the occlusal area respond approximately 14% of the time when stimulated in cervical area [41]. It is important to compare the immediacy, the intensity, and duration of the response from different teeth within the same patient.

2.15 Thermal Testing

The pulp tissue contains neural fibers along with blood and lymphatic vessels, extracellular matrix, ground substance, and all of the other components of a normal connective tissue. These fibers are either of the A or C type; A (A β or A δ) are well-developed myelinated fibers that are fast conducting and operate in the normal healthy pulp tissue. On the other hand, the C fibers are more primitive, non-myelinated slow-conducting fibers located in the core of the pulp that tend to be active only in inflamed pulp. The C fibers are slow to respond to stimulation, but once they begin to respond, they tend to continue to send impulses to higher cortical centers. Clinically, application of cold or heat that provokes a long-lasting response is one that is stimulating the C fibers, indicating the presence of active C fibers in inflamed tissue. This, therefore, determines a pulpal diagnosis of irreversible pulpitis. Additionally, thermal stimuli cause contraction or expansion of fluids inside the dentinal tubules. The hydrodynamic forces generated act on the A δ nerve mechanoreceptors of the pulp, causing a short sharp pain indicative of a normal pulp. The results obtained with the use of thermal stimulation (heat or cold) are particularly important because of its ability to reproduce the patient's chief complaint. A response that lingers for more than 15–20 s after the thermal stimulus has been removed is frequently interpreted as indicating an irreversibly inflamed pulp. No response from the patient to a thermal stimulation can be regarded as an indication of a necrotic pulp. Obviously a diagnosis should not be accomplished on the basis of a single test. Selecting between cold and heat testing is based on a patient symptomology; a complaint of

heat sensitivity would indicate a heat test should be preformed. In a patient that does not report a history of thermal pain, a cold test should be used first due to its simplicity and reliability. Some teeth with irreversible pulpitis may need repetitive stimuli to achieve the threshold that causes pain. It is also important to recognize that once a tooth has been stimulated thermally, there can be a refractory period of several minutes before a second cold or heat stimulation can provoke the same response.

2.15.1 Cold

Cold testing is technically the simplest pulpal test to perform. It can be accomplished by using one of several different cold stimulus including ice sticks ($\sim 0^\circ\text{C}$), ethyl chloride ($\sim -5^\circ\text{C}$), frozen carbon dioxide ($\sim -75^\circ\text{C}$), or a pressurized refrigerant spray containing either 1,1,1,2 tetrafluorethane, or dichlorodifluoromethane ($\sim -26^\circ\text{C}$). Although all of these methods have been successfully demonstrated, refrigerant spray applied to a small cotton pellet is the best at achieving a predictable low temperature in a convenient and efficient manner. It is also significantly more effective than either an ice stick or ethyl chloride. Cold stimulus should be applied to a tooth until the patient definitively responds or for a maximum of 15 s.

In some instances, cold can relieve a patient's pain. Typically, these patients will present with a container of ice-cold liquid that they will periodically sip to relieve their pain. In these patients, application of cold to the individual offending tooth will eliminate the pain, thus allowing the dentist to make a diagnosis of irreversible pulpitis. Concerns about potential damage done to porcelain restorations or enamel have been dismissed [42].

2.15.2 Heat

Heat testing is not typically the first test performed; however, it may be indicated if a patient reports heat sensitivity as part of their chief complaint or when other tests fail to establish enough information to make an accurate diagnosis. The simplest and most practical way of performing a heat test is to use gutta-percha softened in a flame or with an electric heat carrier. The application of the heat stimulus to a tooth should not last for more than 5 s in order to prevent permanent pulpal damage. From this perspective, it is important to use a separating medium, such as Vaseline, so that the heated gutta-percha does not stick to the tooth being tested. Alternatively, a rubber dam can be applied to each tooth to be tested individually and hot water can be flowed around the tooth. This allows for isolated testing of individual teeth.

2.16 Electrical Pulp Test

Electric pulp testing (EPT) is based on the stimulation of sensory nerve fibers within the pulp. Electric pulp testing does not give any information on the degree of health or disease of a pulp. A positive response is merely an approximate indicator of the

presence of vital neural fibers in the pulp. It entails a subjective evaluation from the patient. The basic principle of the electric pulp tester is to deliver a high-frequency direct electric current through the tooth. The electrical stimulus, like other pulp testing techniques, is best applied to the enamel of the buccal surface of the mesiobuccal cusp. A small amount of a conducting agent such as toothpaste should be applied to the tip of the testing probe. When the probe is applied to the tooth, the level of electric current transmitted through the tooth gradually increases. The operator sets the rate at which the current increases. The electrical circuit needs to be completed by placing the connecting sensor in contact with the patients' soft tissue. This can be accomplished by either placing the sensor on the patient's bottom lip or by having them hold the sensor. Having the patient hold the connecting sensor to discontinue the EPT circuit gives the patient more control over the process and may result in more reproducible test results. It can be difficult to use on crowned teeth; an additional smaller probe may be required to stimulate the tooth structure apical to the crown margin. Care must also be taken not to stimulate the soft tissues in this situation. The EPT is useful in older patient or in teeth that have undergone pulp canal obliteration/mineralization where cold stimulus may be insufficient to provoke the remaining neural tissue [43].

The use of EPT in patients with surgically implanted pacemakers has been controversial; early animal studies indicated that EPT could cause interference in the pacemaker [44]. Since the time of this study, pacemakers have continued to undergo development. In vitro studies carried out in the 1980s and 1990s have indicated no interaction between pacemakers and EPTs [45–47]. In a 2006 study in patients with implanted cardiac pacemakers or cardioverter/defibrillators, the use of a simulated EPT did not produce any interference effects [48].

2.17 Pulpal Testing Accuracy

In considering the accuracy of a pulpal test, it is important to have an understanding of the rate of disease with the general population. The prevalence of non-endodontically treated teeth with periradicular disease in the general population as defined by the presence of periradicular radiolucency is approximately 2% of all teeth [49]. Additionally, 5.4% of the patients reporting to an emergency room presented with a dental problem not associated with trauma [50]. The presence of frequent pain in the region of the mouth in the general population is approximately 5–14% [51]. The prevalence of pulp disease in patients seeking treatment for pain in the facial region in an endodontic specialty practice has been shown to be as high as 88%.

Traditionally, terms used to describe the accuracy of a diagnostic test (pulp testing) are sensitivity and specificity. Sensitivity (true positive rate) is the rate at which a test correctly predicates a diseased state; that is, the number of diseased pulps as indicated by a test divided by the actual total number of diseased pulps. Specificity (true negative rate) is the rate at which a test correctly predicates a healthy state; that is, the number of healthy pulps as indicated by a test divided by the actual total number of healthy pulps. Thus, a test can have four predicative results: true positive: diseased pulps correctly diagnosed as diseased pulps; false positive: healthy

pulps incorrectly identified as diseased pulps; true negative: healthy pulps correctly identified as healthy pulps; and false negative: diseased pulps incorrectly identified as healthy. Part of the difficulty in accessing accuracy of pulp testing is that the same test is used to identify several different states of health and disease of the pulpal tissue. The fact that thermal tests and EPT results report no response to the test as positive can also be confusing. Furthermore, the literature reports the results in terms of categories of vital and nonvital or pulp necrosis. The confusion then is that a tooth can test for a disease state that is irreversible pulpitis and still be in the vital category. Thus, in terms of sensitivity, specificity, and predictive value, much of what is reported is in reference to differentiating between no pulp and some pulp present in the tooth.

The accuracy and value of EPT has been questioned chiefly due to the high rate of false positive responses that can occur. However, a negative response to EPT has a high positive predictive value. EPT correctly identified 71 % of the necrotic pulps (sensitivity) and 92 % of the vital pulps (specificity) [40]. Generally, studies on sensitivity and specificity of EPT report a 90 % plus specificity, but a large range in sensitivity from 21 to 87 % [40]. Additionally, it is important to understand that a response to EPT is not an indication of healthy pulp tissue. A reading from an EPT cannot be used to differentiate between normal pulp, reversible, or irreversible pulpitis [52].

The true value in EPT testing is identifying teeth that have potentially vital pulp tissue that fail to respond to cold thermal insult. It is extremely rare to have false negative responses to EPT.

The specificity (the ability to identify healthy pulp) of cold tests reported in the literature ranged from 10 to 98 %, while sensitivity (the ability to identify pulp necrosis) is typically greater than 75 % [40]. Additionally, the incidence of false negative to cold response increased with age and has been reported to be in 14 % of population over 50 and 20 % in population over 60 years of age [41]. The specificity of heat tests has been reported to range from 5 to 66 %, while sensitivity is typically greater than 65 %. Thus, the accuracy of heat testing when simply evaluating vitality is low.

In general, these tests exhibit high negative predictive values, typically 0.80–0.90. It is very likely that patients who have a negative test result are indeed disease-negative [53]. One study has reported an accuracy of 86 % for the cold test, 71 % for the heat test, and 81 % for the electrical test [41]. This is of particular importance when differentiating between pain of odontogenic origin and pain of a non-odontogenic origin.

Pulp testing in children is a complicated process and can be very subjective. A child's linguistic development and expectation can significantly influence their response to various tests and questions [54, 55]. Diagnosis can be confused by the patient's subjective symptomatology, reduced linguistic development coupled with greater expectations of a negative experience results in a less discerning response [54, 55]. Response to pulp testing is also less predictable than in adults, with a greater likelihood of false negatives. Typically, the response to cold stimulus generates the most dependable outcome in children [56, 57]. Electric pulp testing in teeth with open immature apices can result in a greater percentage of false negatives [58].

2.18 Periradicular Tests

2.18.1 Percussion

Percussion of an individual tooth will stimulate nerve tissue within the periodontal ligament and as such is a test reflective of inflammation within the periodontal ligament that is causing pain. As a clinical test, it shows a high sensitivity for detecting periradicular inflammation that produces pain. It is important to note that not all inflammatory changes in the periodontium are due to pulpal demise. It can occur as a result of periodontal disease or occlusal disharmony or periradicular pathology of non-pulpal origin. Traumatic occlusion from a recent restoration is a primary example where inflammation of the periodontal ligament is caused by constant irritation during function as a result of a premature occlusal contact or an occlusal interference during lateral and/or protrusive or excursive movements of the mandible. Therefore, this test should be used in conjunction with additional information to establish a diagnosis.

A percussion test is best performed in a graduated manner. A patient in a considerable degree of pain will not appreciate a tooth being tapped aggressively. Furthermore, an aggressive tapping may not be needed to differentiate between teeth. The best approach to percussing patients' teeth is to start out with a light tap using a gloved finger and progress to a heavier tap using a plastic instrument such as a "tooth slooth," moving eventually to the use of a mirror handle if the offending tooth cannot be identified with gentler methods. It is also best to ask the patient to differentiate between teeth in a blinded manner. Similar to pulpal testing, teeth should be tested in an order that establishes a base line level for a normal response for each patient. First, percuss a similar contralateral tooth, then percuss teeth either side of the tooth that is primarily suspected as being the source of the symptoms. The patient should be asked to evaluate their response to the percussion of teeth in a comparative manner that avoids identifying the teeth. For example, identifying the teeth as A, B, and C and then asking the patient to identify which is the most painful or sensitive. This can then be repeated, changing the teeth that are identified by each letter. This technique will identify which tooth is consistently the most tender or responsive to percussion. In molar teeth, it is useful to percuss a tooth on the occlusal and buccal surface of the tooth.

2.18.2 Biting

The biting test is indicated if a patient reports pain while biting or chewing. The two most likely causes of biting pain are:

- The spread of pulpal pathology into the periradicular tissue causing periradicular periodontitis.
- A cuspal fracture that may or may not extend into the root structure.

The deciding factor in differentiating between these two conditions is the response to biting using a tooth slooth that directs the biting force to an individual

cuspl. Each cuspl of a given tooth should be loaded in a sequential manner. Having placed the concave aspect of the tooth slooth on a tooth cuspl, the patient should then be asked to bite down of the opposing side of the device until firm pressure is being applied. The patient should then be asked to hold the pressure for a few seconds and then advised to release the biting pressure. They should then be asked to identify whether the pain was elicited during the pressing or releasing phase of biting. It is important to make the patient aware of this difference prior to carrying out the test. Pain on release is frequently associated with a fracture in the tooth.

2.19 Imaging: Radiography

The collection and collation of pertinent information is central to the establishment of an appropriate and accurate diagnosis in all fields of medicine and dentistry. While endodontic tests such as thermal, percussion, and palpation remain relatively primitive, imaging techniques have become more sophisticated than could have been imagined just a decade ago. The judicious use of these imaging techniques has facilitated the enhancement of diagnostic acuity especially in molar endodontics where anatomical structures can obfuscate the view. It is taken for granted that a full medical history is taken before exposing a patient to radiographs. As a note of caution, it is highly recommended that the clinician should never rely on a radiograph from another source as the sole source for diagnosis.

It has been well established that increasing the number of periapical images of a tooth increases the accuracy of the interpretation of the presenting clinical scenario [59]. The addition of bitewing radiographs to the radiographic survey has long been recommended. The bitewing frequently provides information not easily gleaned from a periapical image such as carious lesions, furcation perforations, or defective restorations (Fig. 2.2). It is useful in determining the crestal bone level and draws attention

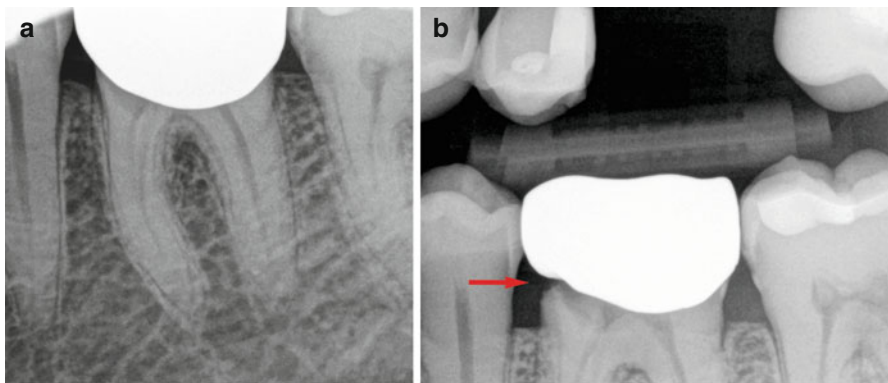


Fig. 2.2 (a) Periradicular radiograph of a mandibular first molar tooth. (b) Bitewing radiograph of the same tooth; note the marginal defect of the crown and associated caries on the mesial aspect of the tooth; (*red arrow*)

to periodontal problems. Alveolar bone loss in the furcation area can be clearly identified on the bitewing. The bitewing provides additional information about the teeth of the opposing arch as well as of the arch under investigation and frequently can direct the examiners eye to a possible problem on an opposing tooth that might be overlooked with periapical films alone. A periapical image focuses on a single tooth and its immediate neighbors. Paralleling devices such as the Rinn XCP should be used.

In recent years, extraordinary advances in three-dimensional imaging techniques have dramatically altered the clinician's perspective on the actual clinical situation. Digital radiography is currently widely available and considering the massive advantages provided by the technology, the use of "wet-film" radiographs can no longer be recommended. Digital radiography has allowed for an enormous (80–90%) reduction in exposure of patients to ionizing radiation in comparison to that from D-speed films. It has eliminated the need for darkroom processing, thereby removing the vagaries of the developing process, and eliminated the use of some very noxious, environment-unfriendly chemicals. The digital process facilitates storage and retrieval of images. In addition, digital radiographs can be easily viewed on large-format monitors enhancing the clinician's ability to discern variations in the image, all the while providing for an exceptional educational experience for the patient. Additionally, digital images are easily shared with other health care professionals.

Radiographs provide the clinician with information on the status of the surrounding tissues and details of the anatomy of the tooth itself. Molar teeth present their own particular set of imaging dilemmas, which frequently complicate the assessment of the case. The use of cone beam computed tomography (CBCT) has greatly reduced these difficulties and the routine use of small-field CBCT in molar endodontic treatment is considered by the authors to be a judicious use of radiation. The concept of ALARA (As Low As Reasonably Achievable) can be upheld with the use of modern CBCT imaging techniques as the doses of radiation are relatively small and the benefits to the patient are great. The effective radiation dose from a maxillary posterior CBCT is 1.4 times the radiation dose of a digital PA film, while that of a mandibular CBCT is about five times that of a digital PA film [60]. Being able to clearly visualize the morphology of the tooth and anatomical structures of the surrounding tissues is a huge advance available to the clinician performing molar endodontics. The guesswork involved when viewing a two-dimensional shadow of a three-dimensional structure has been eliminated or at least greatly reduced (Fig. 2.3). Precise assessment of the relationship of structures to surrounding tissues can be made. Precise location of canals can be established, thereby reducing the amount of "searching" the clinician needs to do to locate the orifices (Fig. 2.4).

Structures that need to be examined on the radiographic survey include but are not limited to:

- Enamel, dentin, and cementum
- Pulp space(s) and pulp space inclusions such as pulp stones
- Tooth morphology (number and length of roots/canals; pulp chamber dimensions)

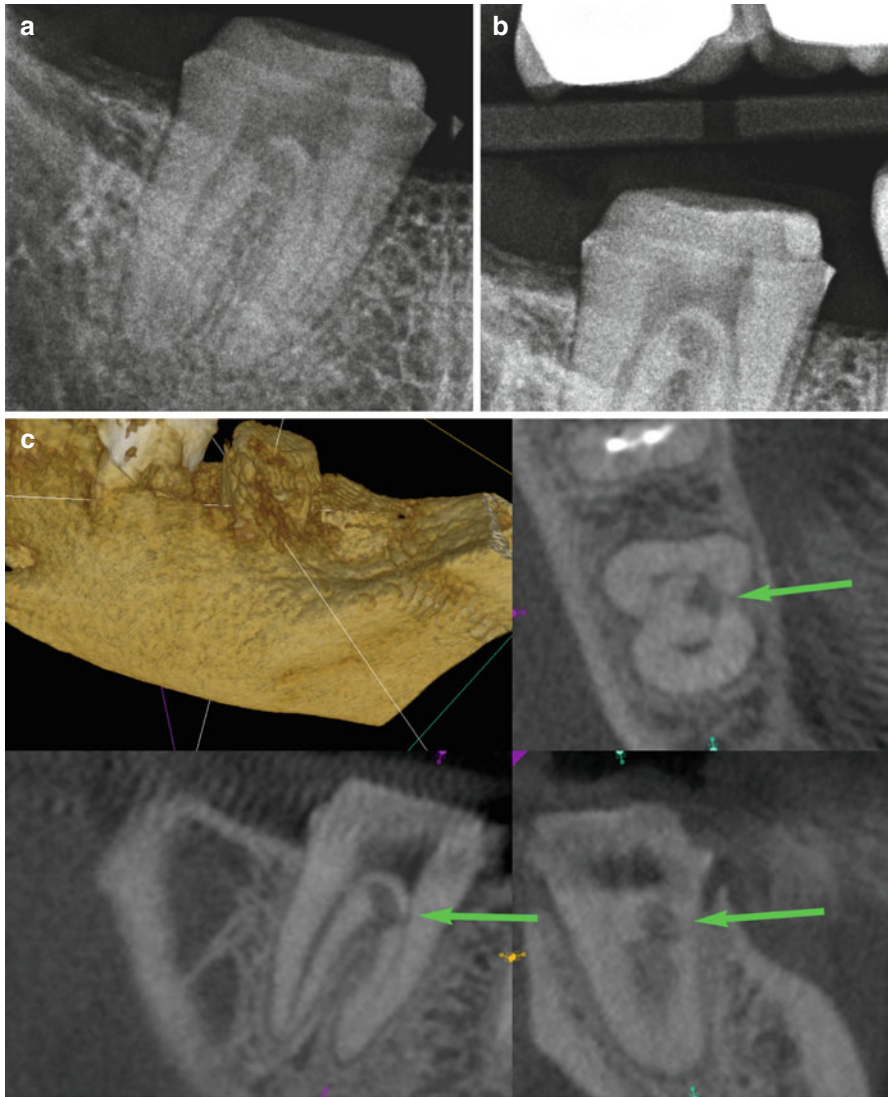


Fig. 2.3 (a) Periradicular radiograph of a mandibular second molar tooth. (b) Bitewing radiograph of the same mandibular second molar tooth. (c) CBCT of the same mandibular second molar tooth demonstrating the position of root resorption in the furcation of the tooth as indicated by the *green arrows*

- Restorations and carious lesions
- Periodontal ligament and its relationship to the root structure and adjacent bone
- Cancellous and cortical bone and variations from normal
- Adjacent anatomical structures such as maxillary sinus and inferior alveolar canal
- Variations in these structures and relationships from the norm

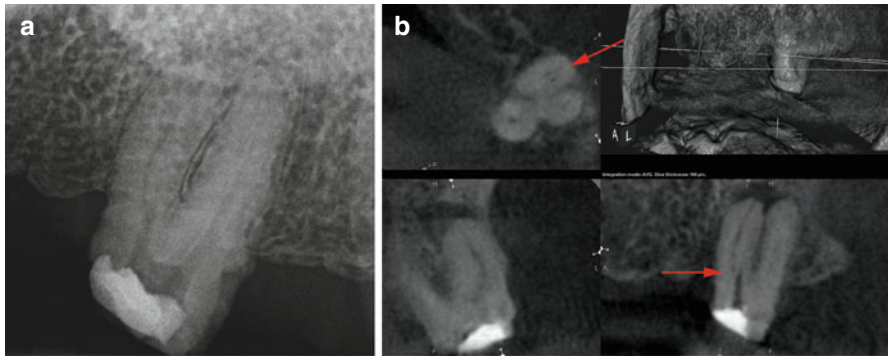


Fig. 2.4 (a) Periradicular radiograph of maxillary second molar tooth. (b) CBCT the same maxillary second molar tooth showing the position of the MB canal in relationship to the previous attempt to access this canal (*red arrow*)

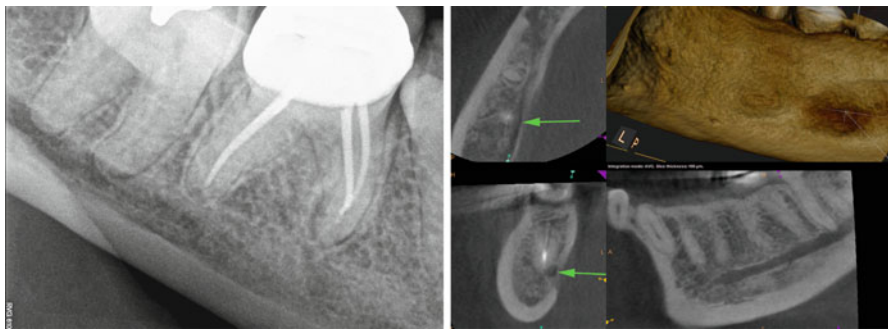


Fig. 2.5 *Left:* periradicular radiograph of an endodontically treated mandibular first molar tooth. *Right:* CBCT of the same mandibular first molar tooth; note the superimposition of the anatomical structures over the tooth anatomy; (*green arrows*)

It is incumbent on the clinician to carefully examine all radiographic images and to report on the findings. It can be said that whatever is visible on a radiographic survey, must be examined and reported on. In cases where there might be any uncertainty, the services of a dental radiologist must be sought. As a consequence, it is appropriate for the clinician performing endodontics to use a small field of view imaging technique that limits the scope of the radiographic examination to the structures of interest.

Periapical radiographic interpretation of molar teeth is associated with a relatively high degree of uncertainty either from errors in interpretation or variability in assessment of the films [61, 62]. Common errors in interpretation in the molar region include false widening of the periodontal ligament space and the superimposition of anatomical structures over the tooth anatomy (Fig. 2.5). False widening of the PDL space may manifest in situations where the tooth apex has fenestrated through the cortical plate of bone or where an air space such as the maxillary antrum is superimposed over it (Fig. 2.6). Other examples of potential errors include the

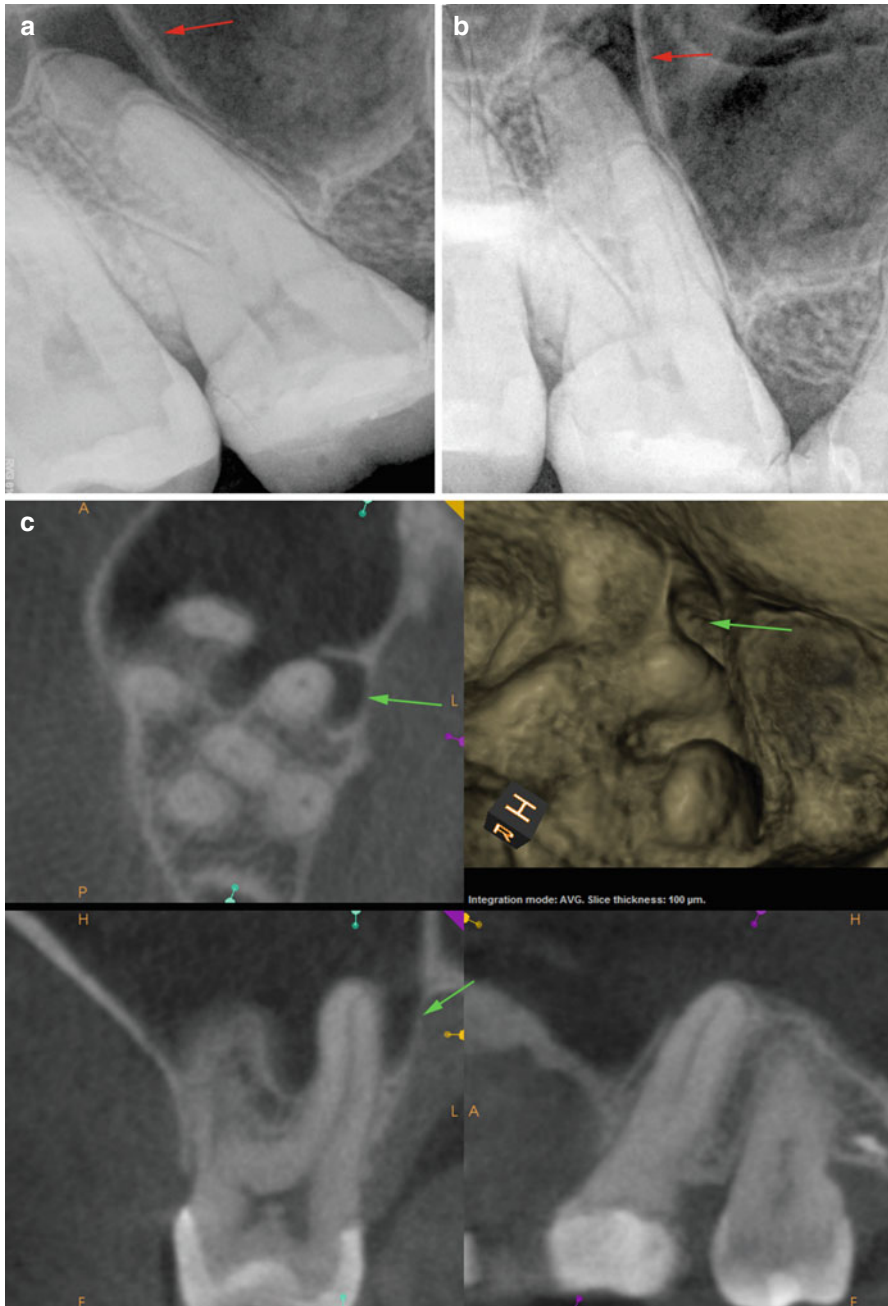

Fig. 2.6 (a, b) Periradicular radiographs of a maxillary first molar tooth showing what appears to be a radiolucency associated with the palatal root; (*red arrows*). (c) CBCT of the same tooth clearly showing that region of radiolucency is related to the position of the maxillary sinus relative to the apex of the palatal root; (*green arrows*)

superimposition of the mental foramen over the apex of lower mandibular teeth and the relationship of the inferior alveolar canal to the apices of molar teeth.

Having identified the need for endodontic treatment based on both the pulpal and periradicular diagnoses, the radiographic information gathered will facilitate the treatment procedure. One of the greatest causes of failure of molar endodontics is failure of the clinician to locate and treat all parts of the canal system [63]. The appropriate radiographic imaging techniques (periapicals and/or CBCTs) will provide the clinician with the information to address these shortcomings (Figs. 2.6 and 2.7). CBCTs are especially helpful in this respect (Figs. 2.6, 2.7, and 2.8).

It is important for the clinician to recognize abnormal structures or changes on a radiograph and arrange for these variations to be investigated. A list of these radiographic impressions is listed here:

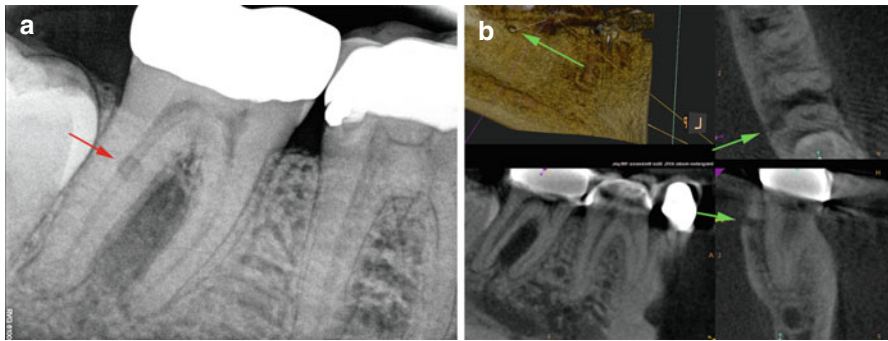


Fig. 2.7 (a) Periapical radiograph of a mandibular second molar tooth showing a radiolucency overlying the distal canal; (*red arrow*) (possibly external root resorption). (b) CBCT of the same tooth showing that that region of radiolucency is a defect in the lingual cortical plate of the mandible; (*green arrows*)

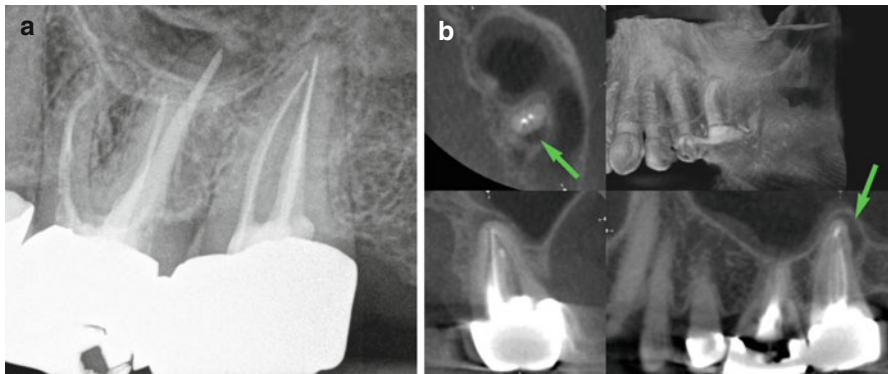


Fig. 2.8 (a) Periapical radiograph of a maxillary second molar tooth. (b) CBCT of the same tooth clearly showing a region of radiolucency at the distal apical aspect of the tooth; (*green arrows*)

2.19.1 Radiolucent Variations

- Dentigerous cyst
- Primordial cyst
- Residual cyst
- Nasopalatine duct cyst
- Globulomaxillary cyst
- Keratocyst
- Lateral periodontal cyst
- Median palatal cyst
- Traumatic bone cyst
- Scar tissue
- Ameloblastoma
- Ameloblastic fibroma
- Central giant cell granuloma
- Metastatic carcinoma

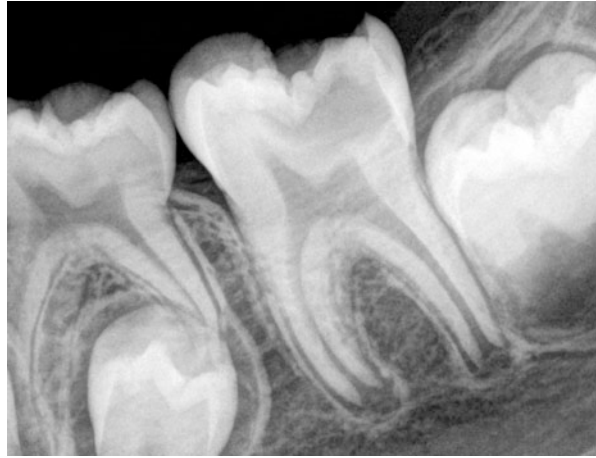2.19.2 Radiopaque Variations

- Condensing osteitis
- Fibrous dysplasia
- Ossifying fibroma
- Odontoma
- Cementoma
- Osteoblastoma
- Osteosarcoma

2.19.3 Children

Knowledge of the radiographic appearance of normal root development is crucial to correctly diagnosing periradicular disease associated with immature teeth (Fig. 2.9). The buccal–lingual dimension of the root canal proper is normally greater than the mesial–distal dimension [64]. A root canal with near parallel walls mesiodistally tends to have divergent walls and greater width labiolingually; a canal with tapering walls mesiodistally tends to have parallel walls and greater width labiolingually. This lag in root development usually exists for more than 3 years after eruption of the tooth [65]. This developmental mode can be misleading with respect to convergence and divergence. The buccal–lingual aspect of the root canal is the last to converge as the root develops, potentially a radiograph will show an apically convergent root canal, in which the buccal–lingual plane is divergent [64]. The tissue forming apically could appear radiographically complete, but is often porous as the developing root in the labiolingual plane lags behind that in the mesiodistal plane of the immature root [66]. However, with the advent of cone beam computerized tomography, the difficulty in assessing apical formation is reduced [67].

Fig. 2.9 Periradicular radiograph of a mandibular first molar with open apices



2.20 Pulpal Diagnostic Categories (Boxes 2.5 and 2.6)

2.20.1 Normal

Dentin Hypersensitivity The short, exaggerated, sharp painful response elicited when exposed dentin is subjected to thermal, mechanical, or chemical stimuli. Key to establishing this diagnosis is the duration of the response following removal of the stimulus. Once the stimulus is removed, the pain will abate quickly. This will typically be accompanied by a diagnosis of normal periradicular tissues. This is also frequently associated with a gingival recession, lost restoration, exposed dentinal tubules following a hygiene appointment, etc.

Reversible Pulpitis A clinical diagnosis based on subjective and objective findings indicating that the inflammation should resolve and the pulp return to normal. Key to establishing this diagnosis is the duration of sensation following removal of the stimulus. Once the stimulus is removed, the pain will abate quickly. This will typically be accompanied by a diagnosis of normal periradicular tissues. This is frequently associated with a deep caries lesion or a recent deep restoration.

Asymptomatic Irreversible Pulpitis A clinical diagnosis based on subjective and objective findings indicating that the vital inflamed pulp is incapable of healing. This will typically be accompanied by a diagnosis of normal periradicular tissues. This diagnosis would be used if there is a carious pulpal exposure with no clinical symptoms.

Box 2.5: Detailed Pulpal Diagnostic Categories

Pulpal diagnosis	Cold test	Heat test	EPT	Percussion	Radiographic	Periradicular diagnosis
Normal	Responsive No lingering Same as control tooth	Responsive No lingering Same as control tooth	Responsive	Normally responsive	Even PDL space around apex of the tooth	Normal
				Abnormally responsive	Even PDL space around apex of the tooth	Symptomatic apical periodontitis Traumatic occlusion
				Normally responsive	Widen PDL space around apex of the tooth	Pathology not of pulpal origin
Dentin hypersensitivity	Responsive No lingering Elevated compared to control tooth	Responsive No lingering Elevated compared to control tooth	Responsive	Abnormally responsive	Widen PDL space around apex of the tooth	Pathology not of pulpal origin
				Normally responsive	Even PDL space around apex of the tooth	Normal
Reversible pulpitis	Responsive No lingering Elevated compared to control tooth	Responsive No lingering Elevated compared to control tooth	Responsive	Normally responsive	Even PDL space around apex of the tooth	Normal
				Abnormally responsive	Even PDL space around apex of the tooth	Symptomatic apical periodontitis
Irreversible pulpitis	Responsive Lingering Elevated compared to control tooth	Responsive Lingering Elevated compared to control tooth	Responsive	Normally responsive	Even PDL space around apex of the tooth	Normal
				Abnormally responsive	Even PDL space around apex of the tooth	Symptomatic apical periodontitis
				Normally responsive	Widen PDL space around apex of the tooth	Asymptomatic apical periodontitis
				Abnormally responsive	Widen PDL space around apex of the tooth	Symptomatic apical periodontitis

Pulpal diagnosis	Cold test	Heat test	EPT	Percussion	Radiographic	Periradicular diagnosis
Pulp necrosis	Nonresponsive	Nonresponsive	Nonresponsive	Normally responsive	Even PDL space around apex of the tooth	Normal/inconclusive
				Abnormally responsive	Even PDL space around apex of the tooth	Symptomatic apical periodontitis
				Normally responsive	Widen PDL space around apex of the tooth	Asymptomatic apical periodontitis
				Abnormally responsive	Widen PDL space around apex of the tooth	Symptomatic apical periodontitis
Previous endodontic treatment	Nonresponsive	Nonresponsive	Nonresponsive	Normally responsive	Even PDL space around apex of the tooth	Normal
				Abnormally responsive	Even PDL space around apex of the tooth	Symptomatic apical periodontitis
				Normally responsive	Widen PDL space around apex of the tooth	Asymptomatic apical periodontitis
				Abnormally responsive	Widen PDL space around apex of the tooth	Symptomatic apical periodontitis

Box 2.6: Pulpal Diagnostic Categories

Pulpal Diagnosis	
Normal	No symptoms, normal response to pulp tests, no pathology that encroach upon the pulp
Dentin Hypersensitivity	Short, exaggerated, sharp painful response elicited when exposed dentin is subjected to thermal, mechanical or chemical stimuli Frequently associated with a gingival recession
Reversible Pulpitis	Compared to control tooth elevated response elicited when tooth is subjected to thermal stimulus Frequently associated with a deep caries lesion or recent restoration
Asymptomatic Irreversible Pulpitis	Clinical findings indicating that the vital inflamed pulp is incapable of healing Normal response to thermal tests Cariou exposure
Symptomatic Irreversible Pulpitis	Clinical findings indicating that the vital inflamed pulp is incapable of healing Thermal sensitivity Spontaneous pain Lingering pain in response to cold testing May also report referral of pain to the surrounding structures
Pulp Necrosis	Clinical findings indicating the death of the pulp Non-responsive to pulp testing
Previous Endodontic Treatment	Clinical findings indicating that the tooth has been previously treated by endodontic therapy Pulpotomy Pulpectomy Non-surgical root canal treatment

Symptomatic Irreversible Pulpitis A clinical diagnosis based on subjective and objective findings indicating that the vital inflamed pulp is incapable of healing. Typically, the patient will report thermal sensitivity, spontaneous pain. The hallmark of this diagnosis is lingering pain in response to cold testing. They may also report referral of pain to the surrounding structures.

Pulp Necrosis A clinical diagnostic category indicating death of the dental pulp. The pulp is usually nonresponsive to pulp testing.

Previous Endodontic Treatment A clinical diagnostic category indicating that the tooth has been previously treated by endodontic therapy (e.g., pulpotomy, pulpectomy, nonsurgical root canal treatment).

2.21 Periradicular Diagnostic Categories (Box 2.7)

2.21.1 Normal

Asymptomatic Apical Periodontitis Inflammation and destruction of apical periodontium that is of pulpal origin, appears as an apical radiolucent area, and does not produce clinical symptoms.

Symptomatic Apical Periodontitis Inflammation usually of the apical periodontium, producing clinical symptoms including a painful response to biting and/or percussion or palpation. It may or may not be associated with an apical radiolucent area.

The flowcharts (Figs. 2.10 and 2.11) provide decision trees to guide clinicians to integrate pulp tests and radiographic findings, in order to arrive at correct diagnoses for most molars with endodontic treatment needs. Several complicating factors that add complexity to molar diagnoses are described below.

2.22 Cracked/Fractured Teeth

Diagnosis of fractures or cracks in molar teeth is a difficult and perplexing problem unless the evidence is overwhelming to the point that it is blatantly obvious. A fracture in a tooth can range from a craze line to a completely split tooth, or somewhere in the continuum between these two aspects. The American Association of Endodontists have classified five specific variations of cracked teeth: craze line, fractured cusp, cracked tooth, split tooth, and vertical root fracture. Craze lines affect only the enamel. Fractured cusps, cracked teeth, and split teeth begin on the occlusal surface and extend apically, affecting enamel,

Box 2.7: Periradicular Diagnostic Categories

	Periradicular Diagnosis
Normal	No symptoms and normal apical periodontium
Asymptomatic Apical Periodontitis	Apical radiolucency of pulpal origin, does not produce clinical symptoms
Symptomatic Apical Periodontitis	Producing clinical symptoms including a painful response to biting and/or percussion or palpation Apical radiolucency may or may not be present
Pathology of Non Pulpal Origin	Apical radiolucency of non pulpal origin, may or may not produce clinical symptoms

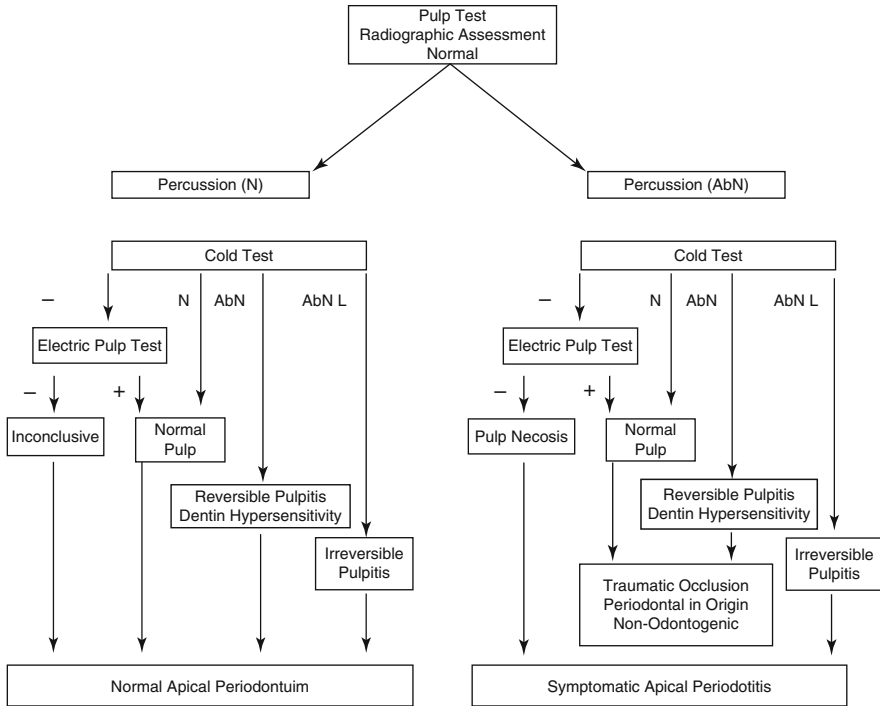


Fig. 2.10 Flowchart for pulp test when radiographic assessment is normal. *N* normal, *AbN* abnormal, *AbN L* abnormal and lingering

dentin, and possibly the pulp; whereas, true vertical root fractures originate in the root. Once the fracture has extended to and exposed the pulp, severe pulp and/or periapical pathology will likely be present and the prognosis for tooth retention is poor.

2.23 Craze Lines

Craze lines are present in the enamel structure of a tooth. The majority of adult teeth will have craze lines. These are the result of “normal” wear and tear from occlusal action. In molar teeth, they are frequently present in the marginal ridges and extending along buccal and lingual surfaces. These craze lines are asymptomatic and require no treatment. Craze lines are best differentiated from cracks by trans-illuminating the tooth. In a tooth with a true craze line the whole tooth will be illuminated, whereas in a cracked tooth the light will not progress through the crack line into the adjacent segments.

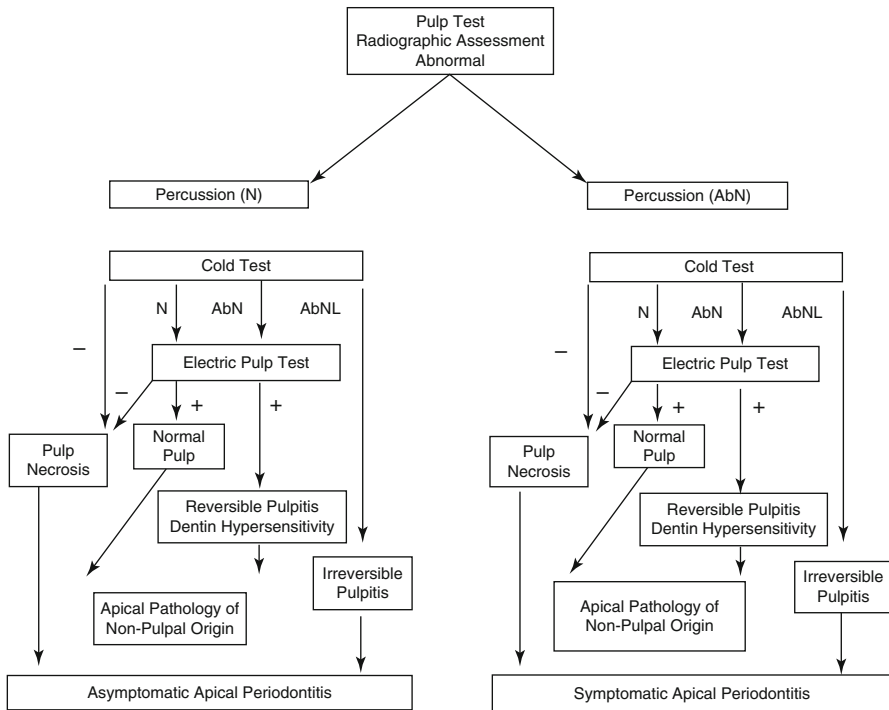


Fig. 2.11 Flowchart for pulp test when radiographic assessment is abnormal. *N* normal, *AbN* abnormal, *AbNL* abnormal and lingering

2.24 Fractured Cusp

A fractured cusp typically involves a vertical and horizontal component of the tooth. The degree of extension can be variable. It can be a complete or an incomplete fracture that is initiated from the crown and extends obliquely in a gingival direction. Occlusally, a fractured cusp can appear to be off-center; this can help differentiate it from a cracked tooth. Classically, if the fracture progresses it will shear off a cusp completely. The pulp may or may not be exposed as a result of this and the fracture may also progress below the gingival attachment.

Frequently, a molar tooth with a cuspal fracture and a Class II restoration can lead to a destabilized marginal ridge. Typically, the crack results in sporadic sharp pain during mastication that can be simulated when a patient applies pressure to the individual offending cusp. A biting test of the cusp will elicit brief, sharp pain, especially upon release of biting pressure. Typically, the pulpal response to thermal

testing will either indicate a normal pulp or possibly reversibly inflamed pulp. Percussion assessment is also frequently normal unless the percussion is in a direction such that it causes movement of the cusp. Similarly, radiographic assessment will also be normal or inconclusive.

2.25 Cracked Tooth

A cracked tooth will have an incomplete fracture that begins in the coronal tooth structure and progresses in the coronal to apical direction toward the gingiva. Typically, the crack will be in a mesiodistal direction and may involve one or both marginal ridges and proximal surfaces. Key to this categorization is that the fracture is located totally within the crown portion of the tooth. A crack may rarely be buccolingual in mandibular molars. In maxillary molars, a crack can be present as an extension of the distolingual groove. The rate of cracks in molar teeth referred to an endodontic office appears to be approximately 11 % with the following distribution: 8.5 % in maxillary molars, 17.5 % in mandibular second, and 11 % in mandibular first molar teeth [68]. The rate in the general population is expected to be less than that reported in a specialty office. A cracked tooth that has not progressed to involve the pulp or periodontal tissues can be difficult to differentiate from a cuspal fracture. Similar to a cuspal fracture, the patient will frequently report sporadic sharp pain during mastication that can be simulated when a patient applies pressure that allows movement in the crack. A biting test of the cusp adjacent to the crack will elicit brief, sharp pain, especially upon release of biting pressure. Percussion assessment is also frequently normal unless the percussion is in a direction such that it causes movement of the cusp. Similarly, radiographic assessment will also be normal or inconclusive. A key component in differentiating these two entities is that the prognosis of a cracked tooth is less favorable than a cuspal fracture. As a crack progresses and the pulp becomes involved, a patient will begin to elicit signs and symptoms consistent with irreversible pulpitis and eventually pulp necrosis and apical periodontitis.

2.26 Split Tooth

A crack that progresses apically down a root will eventually split the tooth. Thus, a split tooth is the progression of a cracked tooth to the extent that the tooth segments are now entirely separate. The signs and symptoms of a split tooth depend on the immediacy of the split. A tooth that has split suddenly will typically display symptoms of irreversible pulpitis with minimal radiographic change. This is more typical of a premolar tooth. A tooth that has split as a result of a progressing crack over a period of time will typically display signs and symptoms of pulp necrosis and either asymptomatic or symptomatic apical periodontitis. Furthermore, radiographic changes will be present.

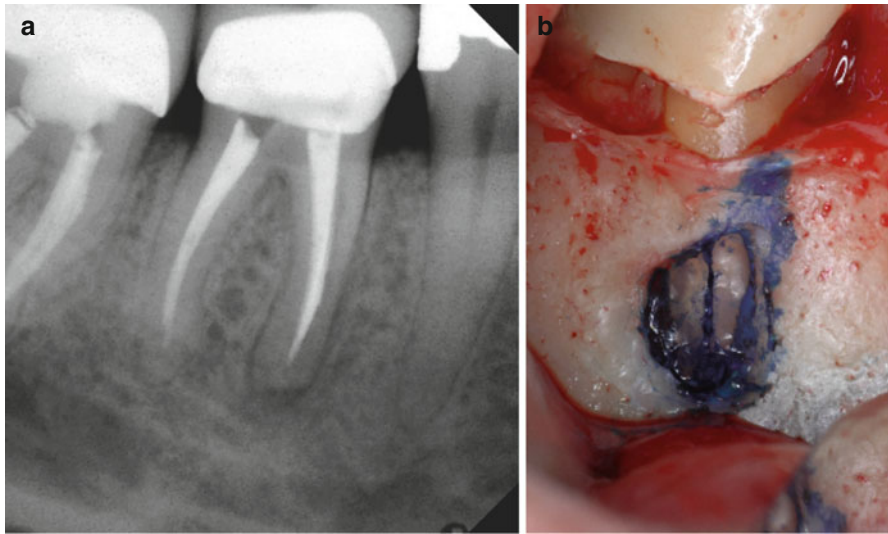


Fig. 2.12 (a) Periradicular radiograph of a mandibular first molar. (b) The same tooth with the buccal tissue reflected to reveal an apical root fracture stained with methylene blue

2.27 Vertical Root Fracture

A “true” vertical root fracture (VRF) is defined as a complete or incomplete fracture initiated from the root at any level, usually directed buccolingually (Fig. 2.12). The key to understanding the term is that the fracture begins in the root structure either at the apex or in the body of the root. Typically, it is a longitudinally oriented fracture of the root, extending from the periodontium to the root canal. It may involve the full length of a root, or a section of the root. This is the difference from a split tooth, which extends from crown to root in a mesiodistal direction. In the endodontic literature these two terms have been frequently interchanged, although from an academic standpoint they are describing a completely different subclass of the category.

2.28 Vertical Root Fracture Versus Advanced Crack

Many of the signs and symptoms for VRF and a cracked tooth in which the crack has progressed apically into the root are similar. Thus, for the purpose of the discussion from this point on, both terms will be referred to collectively as root fractures (Box 2.8). There, two important keys to help identify these conditions in molar teeth. These include periodontal probing and radiographic interpretation. These conditions can occur in teeth with varying degrees of restorative treatment, ranging from non-restored teeth to teeth with full coverage restoration and endodontic treatment. Mandibular molars are among the most prevalent teeth to present with a vertical root

Box 2.8: Root Fracture

Narrow angle probing
Angular radiolucency
J-shaped radiolucency
Abnormally calcified pulp chamber

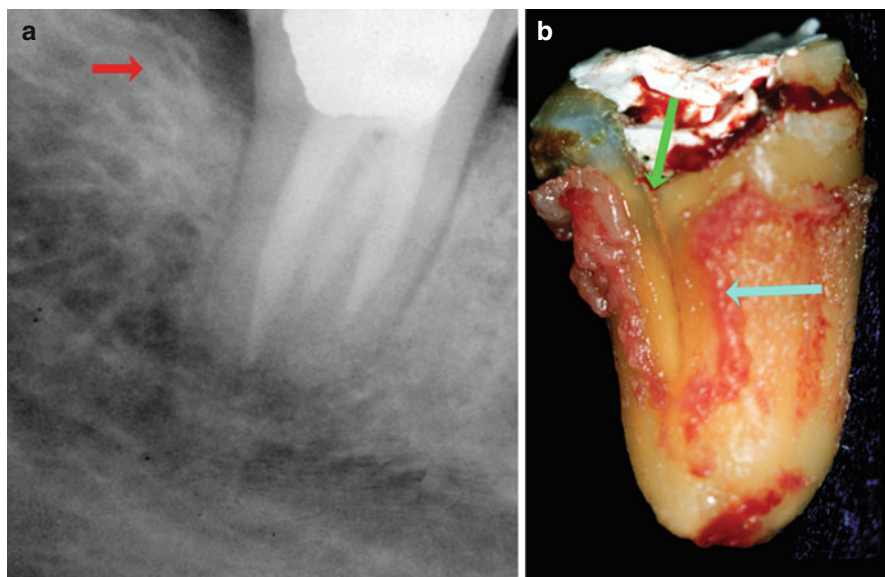


Fig. 2.13 (a) Periradicular radiograph of a mandibular second molar tooth showing an angular bony defect adjacent the distal root of the tooth; (*red arrow*). (b) The same tooth extracted showing the fracture line on the distal root (*green arrow*) and the position of the periodontal ligament adjacent to the fracture line (*blue arrow*)

fracture that has not been endodontically treated. However, the majority of fractures occur in restored teeth, with only approximately 30 % being found in intact teeth that had no history of restorative dental treatment. They are more frequent in populations over the age of 40 years. The highest number of longitudinal fractures occurred in the mesiodistal direction. In a demographic analysis of vertically root fractured teeth, the pulp was vital in only 12 % of the cases, nonvital in 39 % of cases and had been endodontically treated in 49 % of cases [27]. Root fractures are generally only directly visible radiographically in around 30 % of teeth where a fracture is known to be present. In endodontically treated teeth, one the most common signs of vertical root fractures is a narrow deep osseous defect that is generally located on the buccal aspect of the tooth (Fig. 2.13). Various studies have reported a range of approximately 65–95 % for the occurrence of such a defect. Sinus tracts positioned away from the apex of the tooth and located coronally close to the gingival margin can also be a frequent finding occurring in approximately 35–45 % of cases. Additionally, such a sinus tract is frequently associated with the mesial roots of the mandibular molars [69].

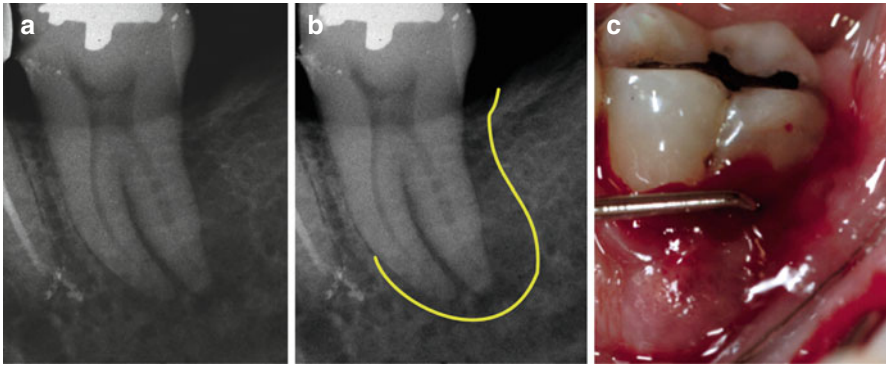


Fig. 2.14 (a) Periradicular radiograph of a mandibular second molar. (b) Periradicular radiograph of the same tooth with a “J-shaped” radiolucency outlined in yellow. (c) Clinical photograph of the same tooth showing deep, narrow-based probing

The most frequent radiographic feature of root fractures in molar teeth is the presence of a “J-shaped” radiolucency (Fig. 2.14) [70]. This forms from a combination of an angular radiolucency from the crestal bone terminating along the lateral side of the root and periapical radiolucency. The angular radiolucency can appear as a diffuse interproximal linear radiolucency of variable width that extends apically from crestal bone along the adjacent root surface. The area of radiolucency is frequently steplike in shape, having an angular rather than rounded appearance at its most apical level. This is typically isolated and occurs on a single tooth surface and not indicative of generalized periodontal disease. Additionally, the interproximal crestal bone in this region will be frequently poorly delineated. As this defect progresses toward the apex of the tooth and as the pulp undergoes necrosis, a “J-shaped” lesion may develop. The key to differentiating this as a fractured tooth is its association with narrow angle probing. Narrow angled probing is defined as narrow rectangular-shaped periodontal pocket, where the sulcus depth immediately adjacent to the pocket tends to be normal. This type of pocket occurs adjacent to a vertical fracture in the tooth structure. Frequently, there is a narrow angle probing in the region of the J-shaped radiolucency. In mandibular molars this is often accompanied by a radiolucency in the furcation region [69]. Another radiographic finding that can be present is an atypical degree of mineralization in the pulp chamber of a nonrestored or minimally restored tooth. Mandibular second molars have the largest incidence followed by mandibular first molars and then maxillary first molars. In endodontic specialty practices, the incidence of fracture in molar teeth appears to be approximately 10% of all teeth referred for assessment [68].

2.29 Tooth Resorption

Tooth resorption is a condition associated with either a physiologic or a pathologic process resulting in loss of dentin, cementum, and or bone [71]. It is classified based on the site, nature, and pattern of process. It is generally differentiated into internal

and external resorption. Occasionally, combinations of both internal and external can be found on the same tooth. In a large part, the diagnosis of the various forms of root resorption is based on a radiographic analysis of the tooth.

2.30 Internal Resorption

Internal resorption is rare in permanent teeth. It is typically associated with traumatic injuries and as such is not found frequently in molar teeth. In luxation injuries it has been recorded as a sequela in approximately 2% of recalled cases. Typically asymptomatic, it is usually discovered during a routine radiographic evaluation and is often misdiagnosed as external resorption. The incidence of internal root resorption in posterior teeth as a percentage of all teeth reported with the condition is 25% in maxillary posterior teeth and 18% in mandibular posterior teeth. Unfortunately, there was no differentiation between premolar and molar teeth [72]. There are two types of internal resorption; root canal replacement resorption and internal inflammatory resorption [73]. Both forms of the disease process appear to result from a low-grade irritation of pulp tissue localized to a small area of the root canal system. Root canal replacement resorption involves resorption of the dentin, and a subsequent deposition of hard tissue that resembles bone or cementum, but not dentin. Internal inflammatory resorption involves a progressive loss of root substance with no hard tissue deposition in the resorption cavity. Typically, both forms of internal resorption are asymptomatic and usually identified on routine radiographs. The affected teeth may respond within normal limits to thermal or electric pulp testing [74]. However, in internal inflammatory resorption, as the coronal pulp becomes necrotic, pulp testing can result in a negative response [75]. The condition can develop symptoms if it progresses to the extent that it perforates the root or crown of the tooth. The tooth may exhibit a pinkish or reddish hue (pink spot) if the resorption occurs in the coronal portion of the tooth. Radiographically, internal replacement resorption usually manifests as enlargement of the normal canal space. In root canal replacement resorption, this space is then occupied with a less radio-dense substance giving the appearance of partial canal obliteration. Internal inflammatory resorption appears as a circumscribed oval-shaped radiolucency continuous with the root canal wall.

2.31 External Resorption

There are many different categorizing schemes for external root resorption [71]. For the purposes of this discussion, external resorption can be classified into four categories by their clinical and histological characteristics: external surface resorption, external inflammatory root resorption, ankylosis/replacement resorption, and root resorption. These categories differentiate external resorption from other pathologies that remain independent of the tooth but that resorb the roots of the teeth in any case. In addition to these four categories, external resorption is often described according to their location on the tooth: cervical, body, or apex of the tooth. Critically, in diagnosing resorption of the tooth root is the ability to identify those odontogenic and

non-odontogenic pathologies of the jaws that can produce external root resorption. Recognizing these types of pathologies is important in avoiding unneeded dental treatment or hindering appropriate medical treatments. Such pathologies include odontogenic keratocyst, lateral periodontal cyst, ameloblastoma, and giant cell reparative granuloma, ossifying fibroma, cementoblastoma, osteoblastoma, osteosarcoma, chondrosarcoma, and metastatic cancer [76–81]. Typically, teeth that are resorbed by these types of diseases will be normally responsive to thermal and electrical pulp testing. However, if the pathology has invaded the neural tissue that supplies the pulp of a tooth, then the pulp may be nonresponsive or inconclusive to testing. If these types of pathologies are suspected, then a biopsy of the lesion is crucial to establish definitive diagnosis. Several medical conditions have also been implicated in the cause of multiple external root resorption; these include Paget's disease of bone, hyperparathyroidism, Gaucher's disease, hypophosphatasia, Papillon-Lefèvre syndrome, hemifacial atrophy, renal and liver diseases, focal dermal hypoplasia (Goltz syndrome), familial expansile osteolysis, and osteogenesis imperfecta. The reader is referred to an oral pathology text for a complete discussion of such conditions. The discussion here will be limited to those conditions that directly relate to the teeth.

2.32 External Surface Resorption

External surface resorption is an ephemeral episodic event where the root surface of a tooth undergoes spontaneous destruction and repair. It is present in all teeth to a varying extent and is likely to be a normal physiological response [82]. It is the least destructive form of external root resorption and is a self-limiting process that requires no treatment [73].

2.33 External Inflammatory Root Resorption

Inflammatory resorption is the most prevalent form of external root resorption. Several etiological factors have been found to cause external inflammatory root resorption. In general, any injury or irritation to the periodontium can produce a resorptive reaction. Such irritation includes trauma, periodontal infection, pulpal infection, orthodontic treatment, or an impacted tooth. Typically, this form of resorption appears as an elliptical-shaped radiographic defect that penetrates into the dentin. It can occur on any part of the root; however, it is frequently subcategorized according to that part of the tooth to which it has occurred such as cervical or apical. As a general rule, external resorption that is not associated with pulpal pathology or orthodontics occurs away from the apex of the tooth and can be differentiated from internal resorption by its radiographic presentation. The resorptive radiolucencies are superimposed over the root canal system. In the case of external inflammatory root resorption in the root apex, a persistent and progressive radiolucency is typically found adjacent to region of root resorption (Fig. 2.15) [74]. The prevalence of cervical external root resorption (Fig. 2.16) in molar teeth has been poorly studied. It is

Fig. 2.15 Mandibular first molar tooth with external inflammatory root resorption of the mesial root apex and associated radiolucency adjacent to region of root resorption

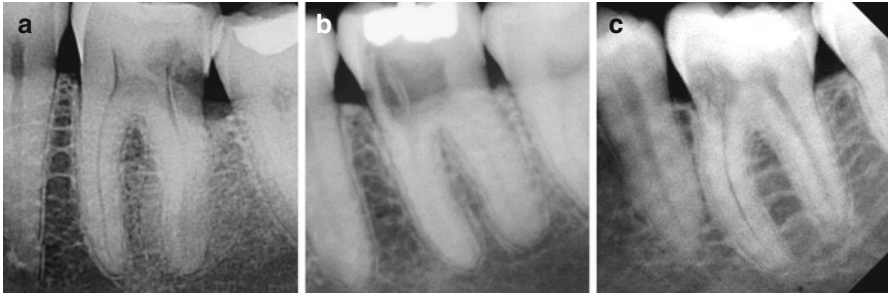
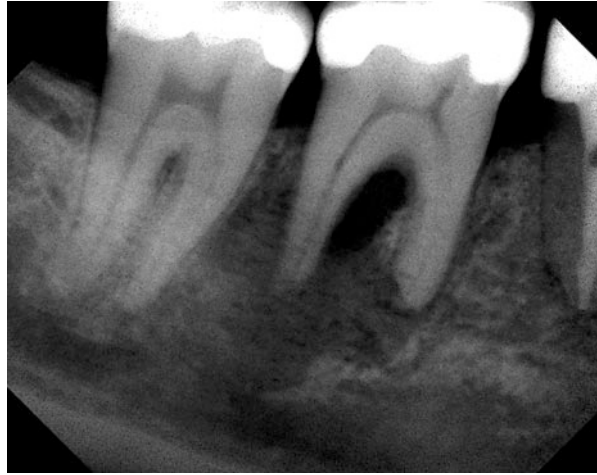


Fig. 2.16 Three variations (a–c) of cervical external root resorption in mandibular first molar teeth

most frequently studied as a sequela of traumatic injuries to anterior teeth. Heithersay reported that cervical external inflammatory root resorption of maxillary and mandibular first molars accounted for approximately 8 % of reported cases [83]. In teeth with apical periodontitis the prevalence of apical external root resorption has been reported to range from 19 to 50 % using radiographic analysis (Fig. 2.17) [84, 85]. In a histological analysis of extracted teeth with apical periodontitis the rate of apical external root resorption ranges from 81 to 100 % [85–88]. Additionally, a Middle Eastern population study on the prevalence of root resorption reported that 28.8 % of all teeth showed radiographs signs of external root resorption. Apical root resorption associated with pulpal infection was the most common. It accounted for 71.2 % of all cases of root resorption and was observed in 20.5 % of the patients. Additionally, all cases were from poorly endodontically treated teeth with radiographic signs of apical periodontitis (Fig. 2.18). Orthodontic pressure and impacted tooth pressure were the next most common cause of resorption, accounting for approximately 7 % of cases [89]. Unfortunately, the study did not differentiate between tooth types and thus the rate of external root resorption may be different when limited to molar teeth.

Multiple idiopathic external root resorption or MIEARR is a bizarre condition that can occur in the cervical or apical region of the teeth. MIEARR affects a wide

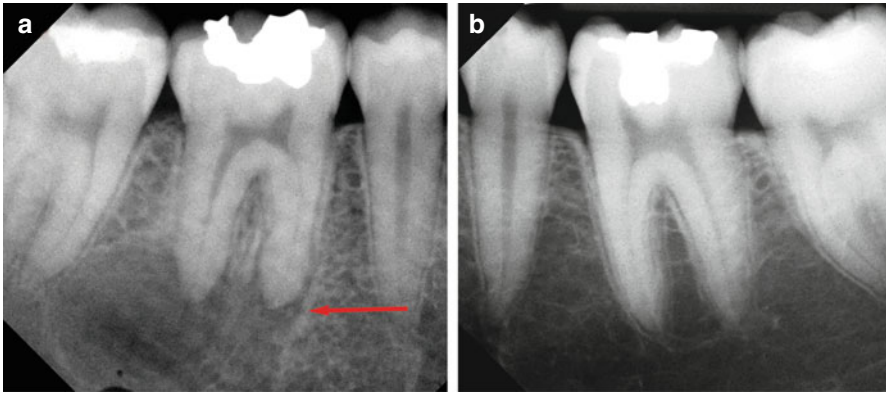
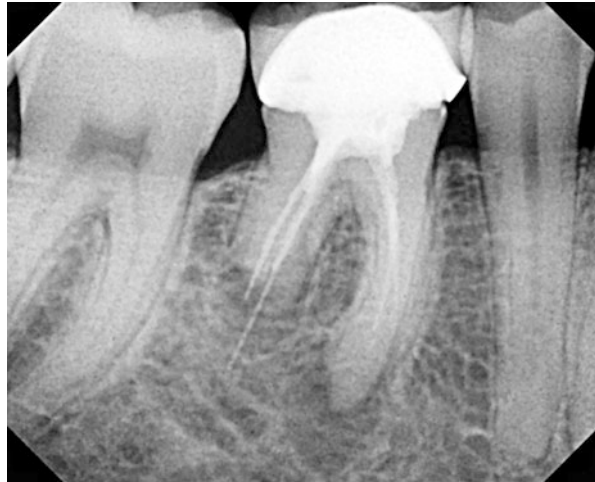

Fig. 2.17 (a) Apical external root resorption associated with apical periodontitis of mandibular first molar tooth; note the blunting of the root apices on the tooth; (*red arrow*). (b) The contralateral mandibular first molar tooth in the same patient with no apical periodontitis

Fig. 2.18 Deficient endodontic treatment on a mandibular first molar tooth with external inflammatory root resorption of the distal root and radiographic signs of apical periodontitis



age range of individuals, with males affected more frequently than females. There appears to be a predilection for premolar and molar teeth in a symmetrical pattern of expression. The current mainstay of management for affected individuals remains long-term monitoring. Endodontic therapy is not indicated at the present time. Furthermore, the etiology of MIEARR remains unknown [90].

2.34 Ankylosis

Ankylosis is the end result of replacement resorption whereby a tooth is no longer capable of normal physiologic movement due to the fusion of bone to the root surface [71]. Ankylosis is primarily associated with history of luxation injuries especially avulsion and thus is not common in molar teeth. Failure of eruption of first

and second permanent molars from all causes not just ankylosis is very rare. However, several case reports have described the condition occurring in molar teeth [91–93]. The prevalence in the normal population is 0.01% for first permanent molar and 0.06% for the second molar [94]. Classically, the tooth will be immobile once it is ankylosed; therefore, percussion of the teeth is an important diagnostic tool. Percussion applied to an ankylosed tooth will give a high-pitched or metallic tone, which will be markedly different from adjacent teeth. Other clinical signs that may be present include infra-occlusion, incomplete alveolar process development in young patient, and lack of normal mesial drift. It is difficult to identify ankylosis on radiographs because of the overlapping structures and bone marrow spaces [95]. However, a complete disappearance of periodontal space and an uneven root surface contour is common when examining the radiograph [96].

References

1. Klausen B, Helbo M, Dabelsteen E. A differential diagnostic approach to the symptomatology of acute dental pain. *Oral Surg Oral Med Oral Pathol.* 1985;59:297–301.
2. Fenlon MR, McCartan BE. Validity of a patient self-completed health questionnaire in a primary care dental practice. *Community Dent Oral Epidemiol.* 1992;20:130–2.
3. Balasubramaniam R, Turner LN, Fischer D, Klasser GD, Okeson JP. Non-odontogenic toothache revisited. *Open J Stomatol.* 2011;1:92–102.
4. Okeson JP, Bell WE. Bell's orofacial pains: the clinical management of orofacial pain. 6th ed. Chicago: Quintessence Publ.; 2005.
5. Vargas CM, Macek MD, Marcus SE. Sociodemographic correlates of tooth pain among adults: United States, 1989. *Pain.* 2000;85:87–92.
6. Cuffari L, Tesseroli de Siqueira JT, Nemr K, Rapaport A. Pain complaint as the first symptom of oral cancer: a descriptive study. *Oral Surg Oral Med Oral Pathol Oral Radiol Endod.* 2006;102:56–61.
7. Linn J, Trantor I, Teo N, Thanigaivel R, Goss AN. The differential diagnosis of toothache from other orofacial pains in clinical practice. *Aust Dent J.* 2007;52:S100–4.
8. Gawande A. The checklist manifesto: how to get things right. New York: Metropolitan Books; 2010.
9. Okeson JP. Management of temporomandibular disorders and occlusion. 7th ed. St. Louis: Elsevier/Mosby; 2013.
10. American Academy of Orofacial Pain; de Leeuw R, Klasser GD. Orofacial pain: guidelines for assessment, diagnosis, and management. 5th ed. Chicago: Quintessence Publ.; 2013.
11. Zakrzewska JM. Multi-dimensionality of chronic pain of the oral cavity and face. *J Headache Pain.* 2013;14:37.
12. Ehrmann EH. The diagnosis of referred orofacial dental pain. *Aust Endod J.* 2002;28:75–81.
13. Mehra P, Murad H. Maxillary sinus disease of odontogenic origin. *Otolaryngol Clin North Am.* 2004;37:347–64.
14. Penarrocha M, Bandres A, Penarrocha M, Bagan JV. Lower-half facial migraine: a report of 11 cases. *J Oral Maxillofac Surg.* 2004;62:1453–6.
15. Sarlani E, Schwartz AH, Greenspan JD, Grace EG. Chronic paroxysmal hemicrania: a case report and review of the literature. *J Orofac Pain.* 2003;17:74–8.
16. Pascon FM, Kantovitz KR, Sacramento PA, Nobre-dos-Santos M, Puppini-Rontani RM. Effect of sodium hypochlorite on dentine mechanical properties: a review. *J Dent.* 2009;37:903–8.
17. Kreiner M, Falace D, Michelis V, Okeson JP, Isberg A. Quality difference in craniofacial pain of cardiac vs. dental origin. *J Dent Res.* 2010;89:965–9.
18. Kreiner M, Okeson JP, Michelis V, Lujambio M, Isberg A. Craniofacial pain as the sole symptom of cardiac ischemia: a prospective multicenter study. *J Am Dent Assoc.* 2007;138:74–9.

19. National Institute of Dental and Craniofacial Research. Oral Cancer Incidence (New Cases) by Age, Race, and Gender. 2013 [cited 2013 November 3, 2013]; Available from: <http://www.nidcr.nih.gov/DataStatistics/FindDataByTopic/OralCancer/OralCancerIncidence.htm>.
20. Gorsky M, Epstein JB, Oakley C, Le ND, Hay J, Stevenson-Moore P. Carcinoma of the tongue: a case series analysis of clinical presentation, risk factors, staging, and outcome. *Oral Surg Oral Med Oral Pathol Oral Radiol Endod.* 2004;98:546–52.
21. Kumar G, Manjunatha B. Metastatic tumors to the jaws and oral cavity. *J Oral Maxillofac Pathol.* 2013;17:71–5.
22. Epstein JB, Voss NJ, Stevenson-Moore P. Maxillofacial manifestations of multiple myeloma. An unusual case and review of the literature. *Oral Surg Oral Med Oral Pathol.* 1984;57:267–71.
23. Hirshberg A, Leibovich P, Buchner A. Metastatic tumors to the jawbones: analysis of 390 cases. *J Oral Pathol Med.* 1994;23:337–41.
24. D'Silva NJ, Summerlin DJ, Cordell KG, Abdelsayed RA, Tomich CE, Hanks CT, et al. Metastatic tumors in the jaws: a retrospective study of 114 cases. *J Am Dent Assoc.* 2006;137:1667–72.
25. Ray HA, Trope M. Periapical status of endodontically treated teeth in relation to the technical quality of the root filling and the coronal restoration. *Int Endod J.* 1995;28:12–8.
26. Madison S, Swanson K, Chiles SA. An evaluation of coronal microleakage in endodontically treated teeth. Part II Sealer types. *J Endod.* 1987;13:109–12.
27. Berman LH, Kuttler S. Fracture necrosis: diagnosis, prognosis assessment, and treatment recommendations. *J Endod.* 2010;36:442–6.
28. Sathorn C, Palamara JE, Palamara D, Messer HH. Effect of root canal size and external root surface morphology on fracture susceptibility and pattern: a finite element analysis. *J Endod.* 2005;31:288–92.
29. Kishen A. Mechanisms and risk factors for fracture predilection in endodontically treated teeth. *Endod Topics.* 2006;13:57–83.
30. Sedgley CM, Messer HH. Are endodontically treated teeth more brittle? *J Endod.* 1992;18:332–5.
31. Papa J, Cain C, Messer HH. Moisture content of vital vs endodontically treated teeth. *Endod Dent Traumatol.* 1994;10:91–3.
32. Belli S, Cobankara FK, Eraslan O, Eskitascioglu G, Karbhari V. The effect of fiber insertion on fracture resistance of endodontically treated molars with MOD cavity and reattached fractured lingual cusps. *J Biomed Mater Res B Appl Biomater.* 2006;79:35–41.
33. Iqbal MK, Johansson AA, Akeel RF, Bergenholtz A, Omar R. A retrospective analysis of factors associated with the periapical status of restored, endodontically treated teeth. *Int J Prosthodont.* 2003;16:31–8.
34. Sorensen JA, Engelman MJ. Ferrule design and fracture resistance of endodontically treated teeth. *J Prosth Dent.* 1990;63:529–36.
35. Gulabivala K, Ng Y-L. *Endodontics*. 4th ed: Mosby; 2014.
36. Simring M, Goldberg M. The pulpal pocket approach: retrograde periodontitis. *J Periodontol.* 1964;35:22–48.
37. Simon JH, Glick DH, Frank AL. The relationship of endodontic-periodontic lesions. *J Periodontol.* 1972;43:202–8.
38. Belk CE, Gutmann JL. Perspectives, controversies and directives on pulpal-periodontal relationships. *J Can Dent Assoc.* 1990;56:1013–7.
39. Harrington GW. The perio-endo question: differential diagnosis. *Dent Clin N Am.* 1979;23:673–90.
40. Mejare IA, Axelsson S, Davidson T, Frisk F, Hakeberg M, Kvist T, et al. Diagnosis of the condition of the dental pulp: a systematic review. *Int Endod J.* 2012;45:597–613.
41. Petersson K, Soderstrom C, Kiani-Anaraki M, Levy G. Evaluation of the ability of thermal and electrical tests to register pulp vitality. *Endod Dent Traumatol.* 1999;15:127–31.
42. Peters DD, Lorton L, Mader CL, Augsburg RA, Ingram TA. Evaluation of the effects of carbon dioxide used as a pulpal test. I. In vitro effect on human enamel. *J Endod.* 1983;9:219–27.

43. Farac RV, Morgental RD, Lima RK, Tiberio D, dos Santos MT. Pulp sensibility test in elderly patients. *Gerodontology*. 2012;29:135–9.
44. Woolley LH, Woodworth J, Dobbs JL. A preliminary evaluation of the effects of electrical pulp testers on dogs with artificial pacemakers. *J Am Dent Assoc*. 1974;89:1099–101.
45. Adams D, Fulford N, Beechy J, MacCarthy J, Stephens M. The cardiac pacemaker and ultrasonic scalers. *Br Dent J*. 1982;152:171–3.
46. Luker J. The pacemaker patient in the dental surgery. *J Dent*. 1982;10:326–32.
47. Miller CS, Leonelli FM, Latham E. Selective interference with pacemaker activity by electrical dental devices. *Oral Surg Oral Med Oral Pathol Oral Radiol Endod*. 1998;85:33–6.
48. Wilson BL, Broberg C, Baumgartner JC, Harris C, Kron J. Safety of electronic apex locators and pulp testers in patients with implanted cardiac pacemakers or cardioverter/defibrillators. *J Endod*. 2006;32:847–52.
49. Pak JG, Fayazi S, White SN. Prevalence of periapical radiolucency and root canal treatment: a systematic review of cross-sectional studies. *J Endod*. 2012;38:1170–6.
50. Quinonez C. Self-reported emergency room visits for dental problems. *Int J Dent Hyg*. 2011;9:17–20.
51. Sanders AE, Slade GD, Lim S, Reisine ST. Impact of oral disease on quality of life in the US and Australian populations. *Community Dent Oral Epidemiol*. 2009;37:171–81.
52. Levin LG. Pulp and periradicular testing. *J Endod*. 2013;39:S13–9.
53. Hyman JJ, Cohen ME. The predictive value of endodontic diagnostic tests. *Oral Surg Oral Med Oral Pathol*. 1984;58:343–6.
54. Harman K, Lindsay S, Adewami A, Smith P. An investigation of language used by children to describe discomfort expected and experienced during dental treatment. *Int J Paediatr Dent*. 2005;15:319–26.
55. Toole RJ, Lindsay SJ, Johnstone S, Smith P. An investigation of language used by children to describe discomfort during dental pulp-testing. *Int J Paediatr Dent*. 2000;10:221–8.
56. Fulling HJ, Andreasen JO. Influence of maturation status and tooth type of permanent teeth upon electrometric and thermal pulp testing. *Scand J Dent Res*. 1976;84:286–90.
57. Fuss Z, Trowbridge H, Bender IB, Rickoff B, Sorin S. Assessment of reliability of electrical and thermal pulp testing agents. *J Endod*. 1986;12:301–5.
58. Klein H. Pulp responses to an electric pulp stimulator in the developing permanent anterior dentition. *J Dent Child*. 1978;45:199–202.
59. Bystrom A, Happonen RP, Sjogren U, Sundqvist G. Healing of periapical lesions of pulpless teeth after endodontic treatment with controlled asepsis. *Endod Dent Traumatol*. 1987;3:58–63.
60. Barnett F. Cone beam-computed tomography in endodontics. *Endodontics: Colleagues for Excellence*. Chicago: American Association of Endodontists. 2011. p. 1–7.
61. Goldman M, Pearson AH, Darzenta N. Endodontic success—who's reading the radiograph? *Oral Surg Oral Med Oral Pathol*. 1972;33:432–7.
62. Goldman M, Pearson AH, Darzenta N. Reliability of radiographic interpretations. *Oral Surg Oral Med Oral Pathol*. 1974;38:287–93.
63. Witherspoon DE, Small JC, Regan JD. Missed canal systems are the most likely basis for endodontic retreatment of molars. *Tex Dent J*. 2013;130:127–39.
64. Camp JH. Pedodontic endodontic treatment. In: Cohen S, Burns RC, editors. *Pathways of the pulp*. 2nd ed. St. Louis: Mosby; 1980. p. 622–56.
65. Duell RC. Conservative endodontic treatment of the open apex in three dimensions. *Dent Clin N Am*. 1973;17:125–34.
66. Gutmann JL, Heaton JF. Management of the open (immature) apex. 2. Non-vital teeth. *Int Endod J*. 1981;14:173–8.
67. Patel S. The use of cone beam computed tomography in the conservative management of dens invaginatus: a case report. *Int Endod J*. 2010;43:707–13.
68. Krell KV, Rivera EM. A six year evaluation of cracked teeth diagnosed with reversible pulpitis: treatment and prognosis. *J Endod*. 2007;33:1405–7.
69. Tsesis I, Rosen E, Tamse A, Taschieri S, Kfir A. Diagnosis of vertical root fractures in endodontically treated teeth based on clinical and radiographic indices: a systematic review. *J Endod*. 2010;36:1455–8.
70. Hargreaves KM, Cohen S, Berman LH. *Pathways of the pulp*. 10th ed. St. Louis: Mosby Elsevier; 2011.

71. American Association of Endodontists. Glossary of Endodontic Terms 2015 [accessed 2/27/2016]; Available from: <http://www.nxtbook.com/nxtbooks/aae/endodonticglossary2015/>.
72. Caliskan MK, Turkun M. Prognosis of permanent teeth with internal resorption: a clinical review. *Endod Dent Traumatol*. 1997;13:75–81.
73. Andreasen JO, Andreasen FM, Andersson L, Andreasen JO. Textbook and color atlas of traumatic injuries to the teeth. 4th ed. Oxford, UK. 4th ed. Oxford/Ames/Iowa: Blackwell Munksgaard; 2007.
74. Benenati FW. Root resorption: types and treatment. *Gen Dent*. 1997;45:42–5.
75. Trope M. Root resorption of dental and traumatic origin: classification based on etiology. *Pract Periodontol Aesth Dent*. 1998;10:515–22.
76. Dunfee BL, Sakai O, Pistey R, Gohel A. Radiologic and pathologic characteristics of benign and malignant lesions of the mandible. *Radiographics*. 2006;26:1751–68.
77. Struthers P, Shear M. Root resorption by ameloblastomas and cysts of the jaws. *Int J Oral Surg*. 1976;5:128–32.
78. Kendell RL. Permanent molar impactions and an odontogenic keratocyst: report of case. *ASDC J Dent Child*. 1990;57:452–3.
79. Ozturk M, Ozec I, Aker H, Muslehiddinoglu A. Osteoblastoma of the mandible with root resorption: a case report. *Quintessence Int*. 2003;34:135–8.
80. Bhadage CJ, Vaishampayan S, Kolhe S, Umarji H. Osteosarcoma of the mandible mimicking an odontogenic abscess: a case report and review of the literature. *Dent Update*. 2013;40:216–8. 21.
81. Kawai N, Wakasa T, Asaumi J-I, Kishi K. A radiographic study on resorption of tooth root associated with malignant tumors. *Oral Radiol*. 2000;16:55–65.
82. Malueg LA, Wilcox LR, Johnson W. Examination of external apical root resorption with scanning electron microscopy. *Oral Surg Oral Med Oral Pathol Oral Radiol Endod*. 1996;82:89–93.
83. Heithersay GS. Invasive cervical resorption: an analysis of potential predisposing factors. *Quintessence Int*. 1999;30:83–95.
84. Kaffe I, Tamse A, Littner MM, Schwartz I. A radiographic survey of apical root resorption in pulpless permanent teeth. *Oral Surg Oral Med Oral Pathol*. 1984;58:109–12.
85. Laux M, Abbott PV, Pajarola G, Nair PN. Apical inflammatory root resorption: a correlative radiographic and histological assessment. *Int Endod J*. 2000;33:483–93.
86. Vier FV, Figueiredo JA. Prevalence of different periapical lesions associated with human teeth and their correlation with the presence and extension of apical external root resorption. *Int Endod J*. 2002;35:710–9.
87. Vier FV, Figueiredo JA. Internal apical resorption and its correlation with the type of apical lesion. *Int Endod J*. 2004;37:730–7.
88. Leonardo MR, Rossi MA, Silva LA, Ito IY, Bonifacio KC. EM evaluation of bacterial biofilm and microorganisms on the apical external root surface of human teeth. *J Endod*. 2002;28:815–8.
89. Tsesis I, Fuss Z, Rosenberg E, Taicher S. Radiographic evaluation of the prevalence of root resorption in a Middle Eastern population. *Quintessence Int*. 2008;39:e40–4.
90. Cholia SS, Wilson PH, Makdissi J. Multiple idiopathic external apical root resorption: report of four cases. *Dentomaxillofac Radiol*. 2005;34:240–6.
91. Skolnick IM. Ankylosis of maxillary permanent first molar. *J Am Dent Assoc*. 1980;100:558–60.
92. Lim WH, Kim HJ, Chun YS. Treatment of ankylosed mandibular first permanent molar. *Am J Orthod Dentofacial Orthop*. 2008;133:95–101.
93. Paleczny G. Treatment of the ankylosed mandibular permanent first molar: a case study. *J Can Dent Assoc*. 1991;57:717–9.
94. Baccetti T. Tooth anomalies associated with failure of eruption of first and second permanent molars. *Am J Orthod Dentofacial Orthop*. 2000;118:608–10.
95. Barrett EJ, Kenny DJ. Avulsed permanent teeth: a review of the literature and treatment guidelines. *Endod Dent Traumatol*. 1997;13:153–63.
96. Andreasen JO, Andreasen FM. Textbook and color atlas of traumatic injuries to the teeth. 3rd ed. St. Louis: Mosby; 1994.

Local Anesthesia

3

John M. Nusstein

Abstract

Pulpal anesthesia is a cornerstone in the delivery of endodontic therapy. It affects not only the dentist's ability to provide safe, pain-free treatment, but enhances patient compliance and satisfaction. Administration of local anesthesia is one of the first procedures performed by the dentist. This chapter reviews some of the key local anesthetic components and techniques available to providers in the pursuit of providing pain-free dental treatment. This includes both mandibular and maxillary injections, testing for pulpal anesthesia, new technology and drug formulations, and the supplemental techniques that may make all the difference for the provider and patient.

Guiding Reference

Wallace JA, Michanowicz AE, Mundell RD, Wilson EG. A pilot study of the clinical problem of regionally anesthetizing the pulp of an acutely inflamed mandibular molar. *Oral Surg Oral Med Oral Pathol.* 1985;59(5):517–21.

This study quintessentially showed the difficulty of anesthetizing mandibular teeth when a state of pulpal inflammation was present and tried to begin to explain why patients report pain during treatment even after a successful inferior alveolar nerve block was delivered.

J.M. Nusstein, DDS, MS
Division of Endodontics, The Ohio State University College of Dentistry,
305 W 12th Ave, Columbus, OH 43210, USA
e-mail: nusstein.1@osu.edu

3.1 Introduction

Profound pulpal anesthesia is of obvious importance in endodontic practice and dentistry in general. It benefits not only the patient, for obvious reasons, but also the dentist who does not have to worry about patient reactions or sudden movement during therapy. There are a number of challenges a clinician must overcome in achieving profound local anesthesia. Diagnosis of the status of the pulp and periapical tissues will affect the anesthetic regimens potentially utilized.

Inflammatory changes within the pulp progress as a carious lesion nears the pulp and may cause chronic inflammation to take on an acute exacerbation with an influx of neutrophils and the release of inflammatory mediators such as prostaglandins, interleukins, and proinflammatory neuropeptides, such as substance P, bradykinin, and calcitonin gene-related peptide (CGRP). These mediators, in turn, can sensitize the peripheral nociceptors within the pulp of the affected tooth which may increase pain production and neuronal excitability. These changes may lead to moderate-to-severe pain for the patient and influence the anesthetic strategies needed by the dentist/endodontist to gain profound pulpal anesthesia.

Periapical changes due to infection and chronic inflammation may also impact the anesthesia strategy. The development of an acute apical abscess is the result of pyogenic bacteria from the root canal system spreading to the periapical region and stimulating a strong immune response by the host tissue, with neutrophilic leukocytes dominating the early response. The neutrophils secrete lysosomal enzymes that digest both live and dead cell material. As the neutrophilic response progresses, an accumulation of dead and live neutrophils, disintegrated tissue cells, degraded extracellular matrix, and lysosomal enzymes results in a collection of purulent exudate termed pus. If the involved pathogens are of significant virulence and if the host response is of sufficient intensity, an acute apical abscess may arise. Severe percussion pain or swelling will indicate an acute response within the bone and affect the type of local anesthesia techniques that can be utilized.

Once a pulpal diagnosis is made and a treatment plan developed which includes endodontic therapy, the first step in treatment is local anesthesia. The review of a patient's medical history may determine which local anesthetic can and cannot be utilized. Patients with uncontrolled hypertension or sensitivity to vasoconstrictors may require the use of anesthetics such as 3% mepivacaine or 4% prilocaine. Patients taking nonselective beta-blockers should not receive an injection of an anesthetic containing levonordefrin. A thorough review of the patient's medical history and drug list will dictate the proper anesthetic choice.

3.2 Topical Anesthesia

The use of topical anesthetic prior to injection has been shown to help reduce the pain of needle insertion in certain locations of the mouth. More popular topical anesthetics include 20% benzocaine, EMLA (eutectic mixture of local anesthetics – 2.5% lidocaine and 2.5% prilocaine), and 5% lidocaine (Box 3.1).

Box 3.1. Topical Anesthetics

20 % benzocaine

EMLA (2.5 % lidocaine + 2.5 % prilocaine)

5 % lidocaine

These preparations are available as gel, ointment, or spray form, which allows for easy placement at the site of injection. Utilizing a cotton tip applicator, a small amount of topical anesthetic (approximately 0.2 mL) is placed at the injection site and allowed to penetrate for 60 s. Spray forms may be placed on a cotton tip applicator and applied or sprayed directly to the site of injection.

The effectiveness of a topical anesthetic to reduce the pain of needle insertion has been evaluated in several clinical studies. These have reported no significant difference between 20 % benzocaine compared to a placebo for infiltration injections for the maxillary lateral incisor and that 20 % benzocaine had no effect on needle insertion pain for inferior alveolar nerve block and maxillary posterior buccal infiltration injections. However, results did show that topical anesthetic reduced the amount of needle insertion pain for maxillary anterior infiltrations. Evaluation of the pharmacological and psychological effects of topical anesthesia has shown that, using a placebo application and 20 % benzocaine, subjects who believed that they were receiving an active topical anesthetic anticipated significantly less pain than subjects who thought they were receiving a placebo. Whether injections were preceded by the placebo or the active topical anesthetic did not alter the subjects' reported pain. No significant difference between 20 % benzocaine and a placebo was also found when used prior to a palatal anterior superior alveolar nerve block. Gill and Orr reported that topical anesthetic application for 1 min is effective for maxillary infiltrations, but had no significant difference when compared with a placebo for an inferior alveolar nerve block [1]. The sum of these studies suggests that the mere knowledge of the patient that they are receiving a topical anesthetic could lower the pain experienced during needle insertion. A survey of 3051 pediatric dentists reported that the majority of dentists used topical anesthetic prior to local anesthetic injections in private practice.

Due to the placebo effect, and since most patients and dentists believe that topical anesthetic reduces the pain of the injection, topical anesthetic should be used, if for nothing more, to have the patient feel that the dentist is attempting everything to make a stressful procedure as comfortable as possible.

3.3 Mandibular Anesthesia

When one considers the challenges of local anesthesia in dentistry, mandibular teeth pose the more severe challenge. The inferior alveolar nerve block (IANB) must be delivered accurately (indicated by soft tissue and lip numbness) to have any chance to attain pulpal anesthesia. Missed blocks (lack of lip numbness) occur about 5 % of

the time and should prompt the dentist to re-administer the injection prior to beginning treatment. When one reviews the literature to determine what injection techniques or anesthetic solutions can offer, the dentist needs to be aware of what the definition of “anesthetic success” is utilized. One way used to define anesthetic success for mandibular blocks is the percentage of subjects who achieve two consecutive electric pulp tester (EPT) readings of 80 within 15 min of injection and sustain these readings for at least 60 min. Clinically, this translates into being able to work on the patient no later than 15 min after giving the IANB and having pulpal anesthesia for 1 h. In the available clinical literature, it is reported that, following administration of a successful IANB (lip numbness achieved) using 2% lidocaine with 1:100,000 epinephrine, for the mandibular first molar, success occurs 53% of the time, while for the first premolar it is 61% and for the lateral incisor it is 35%. Anesthetic failure (the percentage of patients who never achieve two consecutive 80 readings with the EPT during 60 min of testing) for the mandibular first molar is 17%, 11% for the first premolar, and 32% for the lateral incisor. Patients may also be subject to anesthesia of slow onset. These patients generally do not achieve pulpal anesthesia until after 16 min following the IANB. This is reported to occur in mandibular teeth approximately 19–27% of the time with some patients (8%) having onset after 30 min. Patients who present a history of anesthesia of slow onset need to be scheduled appropriately earlier than their actual procedure, so that the dentist can give the IANB well before the time it is needed clinically.

3.3.1 Block Technique

The most common injection for obtaining mandibular anesthesia is the inferior alveolar nerve block (Box 3.2).

The inferior alveolar nerve (IAN) and lingual nerve are branches of the posterior division of the trigeminal nerve (V3). The lingual nerve provides sensory innervation to the anterior two-thirds of the tongue as well as the floor of the mouth and the lingual gingiva around the molars. The IAN passes medial to the mandibular ramus and enters the mandibular foramen where it eventually branches at the mental foramen and forms the mental and incisive nerves. The IAN provides sensory innervation to the mandibular posterior teeth and buccal soft tissues. Prior to entering the mandibular foramen, the mylohyoid branch splits off and travels downward and forward along the inferior, medial border of the mandible. This nerve innervates soft tissue on the inferior and anterior mandible. It may also innervate the pulps of mandibular molars.

Box 3.2. Mandibular Anesthetic Blocks

- Inferior alveolar nerve block
- Gow-Gates block
- Vazirani-Akinosi (closed mouth) block

The inferior alveolar nerve block (IANB) is usually administered using a standard aspirating syringe and a 27-gauge 1½-inch needle. The injection site is the soft tissue overlying the medial surface of the ramus, lateral to the pterygomandibular raphe, at a height determined by the coronoid notch on the anterior border of the ramus. With the subject's mouth wide open, the thumb of the noninjecting hand is placed over the pterygomandibular triangle and then pulled laterally until the deepest depression in the anterior border of the ramus was felt. The first or second finger of the noninjecting hand palpates the posterior portion of the ramus, finding a slight depression. The line between the thumb and the finger establishes the vertical height of the injection site. The direction of the needle insertion is from the contralateral mandibular premolars and is directed parallel to the occlusal plane [2]. The needle is advanced until the bone is sounded, then retracted 1 mm before aspiration and injection into the pterygomandibular space.

The injection rate should be slow; research has shown that a slower injection rate is more comfortable for the patient (1 cartridge over 60 s) and may lead to more successful blocks. The standard inferior alveolar nerve block will anesthetize the inferior alveolar nerve, mental nerve, and usually the lingual nerve as well. This would include pulpal anesthesia of mandibular molars, premolars, and incisors on the injected side, along with the associated supporting bony and periodontal structures to the midline. It would also anesthetize the buccal and labial soft tissues and chin to the midline. A long buccal injection can be given if soft tissue anesthesia is required of the buccal gingival tissues next to the molar teeth for rubber dam clamp placement. Onset of pulpal anesthesia will range from 5 to 19 min and is slower than the onset of lip numbness (4–6 min).

Other injection techniques have been developed and advocated in attempting to block the inferior alveolar nerve. The Gow-Gates technique [3] has been reported to have a higher success rate than a conventional IANB, but other well-controlled clinical studies have not been able to confirm this. The Vazirani-Akinosi technique (closed mouth) [4, 5] also has not been shown to be superior in terms of achieving profound anesthesia compared to the conventional IANB technique. Therefore, replacing the conventional IANB injection with these techniques will likely not improve success in attaining pulpal anesthesia in mandibular teeth.

Inaccuracy of the IANB injection has been cited as a contributor to failed mandibular pulpal anesthesia. Hannan et al. [6] used medical ultrasound to guide an anesthetic needle to its target site for the IANB. This group reported that accurate injections could be attained by this method, but it did not result in more successful pulpal anesthesia. Simon et al. [7] studied the anesthetic effectiveness of an IANB after using a peripheral nerve stimulator to locate the inferior alveolar nerve at the injection site. The technique was no more successful than the conventional injection technique. Therefore, the accuracy of the injection technique (needle placement) is not the primary reason for anesthetic failure with the IANB. Needle deflection as related to the needle bevel direction (toward or away from the mandibular ramus) has also been shown not to affect the anesthetic success rate of the IANB.

Accessory nerves have also been implicated as a potential reason for the failure of the IANB. The incisive nerve block at the mental foramen has been shown to

improve anesthetic success of the IANB in first molars and premolars, but the success rate was not as good as other supplemental anesthetic techniques (to be discussed later). The mylohyoid nerve is the accessory nerve most often implicated as the cause for mandibular anesthesia failure. However, Clark and coauthors [8], when combining the IANB with a mylohyoid injection after locating the mylohyoid nerve with a peripheral nerve stimulator, found no significant improvement in mandibular anesthesia when the mylohyoid injection was added.

3.3.2 Local Anesthetic Compounds for Mandibular Anesthesia

Lidocaine with epinephrine is still considered the standard to compare all other local anesthetics too. The emergence of 4% articaine has decreased the use of lidocaine in many countries. When one looks at the literature, no local anesthetic has significantly improved the success rate of the IANB. Research comparing various local anesthetic agents such as 3% mepivacaine plain (Carbocaine, Polocaine, Scandonest), 4% prilocaine (Citanest Plain), 4% prilocaine with 1:200,000 epinephrine (Citanest Forte), 2% mepivacaine with 1:20,000 levonordefrin (Carbocaine with Neo-Cobefrin), 4% articaine with 1:100,000 epinephrine (Septocaine) to 2% lidocaine with 1:100,000 epinephrine for the IANB in patients with normal pulps showed that there was no difference in success rates. Therefore, changing local anesthetic agents may not be of benefit for endodontic procedures. When confronted with the increased difficulty of achieving anesthesia due to a diagnosis of symptomatic irreversible pulpitis, clinical studies have also failed to show any superiority of 3% mepivacaine or 4% articaine with 1:100,000 epinephrine over 2% lidocaine with 1:100,000 epinephrine for the IANB. The use of a buffering agent, such as sodium bicarbonate to increase the pH of the anesthetic solution, has also not been found to improve success rates of pulpal anesthesia clinically [9].

Increasing the volume of local anesthetic delivered during the IANB, therefore increasing the amount of anesthetic in the pterygomandibular space and potentially exposing the nerve to more anesthetic, has also been found not to increase the incidence of pulpal anesthesia in asymptomatic patients or those diagnosed with symptomatic irreversible pulpitis. Increasing the concentration of epinephrine (1:50,000) in hopes of keeping the anesthetic agent at the injection site longer showed no advantage in the IANB.

The duration of pulpal anesthesia utilizing 1.8 mL 2% lidocaine with 1:100,000 epinephrine or 0.5% bupivacaine with 1:200,000 epinephrine has been reported to be 2.5 h and 3–4 h, respectively. Therefore, adequate time is available for the dentist to complete endodontic therapy. The actual duration of pulpal anesthesia for anesthetics has not been studied.

The choice of local anesthetic may therefore be more a preference of the provider, medical condition of the patient, or even the desired duration of anesthesia. A volume of 3.6 mL (two cartridges) may improve achieving a successful IANB block (lip numbness), but may not improve the success rate of pulpal anesthesia.

3.4 Maxillary Anesthesia

The supraperiosteal (infiltration) injection is the most commonly used local anesthetic technique for maxillary pulpal anesthesia. Ninety-five percent (95 %) of maxillary infiltration injections (supraperiosteal or field blocks) produce successful anesthesia (Box 3.3).

Clinical studies have evaluated the success of maxillary infiltrations using the electric pulp tester. Using a volume of 1.8 mL or less, pulpal anesthetic success (obtaining maximum output with an electric pulp tester) ranged from 87 to 100 %. The duration of pulpal anesthesia with a lidocaine solution varied from 31 to 100 min, with the majority of studies showing duration times of less than 60 min. This is an important point to remember when the endodontic procedure takes longer than approximately 45 min. Anesthesia will diminish, and re-injection may be necessary to ensure patient's continued comfort.

3.4.1 Maxillary Technique

For molar endodontic procedures, the maxillary infiltration technique may be selected. The maxillary division (V2) of the trigeminal nerve branches off in four regions, including the pterygopalatine fossa. In the pterygopalatine fossa, the maxillary division branches off into the zygomatic nerve, the pterygopalatine nerves, and the posterior superior alveolar (PSA) nerve. The PSA nerve commonly has two branches: The second branch of the PSA provides sensory innervation to the alveoli, periodontal ligaments, and pulpal tissues of the maxillary third, second, and first molars (with the exception in 20 % of patients of the MB root of the first molar). The maxillary division also branches off into the infraorbital canal. Within the infraorbital canal, the maxillary division gives off the middle and anterior superior alveolar (MSA and ASA) nerves. The MSA nerve provides sensory innervation to the two maxillary premolars, and perhaps, to the MB root of the first molar as well as the periodontal tissues, buccal soft tissue, and bone in the premolar region. These are the nerves the dentist is most concerned about when treating a maxillary posterior tooth.

The basic infiltration technique taught in dental school is one of the easier injections to administer. Using a 27-gauge short needle, the lip/cheek is pulled outward to make the vestibular tissue taut. The needle is inserted at the height of the mucobuccal fold parallel to the tooth being anesthetized, with the target being the apical

Box 3.3. Maxillary Anesthetic Injections

- Infiltration injection
- Posterior superior alveolar (PSA) block
- Division V2 block

area of the tooth. The direction of the needle bevel may not be important, since no study has looked at its effect on anesthesia, and the anesthetic solution will dissipate in all directions from the needle tip. Following aspiration, injection speed should be slow – approximately 1 min for a cartridge to reduce the potential pain on solution deposition. Onset time for pulpal anesthesia ranges from 2 to 5 min in premolars and molars.

Anesthesia of the palatal tissues may also be needed. Utilization of this injection will help reduce the pain of rubber dam clamp placement in all cases, but especially for teeth that have lost structure in which the clamp may impinge on the palatal gingiva. The use of either a topical anesthetic and/or pressure anesthesia may help reduce the pain of needle insertion on the palate. Pressure anesthesia can be obtained by placing a blunt instrument handle at the target site for approximately 30 s and maintaining that pressure as the needle is inserted immediately adjacent to the pressure site. The insertion site should be adjacent to the tooth being treated and approximately 10 mm from the free gingival margin. The needle bevel should be oriented toward the bone. A small amount of anesthetic (0.3–0.5 mL) is then deposited slowly until blanching of the tissues is identified.

Alternate techniques for posterior maxillary anesthesia include the PSA and second division nerve blocks. These techniques can be very successful, but have potential risks including hematoma, pain, and difficulty in technique.

The posterior superior alveolar (PSA) nerve block anesthetizes the third and second molars and about 80 % of first molars. Often, an additional mesial infiltration injection may be necessary to anesthetize the first molar. The injection targets the PSA nerve and is given superiorly and medially to the maxillary second molar. The maxillary second division nerve block can be attained using two intraoral techniques. The first technique, the greater palatine approach, involves negotiating the greater palatine canal to the pterygopalatine fossa. The second technique, the high tuberosity approach, places the needle around the posterior maxilla until the needle enters the pterygopalatine fossa. Success rates have been reported as high as 95–100 % for second molars using either approach. However, the challenge in tracking the greater palatine canal and the pain associated with this approach may limit the clinical value of this technique.

3.4.2 Local Anesthetic Compounds for Maxillary Anesthesia

The use of a 2 % lidocaine solution with 1:100,000 epinephrine has resulted in a good rate of pulpal anesthesia success. In reviewing numerous clinical studies, an overall success rate of 87 % is reported for molars.

Alternate anesthetic solutions have also been clinically evaluated. The use of plain solutions such as 3 % mepivacaine and 4 % prilocaine has resulted in relatively good success rates (70–73 %), but greatly diminished duration of anesthesia – 25 min. This reduced duration would preclude their use in endodontic therapy unless the patient's medical condition warranted their use. Repeated injections of these solutions would then be necessary. Solutions of 4 % articaine with 1:100,000

epinephrine, 2% mepivacaine with 1:20,000 levonordefrin, and 4% prilocaine with 1:200,000 epinephrine achieved the same level of anesthetic success in maxillary first molars as 2% lidocaine with 1:100,000 epinephrine. Therefore, the use of these anesthetics is of no clinical benefit. Research on the use of 0.5% bupivacaine with 1:200,000 epinephrine in maxillary first molars revealed a delayed onset time (almost 8 min) and a lower success rate (64 versus 82% for lidocaine). Anesthetic duration was not extended significantly with the use of bupivacaine. The use of 2% lidocaine with 1:50,000 epinephrine has also been shown to increase the duration of anesthesia versus a 1:100,000 epinephrine solution, but it did not extend it beyond 60 min. Success rates were the same. No research, published to date, has reported on the effect of buffering on achieving pulpal anesthesia in maxillary molars.

In terms of the volume to utilize, Mikesell et al. [10] compared the degree of anesthesia obtained with 1.8 and 3.6 mL of 2% lidocaine with 1:100,000 epinephrine in maxillary infiltrations (first molar). The success rates (defined as two consecutive 80 readings with the electric pulp tester) ranged from 97 to 100% for the two anesthetic volumes. There was no statistically significant difference between the two anesthetic volumes. However, the 3.6 mL volume of lidocaine provided a statistically longer duration of pulpal anesthesia than the 1.8 mL volume for the lateral incisor, first premolar, and first molar.

No current local dental anesthetic preparation has been found to be superior in attaining pulpal anesthesia in maxillary posterior teeth. The choice of anesthetic for a maxillary infiltration injection may be dictated by the patient's health history, desired anesthetic duration, or provider preference.

3.5 Determining Pulpal Anesthesia Prior to Initiating Treatment

Determining whether adequate local anesthesia has been achieved prior to treatment is important (Box 3.4).

Mandibular anesthesia via the inferior alveolar nerve block (IANB) has traditionally been confirmed by asking the patient if their lip feels numb, probing or sticking the gingiva around the mandibular tooth to be treated, or simply starting treatment and waiting for a patient response. These techniques are not very effective in determining if pulpal anesthesia has been achieved. For maxillary teeth, lip and/or cheek numbness may be assessed. Objective tests are available that can be utilized to better assess the level of pulpal anesthesia for all teeth. The use of an electric pulp tester (EPT) and/or the application of a cold refrigerant have been shown

Box 3.4. Determining Successful Pulpal Anesthesia

- Thermal testing – cold
- Electric pulp testing – maximum reading

to accurately determine pulpal anesthesia in teeth with a normal pulp prior to treatment. If the patient responds negatively to the stimulus (cold or electric current), then pulpal anesthesia has been attained and the patient should not experience pain during treatment. However, in teeth diagnosed with a symptomatic irreversible pulpitis, a failure to respond to the stimulus may not necessarily guarantee pulpal anesthesia [11]. The patient may still report pain with treatment. Of course, teeth with necrotic pulp chambers but whose root canals contain vital tissue may not be tested using the above means. In these cases, testing for pulpal anesthesia of the neighboring teeth may give the clinician an indication of the anesthetic status of the treatment tooth.

3.6 Supplemental Anesthetic Techniques

Patients in pain due to a tooth diagnosed with symptomatic irreversible pulpitis frequently have difficulties attaining pulpal anesthesia. One theory to explain this is that the inflamed tissue has a lowered pH, which reduces the amount of the base form of anesthetic needed to penetrate the nerve sheath and membrane. Therefore, there is less ionized form of the anesthetic within the nerve to produce anesthesia. Obviously, this theory may only explain the local effects of inflammation on the nerve and not explain why an IANB injection is less successful when given at a distance from the area of inflammation (the “hot” tooth). Another theory states that the nerves arising from inflamed tissue have altered resting potentials and reduced thresholds of excitability. Electrophysiological research indicated that local anesthetic agents were not able to prevent the transmission of nerve impulses due to the lowered nerve excitability thresholds of inflamed nerves. Other theories have considered the presence of anesthetic-resistant sodium channels and upregulation of the so-called tetrodotoxin-resistant sodium channels in pulps diagnosed with irreversible pulpitis.

The failure of the traditional IANB in asymptomatic and symptomatic patients requires that a clinician have strategies to attain good pulpal anesthesia. This is very important when a patient complains of pain too severe for the clinician to proceed with endodontic treatment, as is often the case of patients with “hot” (symptomatic irreversible pulpitis) teeth. There are several supplemental anesthetic techniques (Box 3.5) available to help the dentist. It should be reiterated that these supplemental techniques are used best after attaining a clinically successful inferior alveolar nerve block (lip numbness).

Box 3.5. Supplemental Injection Techniques

- Mandibular buccal infiltration with articaine
- Intraligamentary injection (PDL)
- Intraosseous injection (IO)
- Intrapulpal injection

3.7 Preemptive Strategies to Improve Success of the IANB Injection

Recent clinical studies have looked at the use of various oral medications prior to treatment of a patient with a tooth diagnosed with symptomatic irreversible pulpitis attempting to improve the success rate of the IANB injection. The use of acetaminophen and ibuprofen (various strengths), acetaminophen/ibuprofen combinations, methylprednisolone, ketorolac and triazolam all failed to improve the rate of success of the IANB injection in these patients. However, Stanley et al. [12] did report on an improvement in block success when nitrous oxide was used in a concentration of 30–50%.

3.8 Mandibular Buccal Infiltration Injection with Articaine

Research has looked at the use of a mandibular buccal infiltration injection of 4% articaine with 1:100,000 epinephrine as a supplemental injection to increase the success of the IANB injection (Box 3.6). In asymptomatic patients, the use of the articaine solution was found to be superior to a lidocaine solution (88% versus 71%, respectively). However, when the buccal infiltration injection is used as a supplement to the IANB in patients diagnosed with irreversible pulpitis, success was reported as only 58%. This result was much less than that attained with the IO and PDL injections.

Deposition of one cartridge of 4% articaine solution in the buccal vestibule next to a mandibular posterior tooth is a simple adjunct technique. Research has shown that only articaine is able to provide this added anesthesia. The use of other

Box 3.6. Mandibular Buccal Infiltration with Articaine*

Technique

- Utilize 27-gauge short needle and 4% articaine solution
- Insert needle directly next to the tooth to be anesthetized in the buccal vestibule
- Place needle to approximate depth or root apex
- Inject one cartridge of articaine solution over 1–2 min
- (Optional) For anterior teeth – inject additional one cartridge of articaine solution, lingual to the treatment tooth
- Wait for a minimum of 5 min before beginning treatment
- Test tooth for anesthesia
- Begin treatment

*Note: If a technique is being used as a supplemental injection, do not give until successful IANB injection is confirmed (lip/soft tissue numbness).

anesthetics (lidocaine or prilocaine) and/or different concentrations of anesthetics (2 or 4 %) has failed to match the success of articaine. The use of a 4 % articaine solution with either 1:100,000 or 1:200,000 epinephrine achieves the same rate of success, with the only difference being the duration of anesthesia (less for less epinephrine). For mandibular anterior teeth, the same level of success may be achieved when the injections are given primarily without an IANB injection. The addition of a second injection of articaine on the lingual of an anterior tooth will increase the success rate. However, duration of these primary injections is only approximately 45 min.

3.9 Intraligamentary (PDL) Injection

The PDL supplemental injection is still one of the most widely taught and used supplemental anesthetic techniques (Box 3.7). The success of supplemental PDL injections in helping achieve anesthesia for endodontic procedures has been reported to be 50–96 %. The key to giving a successful PDL injection remains the attainment of back pressure during the injection.

PDL injections are usually given utilizing either a standard dental anesthetic syringe or a high-pressure syringe. A 30-gauge ultrashort needle or 27- or 25-gauge short needle is utilized. The gauge of the needle does not influence the effectiveness. The needle is inserted into the mesial gingival sulcus with the bevel of the needle facing away from the tooth. Maximum penetration within the sulcus is required. Utilizing a standard syringe, slow, but heavy pressure is applied to the syringe plunger for approximately 20 s. With a pressure syringe, the trigger is slowly squeezed until it clicks one or two times. As stated earlier, back pressure must be felt as the injection is given. Failure to get back pressure will most likely lead to

Box 3.7. Intraligamentary Injection

Technique

- Prepare syringe with needle and anesthetic
- Determine need for injection
- Place needle in mesial gingival sulcus
 - Bevel facing bone
- Apply pressure to needle for maximum soft-tissue penetration
- Slow, moderate-to-heavy pressure on syringe
 - Approximately 20 s
 - Two clicks with pressure syringe
 - 0.7 mL with CCLAD device
- Repeat injection in distal sulcus
- Test tooth for anesthesia
- Begin treatment

failure. The same injection is then given in the distal sulcus of the tooth. Approximately 0.2 mL of anesthetic is expressed in both locations.

The development of computer-controlled local anesthetic delivery systems (CCLAD for short), the Wand/CompuDent and Single Tooth Anesthesia System (both Milestone Scientific, Livingston, NJ) have been found to also be able to deliver a PDL injection. These systems are able to deliver 1.4 mL of anesthetic over the course of the two injections. The duration of anesthesia with the CompuDent/Wand system is almost three times what is afforded with a standard/pressure syringe (first molar averaged 31–34 versus 10 min). Currently, no research on the STA device is available for review.

The onset of anesthesia utilizing the PDL injection is immediate. The dentist should not wait to begin treatment. After delivering the injection, the tooth should be pulp-tested and, if no response is recorded, treatment should begin. A repeated set of injections may be necessary if the first set does not help attain adequate pulpal anesthesia.

The intraligamentary injection forces local anesthetic solution through the cribiform plate and into the cancellous bone around the tooth. In a sense, it is an intraosseous injection. The duration of anesthesia is dependent on the volume and type of anesthetic utilized. Anesthetic solutions not containing any vasoconstrictor (3% mepivacaine) will have a shorter duration of action compared to those anesthetics containing epinephrine. Success of anesthesia is also dependent on the presence of a vasoconstrictor with plain solutions showing less effectiveness.

Patients should be advised of potential post-treatment, moderate pain of the tooth that was injected. This is usually due to the trauma to the soft tissue where the needle was inserted and not the pressure of the injection.

3.10 Intraosseous Injection (IO)

The use of the intraosseous injection (IO) allows the dentist to deliver local anesthetic solutions directly into the cancellous bone surrounding the affected tooth (Box 3.8). There are several intraosseous systems available on the market including the Stabident system (Fairfax Dental, Wimbledon, UK), X-Tip system (Dentsply Maillefer, Tulsa, OK), and QuickSleeper made by Dental Hi Tec (Cholet, France). The Stabident system consists of a 27-gauge, beveled wire driven by a slow-speed handpiece which perforates the cortical bone. Anesthetic solution is then delivered into the cancellous bone with a 27-gauge ultrashort needle through the perforation, using a standard anesthetic syringe. The X-Tip system consists of a two-part perforator/guide sleeve component, which is also driven by a slow-speed handpiece. The perforator leads the guide sleeve through the cortical bone and then is separated from it and removed. This leaves the guide sleeve in place and allows for a 27-gauge needle to be inserted to inject the anesthetic solution. The guide sleeve is removed with a hemostat when treatment is complete. The QuickSleeper is an electronic handpiece that holds and drives a perforating needle as well as an anesthetic cartridge. Once perforation is attained, the handpiece uses an electric injection system to deliver the local anesthetic through the perforation.

Box 3.8. Intraosseous Injection

Technique

- Prepare syringe with needle and anesthetic
- Determine need for injection
- Advise patient of the technique's side effects (transient increased heart rate)
- Select perforation site (generally distal to tooth, if accessible)
 - In attached, healthy gingiva
 - Above mucogingival line
 - Exception: X-Tip and QuickSleeper system
 - Equidistant from approximating roots
- Anesthetize perforation area (if needed)
 - 0.5 mL anesthetic
- Place perforator and align perpendicular to bone surface
- Perforate cortical bone over a 5–7 s time period
 - Pecking motion until breakthrough is felt
- Immediately place needle in perforation and/or inject anesthetic
 - 0.9–1.8 mL anesthetic over 1 min
- Retest tooth for anesthesia
- Begin treatment immediately

One of the benefits of the IO injection is the immediate onset of anesthesia (Box 3.8). The injection is recommended to be given distal to the tooth to be anesthetized for best success. The exceptions to this rule are maxillary and mandibular second molars, where a mesial site of injection is appropriate. The perforation site for the IO injection should be equidistant between the teeth and the *attached* gingiva. This allows for the perforation to be made through a minimal thickness of tissue and cortical bone, and prevents damage to the roots of the teeth. Perforation in attached tissue also allows for easier location of the perforation site with the Stabident system. The X-Tip and QuickSleeper could be used in a more apical area below the mucogingival junction if needed, since there is no difficulty in locating the perforation hole. The apical location of the injection would be advisable when the patient has no attached tissue around the affected tooth, there is a lack of interproximal space between adjacent roots, or the Stabident IO injection did not achieve adequate anesthesia.

Injection of the anesthetic solution should be slow – approximately 1 min for 1.8 mL of solution. The volume of solution injected can range from 0.9 to 1.8 mL. Most clinical research has been conducted with these volumes. Research on the supplemental IO injection for asymptomatic patients and those diagnosed with irreversible pulpitis has shown good results. Rates have ranged from 75 to 93% for mandibular first molars. No specific anesthetic has been found to be superior when used with the IO injection. However, duration of effect has been shown to be dependent on the presence of a vasoconstrictor (like the PDL injection). The Stabident

and X-Tip systems show equal effectiveness in terms of anesthesia. No published research is currently available on the effectiveness of the QuickSleeper system. Failure of the IO injection is usually due to back pressure or backflow of anesthetic out of the perforation site. This backflow is usually indicative of an incomplete perforation or blockage of the guide sleeve. The duration of anesthesia for a supplemental IO injection in patients with irreversible pulpitis has been reported to last the entire debridement appointment of approximately 45 min. The duration will be shorter with the 3% mepivacaine solution.

One of the concerns when utilizing the IO injection is the reported transient heart rate increase with both the Stabident and X-Tip systems (and most likely the QuickSleeper system) when injecting epinephrine-containing and levonordephrin-containing anesthetic solutions. Replogle et al. [13] reported that 67% of subjects had an increase in heart rate as measured on an electrocardiograph when 1.8 mL of 2% lidocaine with 1:100,000 epinephrine was utilized. The increase in the heart rate reported ranged from 12 to 32 beats per minute. The use of 3% mepivacaine has been reported not to cause any significant increase in heart rate [13] and may be an excellent alternative when a patient's medical history or drug therapies contraindicate the use of epinephrine or levonordephrin. Prior to the injection of a vasoconstrictor-containing anesthetic, the patient should be warned of the side effect and reassured that the increase in heart rate is transient (2–3 min) and is not dangerous.

3.11 Intrapulpal Injection

In approximately 5–10% of mandibular teeth diagnosed with irreversible pulpitis, supplemental injections (PDL and IO) do not produce adequate anesthesia, even when repeated, to enter the pulp chamber painlessly. This is a prime indication that an intrapulpal injection may be necessary (Box 3.9).

Box 3.9. Intrapulpal Injection

Technique

- Pulpal exposure
- Select appropriate size needle to fit snugly into perforation or canal orifice
- Advise patient of side effects of technique (severe, short-term pain)
- Place needle into perforation or canal orifice with firm pressure to achieve maximum penetration
- Inject anesthetic slowly under back pressure (20–30 s)
- Have patient indicate relief of pain
- Resume coronal pulp tissue removal or removal of tissue from canal (anesthetic duration is approximately 10 min)
- Repeat injection in individual canals as needed

The intrapulpal injection works very well when it is given under back pressure. Onset of anesthesia is immediate. Various techniques have been advocated in giving the injection; however, the key factor is giving the injection under strong back pressure. Simply placing local anesthetic solution in the pulp chamber will not achieve adequate pulpal anesthesia.

A disadvantage of the intrapulpal injection is its short duration of action (approximately 15–20 min). Once anesthesia is achieved, the practitioner must work quickly to remove all the tissue from the pulp chamber and the canals. The intrapulpal injection also requires that the pulp tissue be exposed to permit the injection to be given. Achieving a pulpal exposure could be very painful to the patient, since the pain of treatment may begin when the dentin is exposed. Finally, the injection itself can be very painful for the patient. The patient should be warned to expect moderate-to-severe pain during the initial phase of the injection.

To give the injection, the pulp of the tooth must be exposed. With pinpoint exposures, a 30-gauge needle can be utilized. A large-gauge needle may be needed if the exposure is larger in diameter. The needle is placed on a standard syringe containing any type of local anesthetic. The patient is warned about the pending occurrence of the injection. The needle is then placed into the exposure hole and driven into the pulp chamber. Anesthetic is immediately delivered under strong back pressure. The failure to achieve back pressure with the injection may result in a failure to attain any more useful pulpal anesthesia. If the pulp exposure is larger and the pulp canal orifices can be visualized or probed, the 30-gauge needle is driven into the canal as deeply as it can go while anesthetic is being delivered. Ask the patient to signal if and when the pain of the injection subsides. This can be used as an indication that some degree of pulpal anesthesia has been attained in that canal. Removal of the tissue in the injected canal should begin immediately. The duration of the injection is as little as 10 min. This injection may be required for all of the canals.

3.12 Checklist for Anesthesia in Endodontics

- Check allergies, premedications to determine appropriate local anesthetic selection.
- Select appropriate injection technique for clinical diagnosis and location.
- Test for anesthetic success prior to beginning treatment.
- If anesthesia is insufficient, use supplementary technique to enhance anesthesia.
- Retest for adequate pulpal anesthesia prior to beginning treatment.
- If insufficient anesthesia, repeat previous supplemental technique or select a different one.
- Once adequate anesthesia is achieved, begin treatment.

References

1. Gill CJ, Orr DL. A double-blind crossover comparison of topical anesthetics. *J Am Dent Assoc.* 1979;98(2):213–4.
2. Jorgensen NB, Hayden Jr J. *Local and general anesthesia in dentistry.* 2nd ed. Philadelphia: Lea & Febiger; 1967.
3. Gow-Gates GA. Mandibular conduction anesthesia: a new technique using extraoral landmarks. *Oral Surg Oral Med Oral Pathol.* 1973;36(3):321–8.
4. Vazirani S. Closed mouth mandibular nerve block: a new technique. *Dent Dig.* 1960;66:10–3.
5. Akinosi J. A new approach to the mandibular block. *Br J Oral Surg.* 1977;15:83–7.
6. Hannan L, Reader A, Nist R, et al. The use of ultrasound for guiding needle placement for inferior alveolar nerve blocks. *Oral Surg Oral Med Oral Pathol Oral Radiol Endod.* 1999;87(6):658–65.
7. Simon F, Reader A, Drum M, Nusstein J, Beck M. A prospective, randomized single-blind study of the anesthetic efficacy of the inferior alveolar nerve block administered with a peripheral nerve stimulator. *J Endod.* 2010;36(3):429–33.
8. Clark S, Reader A, Beck M, Meyers WJ. Anesthetic efficacy of the mylohyoid nerve block and combination inferior alveolar nerve block/mylohyoid nerve block. *Oral Surg Oral Med Oral Pathol Oral Radiol Endod.* 1999;87(5):557–63.
9. Whitcomb M, Drum M, Reader A, Nusstein J, Beck M. A prospective, randomized, double-blind study of the anesthetic efficacy of sodium bicarbonate buffered 2% lidocaine with 1:100,000 epinephrine in inferior alveolar nerve blocks. *Anesth Prog.* 2010;57(2):59–66.
10. Mikesell A, Drum M, Reader A, Beck M. Anesthetic efficacy of 1.8 mL and 3.6 mL of 2% lidocaine with 1:100,000 epinephrine for maxillary infiltrations. *J Endod.* 2008;34(2):121–5.
11. Dreven LJ, Reader A, Beck M, et al. An evaluation of an electric pulp tester as a measure of analgesia in human vital teeth. *J Endod.* 1987;13(5):233–8.
12. Stanley W, Drum M, Nusstein J, Reader A, Beck M. Effect of nitrous oxide on the efficacy of the inferior alveolar nerve block in patients with symptomatic irreversible pulpitis. *J Endod.* 2012;38(5):565–9.
13. Replogle K, Reader A, Nist R, Beck M, Weaver J, Meyers WJ. Cardiovascular effects of intraosseous injections of 2% lidocaine with 1:100,000 epinephrine and 3% mepivacaine. *J Am Dent Assoc.* 1999;130(5):649–57.

Vital Pulp Therapy for Permanent Molars

4

Lars Bjørndal

Abstract

Guidelines for vital molar therapy are presented based on best available evidence. Often the cause for vital intervention is due to caries, but seldom the depth of the carious lesion is mentioned in literature, which may hamper the evaluation of prognosis following treatment. Moreover, the lack of devices for monitoring objectively the degree of pulp inflammation makes the topic a clinical challenge where proper tooth selection is important. In this chapter, the deep and extremely deep caries lesion is defined and linked to specific treatment protocols, which include both direct pulp as well as indirect pulp capping procedures. Particularly, a classification of the pulp capping procedure is described, which relates to two specific scenarios. In Class I the need for pulp capping arises by accident, while in Class II the capping procedure is expected and the set-up for the vital pulp therapy includes the use of the operating microscope.

Guiding Reference

Bjørndal L, Thylstrup A. A practice-based study on stepwise excavation of deep carious lesions in permanent teeth: a 1-year follow-up study. *Comm Dent Oral Epidemiol.* 1998;26:122–8.

This practice-based study followed teeth with deep caries, in which clinicians suspected a pulp exposure if excavated to the fullest extent. The high success rate of teeth surviving the final treatment without pulp exposure after 1 year of observation

L. Bjørndal, PhD

Section of Cariology and Endodontics, Department of Odontology, Faculty of Health and Medical Sciences, University of Copenhagen, Nørre Allé 20, 2200 Copenhagen, Denmark
e-mail: labj@sund.ku.dk

shows that it was possible for dentists in general practice to administer and manage the treatment of deep carious lesions, a process which may prolong tooth survival compared with conventional endodontic techniques.

4.1 Introduction

The management of deep caries is a daily issue in endodontic practice. For caries in the pulpal quarter of the dentin, high-level evidence data have shown that a stepwise excavation approach led to a significant decrease in the number of pulp exposures as opposed to complete excavation.

Before performing vital pulp therapy in a molar, clinicians will have to answer two questions: (A) How invasive a treatment needs to be in fulfilling the aims of preserving and maintaining the pulp tissue in a healthy clinical condition, and (B) whether the chosen modality is a permanent or temporary treatment solution. Both topics depend upon the cause and time of the injury: is the pulp exposed as a result of trauma or through caries? What is the aim of performing vital pulp therapy and when could a pulp exposure particularly in carious teeth be avoided, by changing toward an indirect pulp therapy approach?

The controversy about caries and the pulp goes back more than a century [1, 2], and represents a problem of deciding the right treatment in dentistry. G.V. Black wrote in his textbook: "...it will often be a question whether or not the pulp will be exposed when all decayed dentine overlaying the pulp is removed...and It is better to expose the pulp of a tooth than to leave it covered only with softened dentine" [1], whereas Sir John Tomes wrote decades before [2]: "....."It is better that a layer of discolored dentine should be allowed to remain for the protection of the pulp rather than run the risk of sacrificing the tooth."

Even today the same deep caries scenario may be interpreted and treated differently by clinicians [3–5]. The caries and pulp dilemma is partly due to the lack of a noninvasive diagnostic device for monitoring degrees of inflammation in the pulp [6], as well as a low level of scientific evidence addressing the best treatment [7–9]. Finally, the exact definition of deep caries is unclear, when outcomes of vital pulp therapy are reported. In this chapter we define radiographically deep caries as being within the inner quarter of the pulp and extremely deep if penetrating the entire thickness of the dentin (Fig. 4.1).

A pulp exposure is defined relatively broadly being the result of a pathological change in the hard tissue of a tooth caused by caries, a mechanical factor, or trauma [10]. Here, a classification of pulp capping procedures is introduced separating two scenarios: *direct pulp capping Class I* (pulp exposure has been made accidentally) and *direct pulp capping Class II* (pulp exposure is expected, as part of caries excavation and while using a microscope). This chapter aims to align updated treatment guidelines on best clinical evidence for vital pulp therapy in molars including the indirect pulp therapy approach.

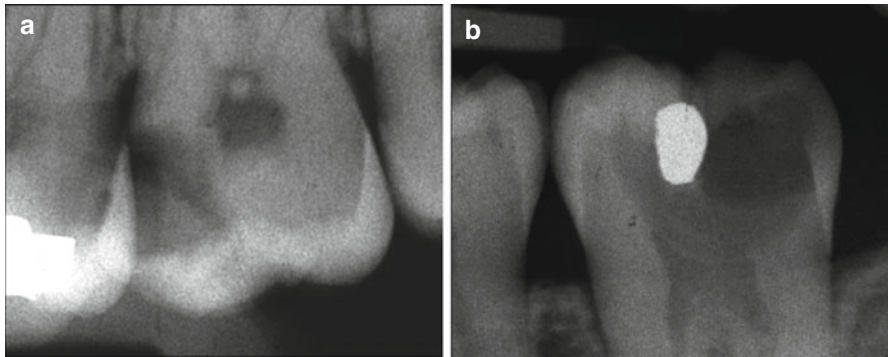


Fig. 4.1 The radiographic presentations are shown of a deep caries lesion versus an extremely deep lesion. (a) The deep lesion involves the pulpal quarter with a radiodense zone separating the translucent zone from the pulp. (b) The extremely deep lesion defines a penetration that involves the entire primary/secondary dentin, either with no radiodense zone separating the demineralized dentin from the pulp or with a radiodense zone located within the pulp chamber indicative of tertiary dentin

4.2 The Benefit of Having a Vital Pulp

4.2.1 Apexogenesis

In injured teeth with incomplete root formation, it is essential to keep a vital pulp for the final formation and completion of the root complex, described as apexogenesis. Much focus has been given in the past to this topic [11], because the tooth has a better prognosis, if the roots are fully matured. Some of the problems associated with incomplete root formation of teeth after pulpal necrosis are briefly listed in Box 4.1 but also discussed in Chap. 7 of this book.

Box 4.1. Vital Pulp Therapy Aims at Apexogenesis for the Prevention of the Following

- An open apex (a challenge to create a stop and establish a good seal)
- Thin dentinal walls (more prone to fracture)
- The incomplete apical development (in general making instrumentation and sealing more difficult)
- Root fracture

4.2.2 Tertiary Dentinogenesis

The stimulation of tertiary dentinogenesis is a main objective of the vital pulp therapy. The classification and definition of tertiary dentin has in the past been described by many synonyms [12, 13]; here, it is presented in the context of dentinogenesis in general (Box 4.2). Tertiary dentin defines new hard tissue produced in relation to an external injury [14]. The subdivision of tertiary dentin into reactionary dentinogenesis and reparative dentinogenesis introduces a biological platform with more emphasis at the cellular origin [15, 16], as well as causes for the upregulation of the aged odontoblast secretion [17–19]. The reactionary dentin can be interpreted as the elevated growth of dentinogenesis, related to early caries lesions [20], and the odontoblast cells are stimulated by dentin matrix proteins released during caries demineralization [21, 22]. These upregulated primary odontoblast cells [18] are involved directly, but also a mixture with new beginners of secondary odontoblast-like cells can be observed in natural caries development [23]. In case of a pulp exposure, a complete new dentin formation leads to the reestablishment of a dentinal bridge formation, defined as reparative dentinogenesis (Box 4.2). Initially, it is composed by a layer of atubular mineralized matrix, described as fibrodentin [14], followed by a tubular dentin formation, presumably laid down by new secondary odontoblast-like cells.

A significant portion of the dental literature has been dealing with the study of a newly formed hard tissue barrier and the status of the pulp after vital pulp therapy. A simple parameter for examining new pulp-protective agents has been to confirm whether or not tertiary dentin is present following pulp therapy. A recent systematic review has argued [24] that these microscopic analyses of histological sections on newly formed hard tissue may be considered a surrogate endpoint, which is difficult

Box 4.2. Classification of Dentinogenesis

Primary dentinogenesis: dentin produced before the tooth erupts

Secondary dentinogenesis: dentin physiologically produced after the tooth has erupted, eventually reducing the size of the pulp cavity

Tertiary dentinogenesis, dentin produced as a response to external stimuli and can be further divided into:

Reactionary dentin (new tubular dentin):

- (a) Produced by upregulated odontoblasts or a mixture of these odontoblast cells and new secondary odontoblast-like cells

Reparative dentin (two layers of hard tissue=dentinal bridge):

- (a) Initially a layer of atubular dentin=fibrodentin (nonodontoblast origin)
- (b) Followed by a layer of tubular dentin produced by new secondary odontoblast-like cells

to interpret in the clinic. Future hard tissue studies following vital pulp therapy should analyze in more detail how well newly formed tertiary dentin reacts as a barrier, in order to avoid late invasion of microorganisms, and what is the structural integrity of newly formed hard tissue.

The formation of reparative dentin might be beneficial in terms of blocking potential bacteria from invading the pulp due to the atubular interface, as opposed to the structure of the primary tubular dentin. However, it should be remembered that the reparative dentin might contain more organic material and be less mineralized than primary dentin. The more organic material the dentin comprises, the more permeable it will be, and therefore the reparative dentin represents an inferior type of dentin as compared to primary dentin [12]. Also it is important to note that reparative dentin with or without so-called tunnel defects, cannot keep away the bacterial invasion from untreated progressing caries and/or a leaking coronal restoration. The optimal endpoint for evaluating vital pulp therapy would be to determine the long-term clinical outcome of the pulp, i.e., function, healthy state, and capacity of preventing a secondary infection [24].

4.2.3 Inflammation and Tertiary Dentin

Most experimental studies on pulp capping and protective agents have been carried out in healthy teeth, which in reality makes it difficult to transform information into the clinical situation, where the exposed pulp most often is expected to be associated with various grades of inflammation. Severity of pulp inflammation may influence tertiary dentin. At the extreme, inflammation will lead to pulp necrosis, hence stop or even absence of any tertiary dentinogenesis. In contrast, milder degrees of pulp inflammation may seem beneficial for tertiary dentinogenesis [25]. Taken together, some treatment principles can be aligned for the vital pulp therapy promoting apexogenesis and tertiary dentinogenesis (Box 4.3).

Box 4.3. General Principles for Vital Pulp Therapy

- Removal of (i) bacterial infected dentin and (ii) clinically judged inflamed pulp tissue
- The application of a pulp protective agent stimulating reparative dentinogenesis
- To secure apexogenesis by the vital radicular pulp tissue
- Performance of a coronal seal for preventing secondary infection of the reparative dentin and hence the development of infected pulp necrosis associated with apical periodontitis

4.3 Clinical Evaluation of Inflammation

Before the principles of vital pulp therapy are laid out, it is important to recall that a precise clinical diagnosis of the degree of inflammation in the pulp is not possible [3]. Little or no correlation exists between the histological findings of pulp pathosis and clinical symptoms [26–28]. Moreover, in a clinical setting a diagnostic device is not yet available for objectively measuring a threshold of reversible pulp inflammation being beneficial or not for tertiary dentinogenesis. The diagnoses are based on interpretation of data from the pretreatment examination, the clinical examination, as well as the radiographic examination [29], rather than histopathological findings. Clinical data are shown for case selection that divide the condition of the pulp into so-called reversible pulpitis and irreversible pulpitis (Box 4.4).

Figure 4.2 shows a clinical example of an extremely deep caries lesion with direct exposure of the pulp prior to excavation. The patient arrived to the dental office with prolonged pain and disturbed night sleep. The clinical diagnosis “irreversible pulpitis” is further confirmed by the color of the blood being dark red. In this case also pus is apparent associated with a frank cavitation, and hemostasis is not possible to achieve, and root canal treatment is initiated.

Box 4.4. Reversible and Irreversible Pulpitis

Reversible pulpitis:

- A clinical diagnosis – based of the evaluation of subjective, clinical, and radiographic findings.
- Suggest that if the external stimuli are removed the pulp will return asymptomatic and vital after long term evaluation.
- Thermal changes (air, liquid) may produce a sharp transient pain.
- In case of pulp exposure hemostasis can be obtained.
- The diagnosis does not indicate the precise histological status of the pulp.

Irreversible pulpitis:

- It is a clinical diagnosis associated with subjective and objective findings indicating presence of pain (spontaneous and or prolonged unbearable pain/disturbed night sleep).
- Temperature changes may produce lingering pain.
- In case of pulp exposure hemostasis cannot be obtained.
- The diagnosis does not indicate the precise histological status of the pulp.

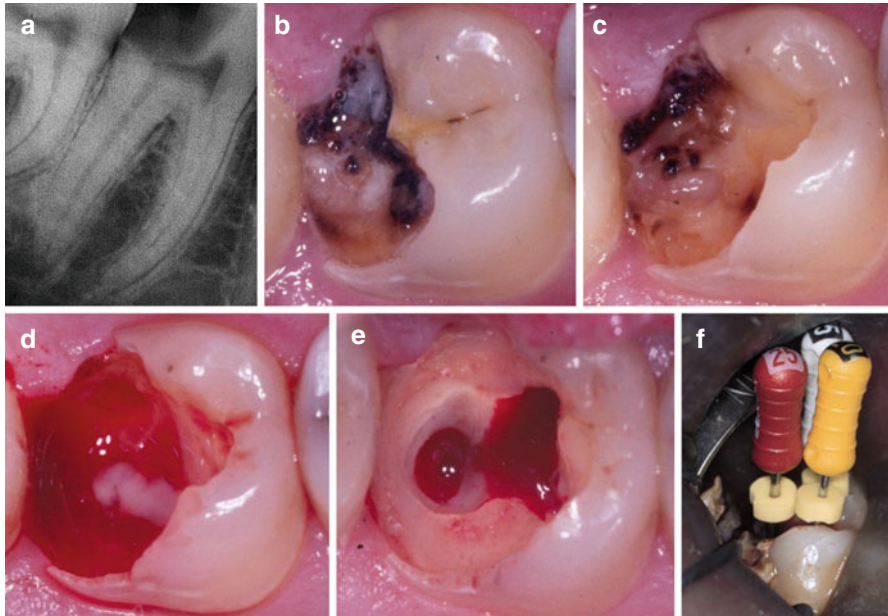


Fig. 4.2 (a) Preoperative periapical radiograph showing extremely deep caries lesion in the mandibular second molar with apical periodontitis. (b) Tooth shown before treatment. Clinically the tooth is vital and the combined diagnosis is “irreversible pulpitis” and apical periodontitis. (c) Following excavation an exposure of the pulp is present with pus. (d) During further access to the pulp cavity focal areas of pus are noted within the bleeding inflamed pulp. (e) Complete excavation performed before placement of “endodontic working” restoration and preparation of an aseptic working field. (f) Root canal treatment is initiated and determination of working length is about to be accomplished

4.4 Indications and Treatment Concepts for Vital Pulp Therapy

The principal indications for performing vital pulp therapy are carious lesions, mechanical iatrogenic injury, and trauma. In the context of molar endodontics, the most frequent cause for endodontic treatment including vital pulp therapy has, in the general practice environment, been caries [30]. Therefore, the aligned treatment guidelines are described within the “scenario” of a carious pulp exposure. From the literature, it is often unclear whether the clinicians are creating a pulp exposure by accident or whether it is the intention to do a pulp exposure; moreover the depth of the carious pulp exposures are seldom defined in clinical studies [31]. The following vital pulp therapy guidelines will include these aspects.

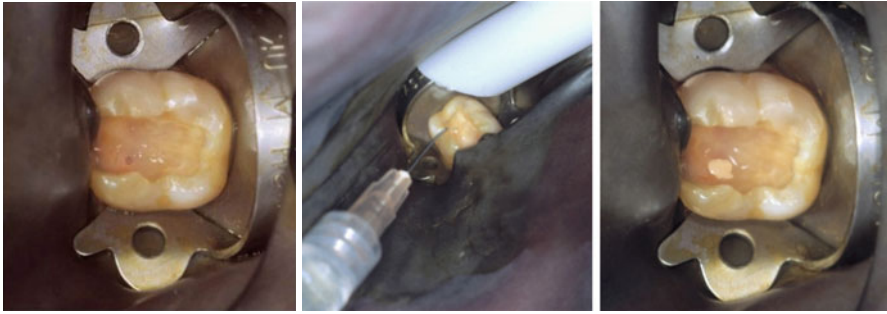


Fig. 4.3 (Left) Direct pulp capping Class I: an accidental pulp exposure has occurred during preparation. No additional enlargement is carried out. (Middle) The cavity is irrigated with saline. (Right) Calcium hydroxide capping material is placed prior to permanent restoration

4.4.1 Direct Pulp Capping Class I (Accidental Pulp Exposure)

No additional enlargement is made of the exposed pulp. Typically, the exposure has just occurred following a trauma or an accidental perforation during a preparation procedure (Fig. 4.3). It is a prerequisite that the pulp is healthy. Clinically, this means that the pulp is *vital* and the patient is without subjective pain prior to treatment, and hemostasis can be expected. The exposure of the pulp is less than 1 mm in diameter and should be located in the coronal third, but preferable in relation to a pulp horn. The pulp protective agent can be placed directly at the pulp exposure and the cavity can be sealed efficiently. It may also take place during excavation of caries, but in an area not directly related to the carious dentin, because the pulp exposure has been made by accident.

4.4.2 Direct Pulp Capping Class II (Intentional Pulp Exposure)

This modality includes the mandatory use of an operating microscope during caries excavation [32]. The potential implementation of carious dentin into the pulp during excavation can better be limited by the use of magnification. If hemostasis can be achieved it should be seen as the clinical interpretation of an acceptable and treatable pulp, but the exact extent of pulp inflammation is currently impossible to predict objectively in the clinical setting. No global consensus is available for this approach, and it may be argued that a pulp exposure shall be avoided by an indirect pulp therapy where less invasive excavation procedures are introduced (see below).

It has been shown in cases with deep or extremely deep caries that if the bacterial invasion zone penetrates the pulp close to reparative dentin, the subjacent pulp is severely inflamed [33], making both vital and indirect pulp therapy unpredictable treatment options. When irreversible inflammation in the pulp is present, hemostasis is typically not possible to obtain; therefore pulp capping is contraindicated in deep or extremely deep caries. However, when hemostasis can be controlled, such lesion depths may be successfully treated (Fig. 4.4). The result of apexogenesis following treatment of a deep carious lesion is shown in (Fig. 4.5).

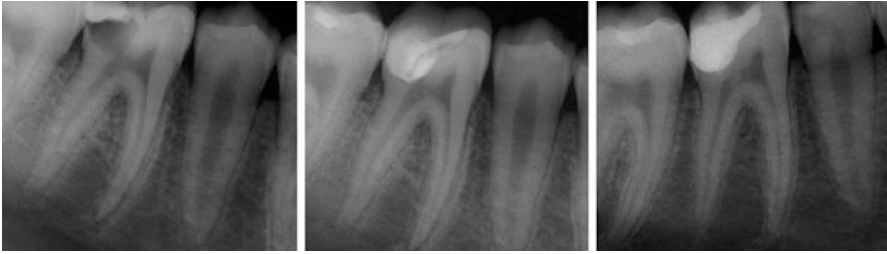

Fig. 4.4 (Left) Preoperative radiograph of a 12-year-old child showing first mandibular molar with extremely deep caries. (Middle) After excavation and carious exposure and MTA application. (Right): Postoperative 1-year follow-up. Tooth vitality present and well-defined *lamina dura* in the apical region. Note the formation of tertiary dentin (Courtesy of Dr. G. Bogen)

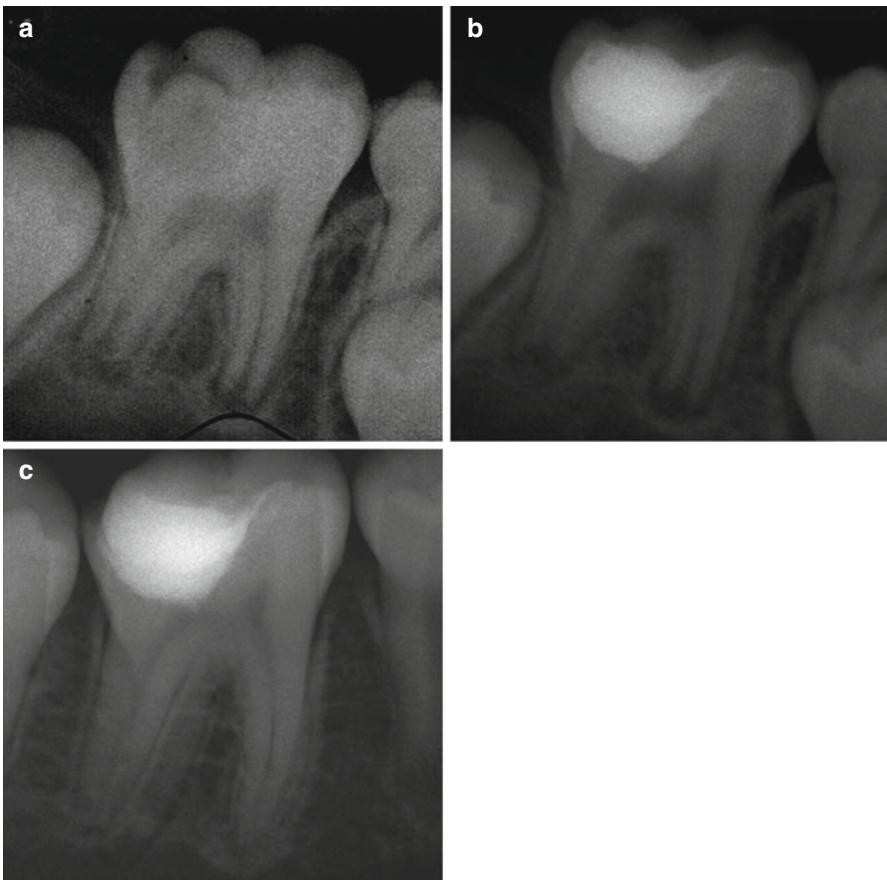

Fig. 4.5 (a) Preoperative radiograph of a 7-year old child, showing first mandibular molar with deep caries. (b) After excavation and carious exposure and MTA application. (c) Postoperative 3-year follow-up. Tooth vitality present and completed root formation (Courtesy of Dr. G. Bogen)

4.4.3 “Partial” Pulpotomy

As opposed to direct pulp capping, an additional removal of suspected inflamed pulp tissue is performed, and for providing a better seal of the pulp protecting agent, which may be a problem with complicated crown fractures [34]. The definition between a direct pulp cap procedure Class II and the partial pulpotomy appears to overlap in carious pulp exposures. In particular where the treatment is carried out under the conditions of “reversible pulpitis” [35–37], the argumentation of avoiding pulp exposure in the first place is in principle the same as indicated for *direct pulp capping Class II*. In contrast, a “several-day-trauma” tooth with exposed pulp represents the classical indication for this treatment modality, where the tissue is expected to be superficially and inflamed. In this situation, a superficial removal of pulp tissue is highly beneficial [34]. The completion of an incomplete root complex is shown following a partial pulpotomy (Fig. 4.6).

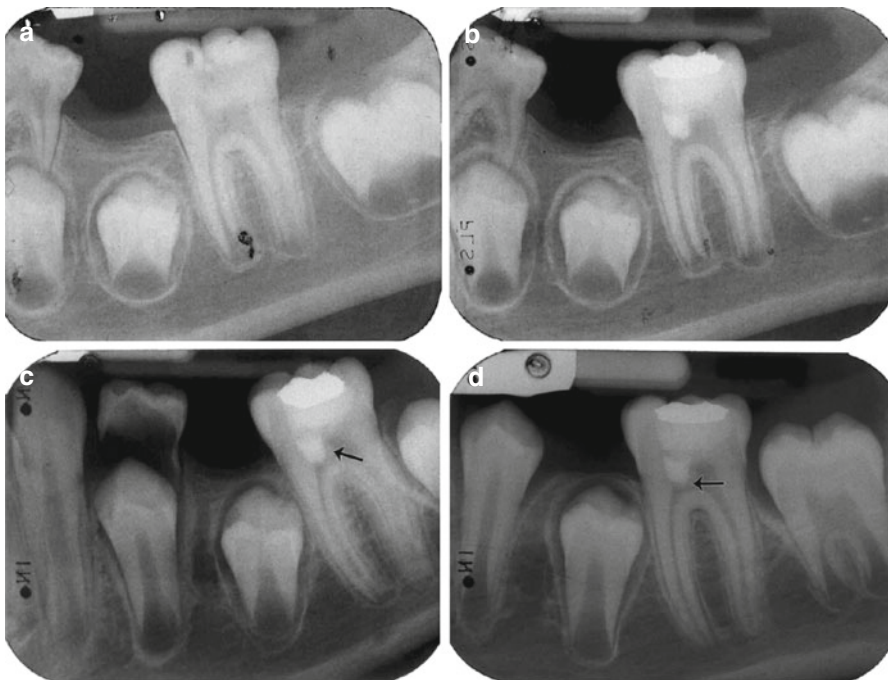


Fig. 4.6 (a) Preoperative periapical radiograph showing deep carious lesion in the mandibular first molar. (b) Postoperative radiograph taken immediately after treatment with partial pulpotomy and MTA. (c) Tooth: 16 months after treatment. Notice dentine bridge formation in the mesial side of the tooth (*arrow*). (d) Tooth: 26 months after treatment. Notice the well-formed dentinal bridge (*arrow*) and the physiological continuation of root formation (Reprinted from Barrieshi-Nusair and Qudeimat [37]; with permission)

4.4.4 “Full” Pulpotomy

In single rooted teeth, the definition includes the surgical amputation of the coronal portion of an exposed pulp, whereas in molar it covers the removal of the entire pulp tissue in the pulp chamber down to the orifices (1–2 mm into in the root canals). The rationale is to completely remove the inflamed pulp tissue. As the prognosis of the vital pulpectomy is very high (see Chap. 8) why then attempt a “full” pulpotomy?

In children it seems advisable to try a conservative pulp-preserving procedure, even in deeply carious permanent teeth with signs of “irreversible pulpitis,” whereby ideal conditions can be established, as already discussed the loss of the vital pulp function is so devastating in teeth with immature apices (Box 4.1). If failure then occurs, apexification or regenerative techniques can still be options. It has been speculated that a full pulpotomy could be a more permanent treatment option in cases of “irreversible pulpitis,” but with established hemostasis, but only case series and case report are available [38, 39].

4.4.5 “Emergency” Pulpotomy

Often “emergency” treatments are closely associated with the practical aspect of lacking time, as the patient arrives unexpected to the dental office and being in acute pain. Thus, a simple treatment is urgently needed to reduce the level of pain in the first place and then a treatment session can be scheduled for completing the final pulpectomy, when proper time is available. An “emergency” pulpotomy has shown to be able to reduce pain in relation to acute “irreversible pulpitis” and without the need of additional medicaments [40]. It is a temporary treatment, but with the surgical pulp approach being the same as the “full” pulpotomy, except for the temporary seal.

4.5 Brief Comments on Capping Agents

For decades the capping agent to promote healing and maintaining viability of the remaining pulp tissue has been a calcium hydroxide-containing material applied either as a base or as a liner. Within the last 20 years, calcium silicate-containing materials have gained more and more focus. In particular, MTA (mineral trioxide aggregate, Dentsply Tulsa Dental, OK, USA) has been investigated and used intensively. More recently other bioceramic cements have been introduced such as Biodentine (Septodont, Saint Maur des Fosses, France) or iRoot BP (Innovative BioCeramix, Vancouver, BC, Canada). Only limited clinical information is actually available to show potential clinical differences. The reason for selecting the silicate containing materials is therefore based mainly on laboratory studies, where it is shown that these materials may create a better quality of the hard tissue laid down, without so-called tunnel defects. Interestingly, a recent randomized clinical trial [41] showed no differences between the two classic pulp agents, i.e., the calcium hydroxide containing liner Dycal (DeTrey Dentsply, Skarpnäck, Sweden) and

MTA. This may also underline that other variables such as patient age and irreversible pulp inflammation may determine the prognosis accounting for problems leading to failure or not. Finally, larger studies may be needed to show actual differences, when it comes to the choice of the very best pulp agent.

4.6 Treatment Guidelines for Vital Pulp Therapy in Molars

4.6.1 Direct Pulp Capping Class I

Pretreatment Data

- Patient information: subjective evaluation of the region having the present symptom by questioning the patient on the area in focus, intensity, duration, stimulus, relief, and spontaneity. Absence of any signs of “irreversible pulpitis” is mandatory to permit *direct pulp capping* (Box 4.4).
- Objective extraoral examination as well as examination of the intraoral soft and hard tissues.
- Clinical examination showing a tooth that is vital with no lingering or persistent prolonged pain following thermal testing. Other tests such as palpation, percussion, and mobility should have negative findings.
- Radiographic examination: radiographs showing the involved tooth, furcation, periapical area, and the surrounding bone. No apical pathosis is present.

Diagnosis

- Reversible pulpitis

Treatment Protocol

- The tooth is isolated with rubber dam (mandatory for all types of vital pulp therapy).
- The cavity and the pulp exposure area are gently flushed with saline in order to remove detritus and to establish a clean nonbleeding pulp wound.
- Direct flush at the exposure should be avoided.
- Firm pressure with a cotton pellet should be avoided as the removal tends to reactivate bleeding.
- Hemostasis should be reached within 5 min.
- The site of the perforation should be noted in the file of the patient for the future plan of restoration.
- Pulp capping agent is applied at the exposure site and in contact with the tissue (e.g., calcium hydroxide containing base material or mineral-trioxide aggregate (MTA)) followed by a layer of glass-ionomer (Ketac Molar; 3 M ESPE, Glostrup, Denmark)
- A permanent restoration is placed immediately or within a few days in order to prevent secondary bacterial infection.
- After 6 months, the tooth is checked with respect to subjective symptoms and tooth vitality; in case of absence of any response, a radiographic examination is performed to diagnose potential apical pathosis.

Contraindications

- If hemostasis is not achieved, *direct pulp capping* is not done and pulpectomy is indicated (see Chap. 6)
- Direct pulp capping (Class I) should *not* be carried out in deep or extremely deep caries in adults (Fig. 4.1).

4.6.2 Direct Pulp Capping “Class II” and “Partial Pulpotomy”

Pretreatment Data

- Patient information: Absence of any signs of “irreversible pulpitis” is mandatory (Box 4.4)
- Objective extraoral examination as well as examination of the intraoral soft and hard tissues
- The tooth is vital (e.g., bleeding is observed from the exposure site), no lingering or persistent prolonged pain is found following thermal testing (this may, however, be difficult to ascertain in children)
- Radiographic examination; radiographs showing the involved tooth, furcation, periapical area, and the surrounding bone. No apical or furcal pathosis are present.

Diagnosis

- Reversible pulpitis

Treatment Protocol

All the steps are followed as described for adults. However, note additional details are mandatory for vital pulp therapy for the extremely deep caries lesion [32]:

- Excavation is carried out under the operating microscope and aided by the use of caries detector solution.
- Hemostasis is established within 5 min. following the use of 5.25% sodium hypochlorite.
- No specific rules about the size of the perforation which means that it is not a matter of choosing a “*direct pulp capping*,” “*partial*,” or even “*full*” *pulpotomy*; it is related to the fact whether or not hemostasis can be obtained.
- In case hemostasis is not occurring, the “*partial*” *pulpotomy* procedure is applied, which means that a 1.5–2 mm deep preparation is made with a sterile diamond bur in a high speed hand piece under water spray.
 - When hemostasis is obtained, MTA is applied in a thickness of 4–5 mm (mixed according to the manufacture’s prescriptions; however, as dry as possible).
 - Place moist cotton pellet over MTA followed by a solid interim restoration (composite or glass-ionomer cement, e.g., Ketac Molar; (3 M ESPE, Glostrup, Denmark)).
- After 1 week (or at least 2 days) the temporary restoration and the cotton pellet is removed for controlling a proper hardening of the capping agent, followed by a permanent restoration.

- Notably, the treatments have primarily been examined in children and even though the caries has been extremely deep the clinical diagnosis has been “reversible pulpitis” [32].

Contraindications

- If hemostasis cannot be achieved, direct pulp capping is omitted and pulpectomy is indicated (see Chap. 6).
- Without the use of the operating microscope it is not a so-called Class II modality.

4.6.3 “Full” Pulpotomy for Children and Adolescents

Pretreatment Data

- Patient information: No signs of “irreversible pulpitis” is first choice; however in case of incomplete root formation, signs of “irreversible pulpitis” should be a candidate for a “full” pulpotomy procedure.
- Objective extraoral examination as well as examination of the intraoral soft and hard tissues.
- Clinical examination: The tooth is vital (bleeding point from pulp exposure/fracture line), no lingering or persistent prolonged pain following thermal testing. This may be very difficult to do in children. In case of signs of “irreversible pulpitis,” the aspect of whether or not hemostasis can be obtained need to be confirmed clinically.
- Radiographic examination; radiographs showing the involved tooth, furcation, periapical area, and the surrounding bone. No apical or furcal pathosis is present.

Diagnosis

- Reversible pulpitis
OR
- Irreversible pulpitis and based on careful case selection

Treatment Protocol

- All pulp tissue is removed from the pulp chamber.
- The amputation area should be at the orifice (1.5–2 mm into the root canal) and eventually made with a sterile diamond bur in a high speed hand piece under water spray.
- Radicular pulp tissue is examined for hemostasis.
- A pulp capping material is placed, typically calcium hydroxide (DeTrey Dentsply, Skarpnäck, Sweden) or MTA.
- The blunt end of a paper point may be used to ensure that the capping material is proper placed. Seal the preparation including the entire pulp chamber in a thickness of 4–5 mm MTA.

- After 1 week (or at least 2 days), the temporary restoration and the cotton pellet are removed for controlling a proper hardening of the capping agent, followed by a permanent restoration.
- A practical approach has been to place a permanent restoration at once.
- If the patient presents with signs of “irreversible pulpitis,” but hemostasis can be successfully accomplished, an MTA pulpotomy procedure may be considered as an alternative treatment [39, 40]. In such cases it is recommended that the patient receive a relatively short follow-up visit within the following 2 days to assess subjective symptoms. Concomitantly, an assessment of MTA setting may be performed followed by a permanent restoration.

Contraindications

- If hemostasis is not achieved, pulpectomy is indicated (Chap. 6).

4.6.4 Indications for Indirect Pulp Therapy

In relation to deep caries the decision to treat the pulp indirectly may be considered. An indirect pulp therapy addresses the excavation of deep dentin aiming to avoid pulp exposure. The therapy may be performed either in one or two treatment sessions.

Much research during the past decades has modified the original concept of a pulp close excavation during the indirect pulp therapy [42]. For example, Kerkhove et al. [43] described it as leaving only residual caries, meaning that if a further limited excavation was carried out, a pulp exposure would be present. Other studies have introduced less invasive and partial excavation procedures leaving more carious dentin behind permanently and with an apparent good prognosis, primarily in children [44–46]; therefore the original invasive concept of indirect pulp therapy appears outdated.

4.6.5 Stepwise Exaction (2-Step Approach)

The concept of performing two treatment sessions is also described as a stepwise excavation. The focus of the first treatment/excavation appointment is not to reach residual caries close to the pulp, as the risk of exposure of the pulp increases the closer the excavation is performed [47, 48]. In contrast, the aim of the first treatment is to change the active cariogenic environment. The consequence of leaving carious dentin temporarily subjacent to a so-called treatment restoration is that the clinical features of carious dentin will change to that of slowly progressing or arrested caries [49, 50]. The active deep carious environment can clinically be recognized as a soft discolored and wet tissue, which may change towards a darker harder and drier appearance of the carious dentin. Clinically, a second and final excavation of arrested carious dentin will be easier to accomplish without risking a pulp exposure.

High-level evidence data have shown that a stepwise excavation approach led to a significant decrease in the number of pulp exposures as opposed to complete excavation [51, 52]. This approach may be carried out within a practice-based environment even with the concept of two visits [53]. Within communities where it would be difficult to receive the patient for an additional appointment, a one-step partial caries removal approach might be the treatment of choice; however the evidence behind is lower [47].

4.6.6 Detailed Treatment Guidelines for Indirect Pulp Therapy

Stepwise Excavation and Partial Excavation

The present two protocols refer to methods supported by high level of evidence. The first protocol takes adults into account, aiming to prevent exposure of the pulp using stepwise excavation: The last procedure is the partial excavation in one step aiming to prevent over-excitation in children (<18 years). Note the restrictions in both protocols:

Pretreatment Data (Stepwise Excavation)

- Patient information; subjective evaluation of the region having the present symptom by questioning the patient on the area in focus, intensity, duration, stimulus, relief, and spontaneity. No signs of “irreversible pulpitis” is mandatory for stepwise excavation (no unbearable pain causing disturbed night sleep).
- Objective extraoral examination as well as examination of the intraoral soft and hard tissues.
- Clinical examination: The tooth is vital with no lingering or persistent prolonged pain following thermal testing. Other tests such as palpation, percussion, and mobility should have negative outputs.
- Radiographic examination; radiographs showing the involved tooth, furcation, periapical area, and the surrounding bone. No apical pathosis is present. The depth of the caries lesion is in the pulpal quarter, and there is a well-defined radiopaque zone between the pulp and caries lesion defined here as a deep lesion (Fig. 4.1).

Treatment Protocol (Stepwise Excavation) [49]

- Remove as much of the superficial necrotic and demineralized dentin, so that a temporary restoration can be placed in the cavity.
- No excavation close to the pulp.
- Calcium hydroxide-based material and glass-ionomer are placed.
- Treatment interval 3–9 months.
- Final excavation is carried out using hand excavators.
- Calcium hydroxide based material and final permanent restoration is placed (Fig. 4.7).

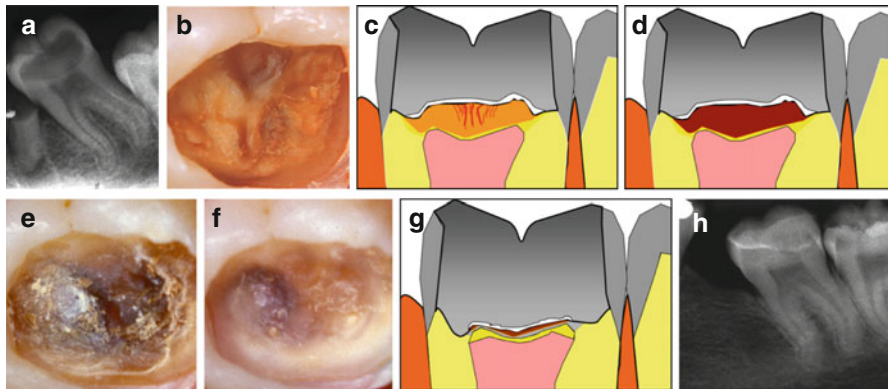


Fig. 4.7 Principle demonstration of the stepwise excavation approach of a molar. (a) Radiographic feature of a secondary molar with deep caries. (b) Cariogenic surface plaque and undermined enamel removed visualizing the exposed carious dentin. (c) A sketch of the temporization of the retained active carious dentin after 1-step. (d) After the treatment interval retained carious dentin will become darker, harder, and drier. (e) The retained carious dentin shown after removal of the temporary restoration. (f) Complete excavation is carried out to optimize the cavity for final restoration, and has been facilitated due to decrease of caries activity. (g) A sketch of the permanent restoration is in place. (h) A 4-year follow-up with no apical pathology. However, complete arrest of caries activity has not been achieved; a new proximal lesion has progressed in the third molar

Pretreatment Data (Partial Excavation)

- Patient information: identical to stepwise.
- Objective extraoral examination as well as examination of the intraoral soft and hard tissues.
- Clinical examination: identical to stepwise.
- Radiographic examination: radiographs showing the involved tooth, furcation, periapical area, and the surrounding bone. No apical pathosis is present. The depth of the caries lesion is in pulpal quarter, and starting from half the dentin thickness and into the pulp.

Treatment Protocol (Partial Excavation) [44]

- Remove as much of the superficial necrotic and demineralized dentin, so the permanent restoration can be placed.
- Final excavation is carried out using hand excavators.
- Calcium hydroxide based material and final permanent restoration is placed (Fig. 4.8).
- The partial excavation approach has not been systematically examined in adults.

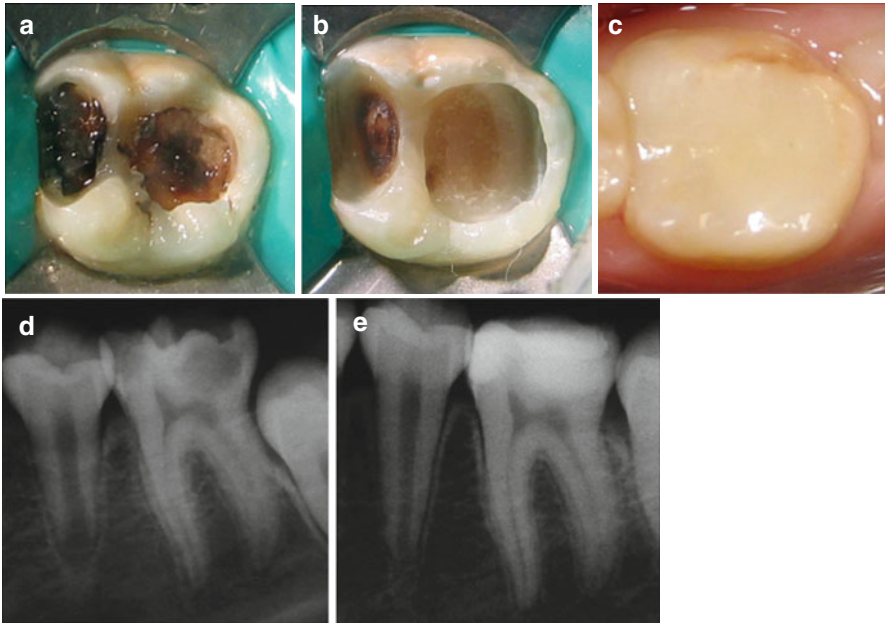


Fig. 4.8 Clinical photographs and radiographs depicting a 1-visit indirect pulp therapy of permanent mandibular left first molar. **(a)** Tooth with a deep carious lesion with large accumulations of cariogenic biomasses. **(b)** Clinical photograph showing the cavity preparation (caries was not completely removed at areas close to the pulp), prior to the final restoration. **(c)** Clinical view after 1-year follow-up. **(d)** The pretreatment radiograph shows no apical pathosis, but a deep carious lesion. **(e)** After 1 year, the radiograph shows no apical radiolucency with successful treatment (Reprinted from Orhan et al. [51]; with permission)

4.7 Factors Controlling Prognosis

Some factors controlling prognosis have been discussed for vital [9] and indirect pulp therapy [47, 52] in relation to caries. The prognosis is connected to methodological problems related to comparing data, which were not prospectively obtained so the following findings should be interpreted with caution.

Based on so-called pooled data, the success rates were reported to be 72.9% for direct pulp capping (no distinction was made between Class I and II) with a recall period more than 3 years (patients: 6–10 years of age; $n=231$), and 99.4% for partial pulpotomy (patients, 6–27 years of age; $n=23$) and 99.3% (patients, 6–70 years of age; $n=37$) for full pulpotomy [9]. Taken together these data indicate that the vital pulp therapy is effective with an acceptable outcome, and proper case selection should indicate the specific treatment needed.

A more recent retrospective observational study [54] suggested a 2-year survival rate of 56.2% (patients, mean age 41 years, $n=51$) for pulp capping. The relatively low survival rate confirms previous observational data suggesting that the prognosis

of pulp capping may be related to age [9, 55]. Within a recent randomized clinical multicenter trial examining *pulp capping* versus *partial pulpotomy* in cariously exposed pulps in adults [52], the results showed an even worse outcome following both *direct pulp capping* (Class I) and *partial pulpotomy*, with a pooled pulp survival rate of only 33.2% after 1½ year. The results showed that a caries lesion, located in the inner ¼ of the dentin in adults, may represent the threshold for successful full pulp capping in adults, and without the use of magnification (Class I). In short, age of the patient and caries lesion depths are important prognostic variables.

In Box 4.5 variables are listed that influence prognosis.

Box 4.5. Potential Factors Increasing Success of Vital Pulp Therapy

- Aseptic working field with rubber dam isolation – mandatory
- Younger age – better prognosis
- Immediate placement of the definitive restoration – to secure and prevent secondary infection
- Mechanical/accidental exposure vs. an attempted carious exposure – If Class I or Class II protocols are chosen acceptable prognosis can be expected even in cariously exposed pulps but proper case selection is mandatory.
- Size of exposure? If hemostasis can be obtained not an issue – important to reach direct contact and without a blood clot in between the agent and the pulp tissue.
- Pulp protective agent – no high evidence data to select one particular material from another but MTA and calcium hydroxide have been the two most often used, with the former being the most often chosen material recently.
- Pulpal inflammation that is judged reversible (see below).

Pulp status must be evaluated before treatment:

- Patients' symptoms and history is not enough.
- Radiographic interpretation is not enough.
- Use objective pulpal tests and arrive to complete pulpal and periapical diagnoses.
- Hemostasis

4.8 The Indications for Vital Pulp Therapy May Change Over Time

Undoubtedly the vital pulp therapies have been established and developed in their own context of time and tradition. The focus of full pulpotomy has been to maintain a vital radicular pulp in order to secure the completion of the root complex in

immature teeth (apexogenesis), and particularly to avoid the necrotic and bacterial infected incomplete root complex.

About 50 years ago the prevalence of caries worldwide as well as the speed of caries progression was higher than today [56]. If a “deep” or an “extremely deep” lesion is present even before the root complex is fully completed, the speed of caries progression has been obviously very high. Accordingly, it can be speculated that the degree of inflammation in “pulp with carious exposures in the 1960s” was often in a more severe and irreversible stage than what can be observed today. In other words, the rationale and the magnitude of using “full” pulpotomy may have changed today, as the speed of the caries progression has reduced.

However, as a paradox the “full” pulpotomy treatment has started to be reevaluated [57], and it may be an alternative to the vital pulpectomy, as the research area of pulp regeneration has developed rapidly. In this chapter, “full” pulpotomy has been presented with respect to (I) securing apexogenesis, and (II) being the emergency treatment approach for the acute “irreversible pulpitis” in molars.

However, pulpotomy is a highly integrated treatment approach for the future revascularization procedure, and perhaps particularly in necrotic teeth with an incomplete root complex [58, 59]. A revascularization protocol has been suggested, but currently being modified and tested [60, 61]. At this point in time, only limited evidence from case reports illustrates the potential for regenerative therapy in molars as opposed to single-rooted teeth (Box 4.6).

Box 4.6. Revascularization Protocol

- Patient/parent compliance with the necessary multiple appointment treatment plan may be significant for case selection.
- Disinfect canal but no mechanical instrumentation is performed.
- Irrigate with sodium hypochlorite.
- Dry root canal.
- Triple antibiotic paste – (*metronidazole, ciprofloxacin, minocycline*) *be aware of staining of the tooth with the use of minocycline.*
- Recently suggested that a classic calcium hydroxide dressing might be as beneficial as the triple paste but not tested in a randomized design.
- Perform temporary restoration.

Two to three weeks later:

- Remove medicament with sodium hypochlorite irrigation.
- Induce bleeding from apical tissue (use of an anesthetic without a vasoconstrictor when trying to induce bleeding).
- Control intracanal hemorrhage to below the CEJ with pressure.
- Place MTA over blood clot to level of CEJ (a collagen matrix is useful for the controlled placement of MTA to a desired and optimal level).
- Perform permanent restoration.

4.9 Summary

- Carious pulp exposures are the most frequent cause for vital pulp therapy in molars.
- Case selection should be performed with attention toward age of the patient and depth of the caries lesion.
- Vital and indirect pulp therapies should be seen as permanent treatments.
- Direct capping Class I should be avoided in the pulpal inner one-fourth.
- Direct pulp Class II is designed for deep and extremely deep caries with the mandatory use of magnification.
- High evidence data indicate that the two-step indirect approach should be the treatment of choice in carious lesions extending into the pulpal one-fourth of the dentin in adults.
- No difference can be found between direct pulp capping and partial pulpotomy in adults.
- Pulpotomy might be the future technical approach for even case with irreversible signs of pulpitis – but hemostasis is mandatory.
- No systematic clinical evidence is yet available for molars and pulp regeneration. Moreover, the main focus addresses the necrotic root canal.

References

1. Black GV. A work on operative dentistry in two volumes. Vol. II the technical procedures in filling teeth. 2nd ed. Chicago: Medico-Dental Publishing; 1908.
2. Tomes J. A system of dental surgery. London: John Churchill; 1859. p. 336.
3. Dumsha T, Hovland E. Considerations and treatment of direct and indirect pulp-capping. *Dent Clin North Am.* 1985;29:251–9.
4. Seale NS. Indirect pulp therapy: an alternative to pulpotomy in primary teeth. *Tex Dent J.* 2010;127:1175–83.
5. Seal NS, Glickman GN. Contemporary perspective on vital pulp therapy: views from the endodontists and pediatric dentists. *J Endod.* 2008;34:S57–61.
6. Mejáre IA, Axelsson S, Davidson T, Frisk F, Hakeberg M, Kvist T, Norlund A, Petersson A, Portenier I, Sandberg H, Tranæus S, Bergenholtz G. Diagnosis of the condition of the dental pulpa: a systematic review. *Int Endod J.* 2012;45:597–613.
7. Nadin G, Goel BR, Yeung CA, Glennly AM. Pulp treatment for extensive decay in primary teeth. *Cochrane Database Syst Rev.* 2003;(1):CD003220. doi: [10.1002/14651858.CD003220](https://doi.org/10.1002/14651858.CD003220).
8. Miyashita H, Worthington HV, Qualtrough A, Plasschaert A. Pulp management for caries in adults: maintaining pulp vitality. *Cochrane Database Syst Rev.* 2007;(2):CD004484. doi: [10.1002/14651858.CD004484.pub2](https://doi.org/10.1002/14651858.CD004484.pub2).
9. Aguilar P, Linsuwanont P. Vital pulp therapy in vital permanent teeth with cariously exposed pulp: a systematic review. *J Endod.* 2011;37:581–7.
10. MESH definition. Accessed 11 Feb 2016 from <http://www.ncbi.nlm.nih.gov/mesh/?term=pulp+exposure>.
11. Webber RT. Apexogenesis versus apexification. *Dent Clin North Am.* 1984;28:669–97.
12. Mjör IA. Human coronal dentine: structure and reactions. *Oral Surg.* 1972;33:810–23.
13. Trowbridge HO. Pathogenesis of pulpitis resulting from dental caries. *J Endod.* 1981;7:52–60.
14. Baume LJ. The biology of pulp and dentine. A historic, terminologic-taxonomic, histologic-biochemical, embryonic and clinical survey. *Monogr Oral Sci.* 1980;8:1–220.

15. Lesot H, Béque-Kirn C, Kubler MD, Meyer JM, Smith AJ, Cassidy N, Ruch JV. Experimental induction of odontoblast differentiation and stimulation during reparative processes. *Cells Mat.* 1993;33:201–17.
16. Smith AJ, Tobias RS, Plant CG, Browne RM, Lesot H. Odontoblast stimulation in ferrets by dentine matrix components. *Arch Oral Biol.* 1994;39:13–22.
17. Simon S, Smith AJ, Bernal A, Lumley PJ, Cooper PR. The MAP kinase pathway is involved in odontoblast stimulation via p38 phosphorylation. *J Endod.* 2010;36:256–9.
18. Simon SRJ, Bernal A, Cooper PR, Lumley PJ, Tomson PL, Smith AJ. Dentin-pulp complex regeneration: from lab to clinic. *Adv Dent Res.* 2011;23:340–5.
19. Couve E, Osorio R, Schmachtenberg O. The amazing odontoblast: activity, autophagy, and aging. *J Dent Res.* 2013;92(9):765–72.
20. Bjørndal L, Darvann T, Thylstrup A. A quantitative light microscopic study of the odontoblastic and subodontoblastic reactions to active and arrested enamel caries without cavitation. *Caries Res.* 1998;32:59–69.
21. Magloire H, Bouvier M, Joffre A. Odontoblast response under carious lesions. *Proc Finn Dent Soc.* 1992;88:257–74.
22. Smith AJ, Scheven BA, Takahashi Y, Ferracane JL, Shelton RM, Cooper PR. Dentine as a bioactive extracellular matrix. *Arch Oral Biol.* 2012;57:109–21.
23. Bjørndal L, Darvann T. A light microscopic study of odontoblastic and non-odontoblastic cells involved in the tertiary dentinogenesis in well-defined cavitated carious lesions. *Caries Res.* 1999;33:50–60.
24. Olsson H, Petersson K, Rohlin M. Formation of a hard tissue barrier after pulp capping in humans. A systematic review. *Int Endod J.* 2006;39:429–42.
25. Cooper PR, Takahashi Y, Graham LW, Simon S, Imazato S, Smith AJ. Inflammation-regeneration interplay in the dentine-pulp complex. *J Dent.* 2010;38:687–97.
26. Seltzer S, Bender IB, Ziontz M. The dynamics of pulp inflammation: correlations between diagnostic data and actual histologic findings in the pulp. *Oral Surg Oral Med Oral Pathol.* 1963;16:846–71.
27. Seltzer S, Bender IB, Ziontz M. The dynamics of pulp inflammation: correlations between diagnostic data and actual histologic findings in the pulp. *Oral Surg Oral Med Oral Pathol.* 1963;16:969–77.
28. Dummer PM, Hicks R, Huws D. Clinical signs and symptoms in pulp disease. *Int Endod J.* 1980;13:27–35.
29. Reit C. Värdering av information. *Tandläkertidningen.* 1995;87:67–77.
30. Bjørndal L, Reit C. The annual frequency of root fillings, tooth extractions and pulp-related procedures in Danish adults during 1977–2003. *Int Endod J.* 2004;37:782–8.
31. Bjørndal L, Demant S, Dabelsteen S. Depth and activity of carious lesions as indicators for the regenerative potential of dental pulp after intervention. *J Endod.* 2014;40:S76–81.
32. Bogen G, Kim JS, Bakland LK. Direct pulp capping with mineral trioxide aggregate: an observational study. *J Am Dent Assoc.* 2008;139:305–15.
33. Reeves R, Stanley HR. The relationship of bacteria penetration and pulpal pathosis in carious teeth. *Oral Surg Oral Med Oral Pat.* 1966;22:59–65.
34. Cvek M. A clinical report on partial pulpotomy and capping with calcium hydroxide in permanent incisors with complicated crown fracture. *J Endod.* 1978;4:232–7.
35. Mejáre I, Cvek M. Partial pulpotomy in young permanent teeth with deep carious lesions. *Endod Dent Traumatol.* 1993;9:238–42.
36. Mass E, Zilberman U. Clinical and radiographic evaluation of partial pulpotomy in carious exposure of permanent molars. *Pediatr Dent.* 1993;15:257–9.
37. Barrieshi-Nusair KM, Qudeimat MA. A prospective clinical study of mineral trioxide aggregate for partial pulpotomy in cariously exposed permanent teeth. *J Endod.* 2006;32:731–5.
38. Witherspoon DE, Small JC, Haris GZ. Mineral trioxide aggregate pulpotomies: a case series outcome assessment. *J Am Dent Assoc.* 2006;137:610–8.
39. Eghbal MJ, Asgary S, Baglue RA, Parirokh M, Ghoddsi J. MTA pulpotomy of human permanent molars with irreversible pulpitis. *Aust Endod J.* 2009;35:4–8.
40. Hasselgren G, Reit C. Emergency pulpotomy: pain relieving effect with and without the use of sedative dressings. *J Endod.* 1989;15:254–6.

41. Chailertvanitkul P, Paphangkorakit J, Sooksantisakoonchai N, Pumas N, Pairojamornyoot W, Leela-Apiradee N, Abbott PV. Randomized control trial comparing calcium hydroxide and mineral trioxide aggregate for partial pulpotomies in cariously exposed pulps of permanent molars. *Int Endod J*. 2014;47:835–42.
42. Bjørndal L, Mjör IA. Dental caries: characteristics of lesions and pulpal reactions. In: Mjör IA, editor. *Pulp-dentin biology in restorative dentistry*. Chicago: Quintessence; 2002. p. 55–75.
43. Kerkhove Jr BC, Herman SC, Klein AI, McDonald RE. A clinical and television densitometric evaluation of the indirect pulp capping technique. *J Dent Child*. 1967;34:192–201.
44. Maltz M, de Oliveira EF, Fontanella V, Bianchi R. A clinical microbiological, and radiographic study of deep caries lesions after incomplete caries removal. *Quint Int*. 2002;33:151–9.
45. Gruythuysen R, van Strijp G, Wu M-K. Long-term survival of indirect pulp treatment performed in primary and permanent teeth with clinically diagnosed deep carious lesions. *J Endod*. 2010;36:1490–3.
46. Maltz M, Garcia R, Jardim JJ, et al. Randomized trial of partial vs. stepwise caries removal: 3-year follow-up. *J Dent Res*. 2012;91:1026–31.
47. Ricketts D, Lamont T, Innes NP, Kidd E, Clarkson JE. Operative caries management in adults and children. *Cochrane Database Syst Rev*. 2013;(3):CD003808. doi: [10.1002/14651858.CD003808.pub3](https://doi.org/10.1002/14651858.CD003808.pub3). Review.
48. Schwendicke F, Meyer-Lueckel H, Dörfer C, Paris S. Failure of incompletely excavated teeth – a systematic review. *J Dent*. 2013;41:569–80.
49. Bjørndal L, Larsen T, Thylstrup A. A clinical and microbiological study of deep carious lesions during stepwise excavation using long treatment intervals. *Caries Res*. 1997;31:411–7.
50. Orhan AI, Oz FT, Ozcelik B, Orhan K. A clinical and microbial comparative study of deep carious lesion treatment in deciduous and young permanent molars. *Clin Oral Invest*. 2008;12:369–78.
51. Orhan AI, Firdevs TO, Orhan K. Pulp exposure occurrence and outcomes after 1- or 2-visit indirect pulp therapy vs complete caries removal in primary and permanent molars. *Pediatric Dent*. 2010;32:347–55.
52. Bjørndal L, Reit C, Bruun G, et al. Treatment of deep caries lesions in adults: randomized clinical trials comparing stepwise vs. direct complete excavation, and direct pulp capping vs. partial pulpotomy. *Eur J Oral Sci*. 2010;118:290–7.
53. Bjørndal L, Thylstrup A. A practice-based study on stepwise excavation of deep carious lesions in permanent teeth: a 1-year follow-up study. *Community Dent Oral Epidemiol*. 1998;26:122–8.
54. Miles JP, Gluskin AH, Chambers D, Peters OA. Pulp capping with mineral trioxide aggregate (MTA): a retrospective analysis of carious pulp exposures treated by undergraduate dental students. *Oper Dent*. 2010;35:20–8.
55. Hørsted P, Søndergaard B, Thylstrup A, EL Attar K, Fejerskov O. A retrospective study of direct pulp capping with calcium hydroxide compounds. *Endod Dent Traumatol*. 1985;1:29–34.
56. Marthaler TM. Changes in dental caries 1953–2003. *Caries Res*. 2004;38:173–81.
57. Simon S, Perard M, Zanini M, Smith AJ, Charpinter E, Djole SX, Lumley PJ. Should pulp chamber pulpotomy be seen as a permanent treatment? Some preliminary thoughts. *Int Endod J*. 2013;46:79–87.
58. Banchs F, Trope M. Revascularization of immature permanent teeth with apical periodontitis: new treatment protocol? *J Endod*. 2004;30:196–200.
59. Lovelace TW, Henry MA, Hargreaves KM, Diogenes A. Evaluation of the delivery of mesenchymal stem cells into the root canal space of necrotic immature teeth after clinical regenerative endodontic procedure. *J Endod*. 2011;37:133–8.
60. Petrino JA, Boda KK, Shambarger S, Bowles WR, McClanahan SB. Challenges in regenerative endodontics: a case series. *J Endod*. 2010;36:536–41.
61. Torabinejad M, Turman M. Revitalization of tooth with necrotic pulp and open apex by using platelet-rich plasma: a case report. *J Endod*. 2011;37:265–8.

Frank C. Setzer and Helmut Walsch

Abstract

The preparation of an endodontic access is a key step during root canal therapy, in particular for molar teeth. This chapter describes design and preparation of molar access cavities to facilitate successful endodontic therapy and to identify, avoid, and overcome potential complications that may arise during treatment. Procedural errors during access significantly reduce the expected outcome for root canal treatment; therefore detailed knowledge of canal and tooth anatomy and a conscientious instrumentation strategy is required for this step in molar endodontics.

Guiding Reference

Abbott PV. Assessing restored teeth with pulp and periapical diseases for the presence of cracks, caries and marginal breakdown. *Aust Dent J.* 2004;49:33–9.

When accessing teeth for root canal treatment, dentin preservation is relevant; however one must not neglect to remove the common factors that may have caused the pulp and periapical disease, and to assess the tooth's prognosis and future treatment needs.

F.C. Setzer, DMD, PhD, MS (✉)
Department of Endodontics, Penn Dental Medicine,
240 South 40th Street, Philadelphia, PA 19104, USA
e-mail: fsetzer@upenn.edu

H. Walsch, DMD, PhD, MS
Department of Endodontics, Penn Dental Medicine, Philadelphia, PA 19104, USA
Private Practice, Baierbrunnerstr. 25, 81379 Munich, Germany
e-mail: hewalsch@hotmail.com

5.1 Introduction

The preparation of an endodontic access is a key step during root canal therapy, in particular for molar teeth. With typically more limited mouth opening and more complicated root canal anatomy, the access to the root canal system proves central to avoid clinical complications and to aid in providing long-term success. Historically, ideal access cavity preparations were recommended for individual tooth types. Clinically, however, an ideal situation is rarely encountered and the level of difficulty in endodontically accessing and treating a tooth will depend on a variety of factors, including tooth-specific and patient-specific variables.

Patient related variables include:

- General health and the anatomy of the orovestibular and craniofacial environment, including mouth opening dimensions
- Disorders of the temporomandibular joint, the anatomy of the dental arches and occlusion, and related pathologic conditions within the mouth

Tooth related factors include:

- Periodontal and endodontic status, including pulpal and periapical diagnoses
- Restorative prognosis, including the extent of tooth structure loss
- Ability to restore the tooth with adequate ferrule effect and biological width
- Anatomy of pulp chamber, roots, and root canal system, including the changes in the structure or size of the pulp chamber, canal orifices, or the individual canals due to mineralizations

Moreover, in case of a history of previous root canal treatment, iatrogenic alterations of the root canal system, such as perforations, transportations, or separated instruments, may pose challenges. Overall, the ability to clean and/or disinfect the root canal system and either prevent or eliminate apical periodontitis will depend to a great extent on the clinician's ability to gain access to the root canal system.

The present chapter will describe the assessment, preparation, and execution of molar access cavities to identify, avoid, and overcome potential complications that may arise during treatment and guide to a practical access to the root canal system.

Sufficient diagnostic radiographs in parallel technique are a prerequisite to arrive at a correct endodontic diagnosis. However, for endodontic treatment planning involving molars, one radiograph may not be enough for proper treatment. In this case, it is necessary to take several angled radiographs in mesial/distal angulations to fully appreciate root canal morphology, the extent of decay and existing restorations, the dimensions of the pulp chamber proper and the pulp horns, mineralizations in chamber and root canals, or anomalies such as internal or external

resorption [1–4]. Additional bitewing radiographs may be obtained to evaluate the remaining tooth structure and the dimensions and orientation of the pulp chamber. Prior to accessing a molar, the preoperative radiographs should be carefully interpreted as to the exact location and size of the access opening, and the radiographic image should be transferred to the clinical situation. Particular care must be given to any possible shifting of the tooth axis, particularly in combination with crown restorations mimicking the original orientation of the former natural crown. For nonsurgical retreatment situations, a limited volume-of-interest cone beam CT may be indicated if a reason for failure of the initial treatment cannot be readily identified by means of periapical radiographs [5].

5.2 General Considerations Prior to Endodontic Access in Molars

After careful interpretation of both clinical and radiographic examination and prior to accessing the tooth, the clinician must have formed a clear mental picture of the steps necessary for proper access, the potential complications, and the precautions to avoid any iatrogenic errors. This includes the assessment of the size and position of any existing restoration and/or decay, angulation and rotation of the tooth, orientation of the pulp chamber in relation to crown and roots, mineralizations and pulp stones, position of the furcation and extensions of root trunks, distance from the occlusal surface of the tooth to the cemento-enamel junction, curvatures of roots, and the position of canal orifices. These deliberations will not only maximize the success of the actual access cavity preparation, but will also help in making the overall treatment procedure easier (Box 5.1). After proper anesthesia and rubber dam isolation, the rubber dam should be disinfected to prevent incidental contamination with oral bacteria on the rubber dam or the rubber dam clamp. This can be done by using chlorhexidine 2%, iodine tincture, or sodium hypochlorite. Great caution has to be taken that the rubber dam isolation does not leak in either direction, to prevent contamination from saliva, but also to prevent sodium hypochlorite accidents if the solution penetrates through the rubber dam isolation. Block out resins or gels may be indicated if proper isolation cannot be achieved with rubber dam and clamp alone. In general, the actual opening of the pulp chamber should only be made after the decay has been removed to avoid initial or further contamination of the root canal system, in particular for teeth with irreversible pulpitis, where the pulpal disease is primarily of inflammatory origin and the deeper layers of the pulp are not yet infected. Teeth with extensive decay mesially or distally may require the extension of the rubber dam to include one or both of the adjacent teeth to allow proper caries or restoration removal without compromising the seal of the rubber dam. In general, with certain exceptions for crowns and bridges as discussed later in this chapter, an existing restoration should be removed together with any decay. This will not only allow the identification of problems such as craze lines or fractures, but also provide easier access to the pulp chamber and the root canals [6].

Box 5.1. Ideal Access Cavity

An ideal molar access cavity provides good visualization and facilitates identification of all canal orifices to achieve thorough cleaning and shaping of all coronal pulp spaces and the root canal system, while not excessively weakening the tooth structure. As a general guideline, one should remove as little as possible, but only as much as necessary tooth structure.

Depending on the extent of the decay and the ability to isolate the tooth sufficiently with little remaining tooth structure, it may be necessary to build up the tooth prior to endodontic access. Alternatively, if adequate isolation can be provided without initial build-up, the tooth may receive a complete build-up when the endodontic procedure is completed. However, this is under the condition that a stable, well-sealing temporary restoration can be provided in between sessions if a multivisit procedure is indicated.

Upon access, the practitioner should mentally visualize the outline, shape, and extent of the pulp chamber. As a general rule of thumb, the horizontal outline of the pulp chamber will follow the cross-section of the tooth at the cemento-enamel junction (CEJ) [7]. The clinician should align the bur with the long axis of the tooth and initially aim for the center of the pulp chamber. A recommendation for access burs depends on the coronal restoration and extension of the pulp chamber. For any metal restoration, carbide burs are indicated. The initial access through a crown (indications see below) should be carried out by using a diamond bur for the ceramic portion of the crown to avoid chipping and cracking of the restoration. The metal portion of the crown will then be penetrated by a carbide bur. The actual access to the pulp chamber should be carried out by using a straight conical diamond bur. These diamond burs may be coated at the tip or noncutting, which may provide some additional safety from destroying pulpal floor anatomy. A straight diamond bur will allow for easier orientation than a round bur and will create less undercuts. In an adolescent or adult patient, if no tertiary dentin or pulp chamber mineralizations are present, the clinician should feel a sudden drop after reaching the pulp chamber. In general, root canals are larger in younger patients [8]. In older patients or where a long-standing low-grade inflammation has been present, this drop into the pulp chamber may not be felt due to the presence of mineralization or deposits of tertiary dentin [9–11]. The pulp chamber may then be significantly smaller and shallower. To avoid iatrogenic damage of the pulpal floor, the clinician is advised to take extra precautions if the radiographic interpretation indicates the presence of hard tissue structures within the pulp chamber. In elderly patients, the pulp may have gone through dystrophic changes, and, similar to pulp necrosis, no bleeding may indicate entering the pulp chamber [12]. After initial opening, the clinician should carefully extend the access cavity by removing the roof of the pulp chamber, allowing for close inspection of the pulp floor and search for the root canal orifices (Box 5.2) [13].

Recently, there has been a debate whether root canal access should follow established guidelines or if it should be part of a minimally invasive procedure. Established guidelines

Box 5.2. Locating Canal Orifices

Prior to creating an endodontic access it is advised to visualize the exterior outline of the tooth at the cemento-enamel junction. This outline will give an approximate idea of the horizontal dimensions of the pulp chamber. Upon access, the pulp chamber anatomy should be observed to locate canals. Several anatomical landmarks exist that aid in orifice localization.

Developmental lines on the pulp floor connect all canal orifices. Also, color differences can be observed between bright, opaque dentinal walls and the darker, transparent pulpal floor. While some canal entrances are located easily, these anatomical landmarks are particularly important to find calcified canal orifices. One common example is MB2. While removing dentin during the search for MB2, the isthmus itself between MB1 and MB2 appears as one developmental line that terminates at the MB2 orifice.

for access ask for a complete removal of the entire roof of the pulp chamber to allow for straight-line access to all root canals, including the removal of all pulp horns and coronal enlargement (Box 5.3) [14, 15]. Any healthy hard tissue structures should be protected and preserved; however, this can be only to the extent of allowing adequate instrumentation and disinfection of the root canal system. *An appropriate guideline for access cavity preparation is to remove as little dentin as possible but as much as necessary.*

Box 5.3. Straight-Line Access

Straight-line access facilitates easier instrumentation and thus cleaning of the root canal system by eliminating curvatures and canal obstructions. Coronal straight-line access addresses the reduction of coronal curvature portions by relocating orifices into access cavity corners. Canal entrances are translocated using NiTi shaping files (e.g., ProTaper S1/Sx or BioRace 0) or Gates Glidden drills. In case of severely calcified canal entrances, the use of stainless steel K- or Hedström files is recommended prior to rotary instrumentation. With any file, coronal dentin is shaped away from the furcation by cutting in outstroking motions into the direction of cusp associated with the respective root canal (maxillary molars: MB to mesiobuccal, DB to distobuccal, PAL to palatal; mandibular molars: MB to mesiobuccal, ML to mesiolingual, DB to distobuccal, DL to distolingual, but a potentially single D to distobuccal and distolingual). This uprighting procedure is to the extent that the straight canal portions extend down to the mid root level. All pulp horns should be removed during this procedure. Reference points should be chosen depending on which anatomical landmark can be easiest verified with a file in the straightened canal. This does not have to be the corresponding cusp, it could as well be the opposing cusp or a marginal ridge. Coronal straight-line access will allow better radicular access to the apical third of the root canal. Canal straightening leads to shorter length measurements. Final length measurements, both electrometrically or radiographically, should only be undertaken after straight-line access has been achieved to avoid potential apical perforations.

Extreme concepts call for the preservation of dentin, for example access through the pulp horns as the priority goal of endodontic therapy [16], to the extent that tissue and debris remnants, adequate biological instrumentation, and cleaning with activated irrigation solutions are only secondary aims of the therapy. A higher resistance to fracture after static loading of unrestored teeth was demonstrated with minimally invasive access cavity designs versus traditional access cavity designs [17]. However, any reduction of structural strength depends on several factors, access, type of root canal preparation, and restoration [18]. The resulting minimalistic access cavities without removal of the pulp chamber roof contradict the concept of straight-line access to coronal and radicular root canal areas. As a result, apical instrumentation to sizes that are conducive to removing tissue remnants, infected dentin, or bacterial biofilm becomes limited (see Chap. 6).

Only a complete removal of the roof of the pulp chamber will allow a close inspection of all surface areas of the pulp floor, including developmental lines and other anatomical landmarks that allow more predictable identification of root canal orifices. There are several risks involved with an extreme hard tissue saving strategy. First, with an incomplete visual inspection of the pulp chamber and floor, there is no verification that all vital or necrotic tissue remnants or debris were removed completely from all critical “hiding places” such as grooves and pulp horns. Proponents of minimally invasive endodontics claim that irrigation regimen with sodium hypochlorite, EDTA, and perhaps other irrigation solutions and adjunctive devices will have removed debris and tissue remnants from all these structures; however, to date, no clinical study exists that has shown a higher or equal success rate for extreme minimally invasive access approaches. Moreover, limited access may make the complete preparation of far buccal and far lingual canal portions of distal canals in mandibular molars as well as clearly locating supernumerary root canals very difficult. Clinical aberrations from the norm are manifold and may result in canals not being in a location where they are “usually” suspected. Incomplete removal of tooth structure to gain coronal access may mislead the clinician into believing that all canals, according to the “norm,” are found. This may result in not locating canals that are in unusual locations.

5.2.1 Accessing Maxillary First Molars

Most maxillary molars have three roots and four canals (see Chap. 1 in this book). Commonly, there is one distobuccal, one mesiobuccal, and one palatal root. In most situations, the palatal and distobuccal roots have one single canal and the mesiobuccal root two canals. However, there is great variation in morphology [19–24]. The distobuccal or mesiobuccal roots may be fused with the palatal root individually or with each other [25]. Also, many variations exist for the number of roots, root canals, and the root canal system, including isthmuses, fins, and other communications between main canals [26].

In maxillary first molars, the access cavity should follow a rhomboidal outline and should be located towards the mesial half of the tooth (Fig. 5.1). Ideally, the

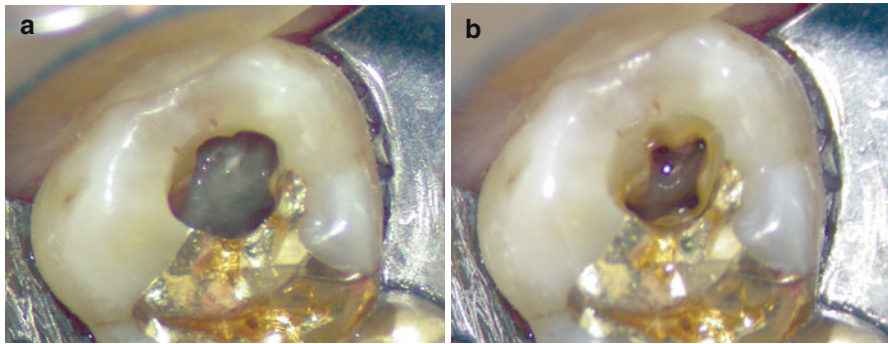


Fig. 5.1 Access cavity in maxillary first molar. (a) Conservative access, allowing straight-line access to main canals. Note cavity extension mesial for MB2 canal. (b) Access cavity and canal orifices filled with sodium hypochlorite. Note change of canal visibility due to light refraction through liquid and the isolation with transparent rubber dam (Case by H. W.)

access cavity should not violate the transversal ridge and should leave approximately 1.5–2.0 mm of the mesial ridge intact, if these are not affected by decay. The palatal canal entrance is the largest and most often the easiest to locate upon access. Its location can be found approximately in the center of the palatal half of the tooth between one-third to one-half the distance from the mesial towards the distal end of the tooth. After locating the palatal orifice, it will be easier to find the mesiobuccal and distobuccal canal entrances. In many situations developmental grooves on the pulpal floor may guide the clinician. After finding the orifices and creating straight-line access, the clinician has to be aware that not only the buccal roots are curved, but also the palatal root most often has a buccal curvature that will not or only hardly be visible on ortho-radial or excentric radiographs. The distobuccal canal usually has a more tear-drop shape orifice and is located slightly distal to the buccal groove. The mesiobuccal canal entrances can vary greatly in shape of the orifices, due to the many variations of the mesiobuccal canal system. As a general guideline, the first mesiobuccal canal entrance (MB1) can be found slightly more buccally than the distobuccal canal entrance just palatal to the mesiobuccal cusp tip. The second mesiobuccal canal entrance (MB2) is most often described to be slightly mesial of an imaginary line connecting MB1 with the palatal canal orifice, approximately 1.5–2.0 mm from the entrance of mb1. Many combinations, however, are possible, including two completely separate canals, one single canal, two orifices with two canals joining, two canals splitting from one orifice, splitting and reuniting, or three separate canals with the third canal being located next to mb1 or mb2 or more disto-palatal [27–32].

Based on differences in study methodology, operator expertise, degree of mineralization, and the classification used MB2 was reported to exist in 19–96% of the cases [28]. According to published studies, the possibility of finding a second mesiobuccal canal increases with the use of magnification and illumination, particularly a dental microscope, as well as the increasing experience of using it [29, 33–37].

Typically, the canal entrance is hidden beneath dentin. This overhanging dentin shelf needs to be removed to detect the orifice with a mesial extension to allow appropriate access to the canal. In many clinical situations for about 1–2 mm the coronal portion of mb2 runs very shallow from distal to mesial before the canal curves towards distal, following the mesiobuccal root (Fig. 5.2).

There are different approaches to gain access to the middle and apical third to avoid iatrogenic complications such as blockage or transportation. Using a long shank #2 round bur or LN bur, one can directly attempt to locate the main portion of the canal from the coronal aspect. Alternatively, the canal path can be carefully modified using a combination of stainless steel Hedström and K-files size #8 and #10 hand instruments or rotary instruments that allow lateral brushing, e.g., ProTaper S1 and Sx or TRUShape Orifice modifiers. Micro-openers #10/0.04 or path or scout files may be of help to clear obstructions. Frequent irrigation is advised to clean debris to avoid blockage of the orifice and the coronal canal portion. The clinician is advised to proceed with caution with the instrumentation of mb2. Not only is it the smallest of all canals in the maxillary first molars, but it also curves, often sharply, towards the mb1 canal if these canals are joining. Abrupt curvatures may pose a great risk for instrument fractures. It is often advisable to complete the instrumentation of mb1 before approaching mb2 to gain a better understanding of the root morphology, leading to an optimal clinical result (Fig. 5.3).

Other counts for the total number of canals were reported, including 5, 6, 7, or 8 main canals, including variations such as the palatal canal splitting in three individual canals [39].

5.2.2 Maxillary Second Molars

Maxillary second molars are generally smaller than the first maxillary molar. Four canals are found less frequently than in first maxillary molars. Although access should follow the same guidelines as for first maxillary molars, it is expected that all root canal orifices are much closer to each other. If four orifices are present, they are frequently found within a diamond shape area or even almost a line connecting the mesiobuccal with the palatal canal. Fused roots are common in second maxillary molars, a fact that accounts for the close proximity of the canal entrances that is often encountered in these teeth.

5.2.3 Mandibular First Molars

Most mandibular first molars typically have two roots with either three or four root canals. Commonly, two root canals are found in the mesial root and one or two canals in the distal root. In order not to miss any canals in the distal root, the access cavity should not be triangular, but rather trapezoid to rectangular in shape, and in most cases be located in the mesial two-thirds of the occlusal surface (Fig. 5.4). Mesiobuccal and mesiolingual canals are found slightly centrally in

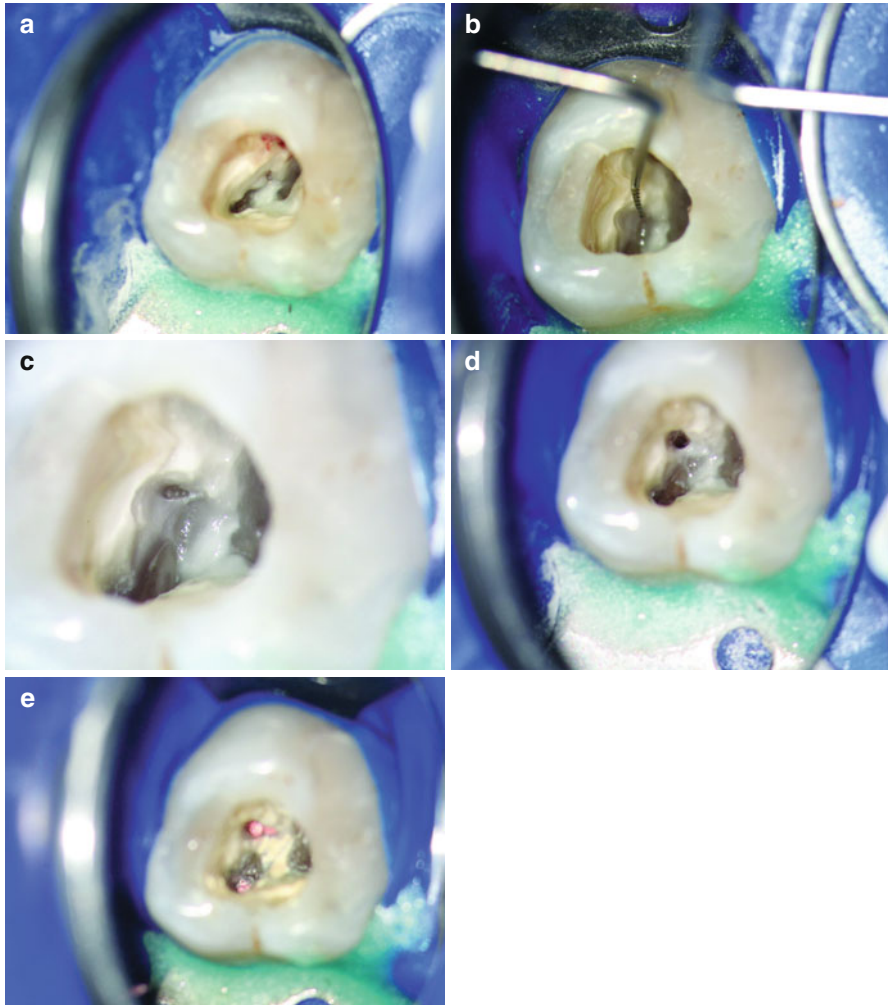


Fig. 5.2 Identification and instrumentation of a calcified MB2 of a first maxillary molar. Access cavity overview with dentin obstructing the canal entrance to MB2 (10× magnification). (b) Canal identification after ultrasonic dentin removal (10×). (c) Initial preparation of MB2 for straight-line access (16×). (d) Completely instrumented MB2 canal prior to root filling (10×). (e) Root fillings in mesiobuccal canals (10×) (Images a, b, and d from Setzer and Kim [38]; with permission)

relation to the mesiobuccal and mesiolingual cusp tips. The distal canal(s) will be found distally to the furcation, respectively distal to the buccal developmental groove. Due to the curvature of the distal root, it is mostly sufficient to limit the access cavity extension in distal direction. Straight-line access will still be possible. If only one distal canal is present, it is located centrally in buccolingual direction. It commonly has a long oval canal cross-section stretching buccolingually.

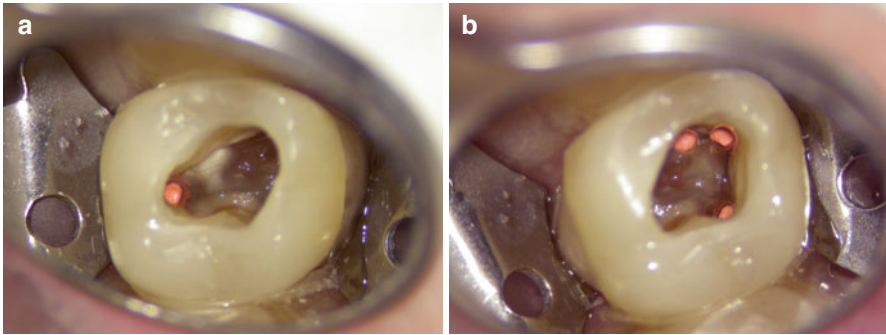


Fig. 5.3 Situation after root canal filling. Straight-line access allowed direct instrumentation of all canals; however, this must not mean complete visibility of all canals. Note color difference between pulp floor (*dark*) and pulp chamber walls (*light*), as well as developmental lines connecting the main canals. (a) Palatal canal. (b) Distobuccal and mesiobuccal canals. Note isolation with transparent rubber dam

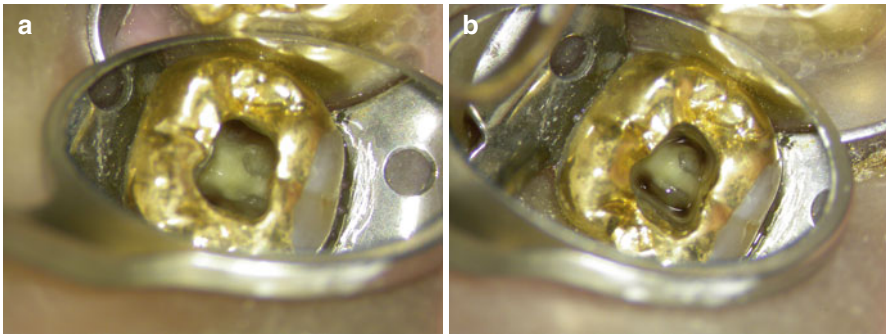


Fig. 5.4 Access cavity in mandibular first molar showing a conservative access through an existing coronal restoration. (a) Access cavity and canal orifices dried. (b) Access cavity and canal orifices filled with sodium hypochlorite. Note change of canal visibility due to light refraction through liquid

Careful examination of both lingual and buccal canal walls will sometimes allow to locate a second distal canal, which may separate off below the level of an oval orifice. If two canals are present in the distal root, they are most likely centered buccally and lingually of the mesiodistal axis. According to the literature, one canal in the distal root is found in about 60% and two canals in about 40% of mandibular first molars; however, one should always take the presence of two canals into consideration (see Chap. 1 in this book). Generally, the developmental grooves help to identify the root canal orifices. Mesiobuccal and mesiolingual are often connected by a developmental groove, which may extend into a partial or complete isthmus between the canals. In approximately 5% of the clinical cases a third mesial canal or mid-mesial canal, between the mesiobuccal and mesiolingual canals, has been

reported. Isthmus structures between the mesial canals should be carefully instrumented, to allow for the removal of vital or necrotic tissue remnants and to disinfect these ramifications. The opening and cleaning of the isthmus will also allow to easier identify any mid-mesial canals, which may only become accessible at a deeper level. Four canals are rarely present in the mesial root.

A three-rooted configuration of the mandibular first molar is found particularly in East or Southeast Asian populations; a second distal (distolingual) root is reported in 5–15 % of clinical cases (“radix entomolaris”) [30–37, 39–41]. In these situations, the main distal canal in the distobuccal root is found closer to the mesiodistal midline, whereas the distolingual canal entrance is found distinctively closer towards the distolingual cusp. For these situations the access cavity must be extended in the direction of the distolingual canal to allow for an almost vertical access to the canal. This is necessitated by the sharp buccal curvatures that are often found in combination with a distinctive apical kink in these separate distolingual roots. This curvature is often invisible on an ortho-radial projection. A third, distolingual root is often considerably shorter than the mesial or distobuccal roots.

5.2.4 Mandibular Second Molars

Similar to the mandibular first molars in anatomy, two roots with three or four root canals are common in the second mandibular molar, with about 80 % for three and 20 % for four root canals. However, there are greater variations in the root and root canal morphology than in first mandibular molars. Pulp chamber and canal entrances are smaller than in first mandibular molars. Roots are more often fused. Mesio Buccal and mesio lingual canal entrances may be in very close proximity, sometimes the root canal orifices appear as one large central canal entrance of oval shape. The clinician must carefully inspect these orifices. In a number of cases, both mesial canals split immediately below the pulp floor in their mesiolingual and mesiobuccal directions. Straight-line access must be created towards buccal/mesiobuccal for the mesiobuccal canal and towards lingual/mesiolingual for the mesiolingual canal, to avoid blockage of the canals by debris during access. The techniques are similar to the relocation and instrumentation of mesiobuccal and distobuccal canals that are in close proximity to each other in maxillary second molars.

A complicated morphology variation is the C-shape root and root canal system configuration [42, 43]. When cross-sectioned through the single C-shaped root in a horizontal plane, the root will appear to have the form of a letter “C”, with the open portion of the C mostly facing lingually.

Common radiographic misinterpretations are the anticipation of one root with one large central canal or two fused roots. However, what appears to be one “canal” is the radiographic appearance of the surface of the root folded into a C-shape. The canals in C-shape molars may have very small diameters and can be radiographically masked by hard tissue structure. While radiographically a C-shape tooth may appear as having one root with a large central canal, two root tips mesial and distal

to the “canal” can often be seen. Second mandibular molars with one root and one real central canal should demonstrate the radiographic appearance of a single root tip. In C-shape molars the variations of anatomy are manifold. There can be one canal system connected as one single C-shape web, or as partial C-shape canal morphology with main canals that are completely or partially connected by isthmuses. These types have been referred to as semicolon-types, with the isolated canal located at the mesiolingual aspect.

Upon access of these teeth, the clinician must exert great caution not to perforate outside the C-shape configuration. Depending on the extent of the C-shape area and the existence of main canals, various techniques may be required to gain access and to instrument the root canal system. If main canals are present, their instrumentation is advised first. The cleaning of the connecting isthmuses should follow as a second step. This will allow an easier management and will reduce the risk of iatrogenic complications. If only a thin isthmus structure exists and the C-shape is complete, it will need to be carefully instrumented from coronal to apical. This can be done initially by using small long-shank round burs, then followed by LN-burs and ultrasonic instrumentation. It will require direct visibility of the area to be instrumented to prevent perforations or transportations.

5.2.5 Third Molars

Both maxillary and mandibular third molars may present with great variability in root and root canal system anatomy. No simple general guidelines can be given. Roots are often completely or partially fused and may number from one to four or even more. Root lengths can be very variable, even within the same tooth. Third molar root canal therapy may be limited by the access to the tooth, not only by tooth inclinations in mesiodistal or buccolingual directions, but also due to rotations, soft tissue impactions, or limited mouth opening by the patient. Canals may be difficult to negotiate due to size or abrupt curvatures. If limited opening is encountered, a children’s head handpiece and endodontic handpieces with reduced head size can provide better access and correct alignment of the bur. Pre-bendable rotary nickel-titanium files manufactured from controlled memory may be another aid for easier access to these root canals.

5.3 Access Through Existing Full Coverage Restorations

Certain clinical situations may prohibit the removal of an existing coronal restoration, which include the following:

- Irreversible pulpitis after a newly cemented crown or fixed partial denture
- A crown restoration that anchors a removable partial denture, such as survey crowns or telescopic crowns

- Large restorations that would have to be completely replaced after the restoration on the tooth in need for endodontic treatment is removed
- Teeth with questionable restorability after the coronal restoration is removed

Whereas for newly cemented restorations the remaining decay should not be an issue, both practitioner and patient must be aware that any existing restoration may not allow a complete inspection of the underlying hard tissue structure. Prior to any access through an existing coronal restoration, it must be checked for sufficient margins by bite-wing radiographs and clinical inspection. If any existing decay cannot be removed prior or during the endodontic procedure, the restoration must be removed not to compromise the treatment. Access through an existing full coverage restoration has become easier by the availability of magnification and illumination provided by the dental microscope (Fig. 5.4). However, the clinician is still advised to exert great caution, since existing topographical landmarks, such as cusps, grooves, and ridges are removed by full coverage restorations. A close inspection of the preoperative radiographs and the roots at the crown margins will allow a better understanding of potential tooth rotations or inclinations to prevent iatrogenic complications such as perforations (Box 5.4).

Box 5.4. Molar Access Checklist

- Establish proper diagnosis, including sufficient radiographs. Do not rush procedure.
- Using all available information, form a clear mental picture of the steps necessary for proper access, potential complications, and precautions.
- Provide proper anesthesia and rubber dam isolation. Disinfect working field prior to endodontic access.
- Remove all decay. If possible, do not leave existing restorations. Avoid iatrogenic contamination.
- Verify circumference of CEJ. The outline of typical pulp chambers bears close resemblance.
- Access pulp chamber carefully. To avoid iatrogenic errors, refrain from deep drilling without verification of pulp chamber location.
- Enlarge pulp chamber circumferentially until good visualization is achieved and all pulp chamber content is exposed. Do not unnecessarily weaken tooth structure.
- Locate canal orifices by observing all available landmarks using enhanced magnification and illumination, and anticipate unusual anatomy. Do not rely on norms.
- After canal localization, provide straight-line access to individual canals, only then establish working length.
- Do not force instruments into canals to avoid iatrogenic errors.

References

1. Nattress BR, Martin DM. Predictability of radiographic diagnosis of variations in root canal anatomy in mandibular incisor and premolar teeth. *Int Endod J.* 1991;24:58–62.
2. Pineda F, Kuttler Y. Mesiodistal and buccolingual roentgenographic investigation of 7,275 root canals. *Oral Surg Oral Med Oral Pathol Oral Radiol Endod.* 1972;33:101–10.
3. Schäch E, Diez C, Hoppe W, Tepel J. Roentgenographic investigation of frequency and degree of canal curvatures in human permanent teeth. *J Endod.* 2002;28:211–6.
4. Slowey RR. Radiographic aids in the detection of extra root canals. *Oral Surg Oral Med Oral Pathol.* 1974;37:762–72.
5. Benye B. Identification of dental root canals and their medial line from micro-CT and cone-beam CT records. *Biomed Eng Online.* 2012;11:81.
6. Abbott PV. Assessing restored teeth with pulp and periapical diseases for the presence of cracks, caries and marginal breakdown. *Aust Dent J.* 2004;49:33–9.
7. Pecora JD, Woelfel JB, Sousa Neto MD. Morphologic study of the maxillary molars. 1. External anatomy. *Braz Dent J.* 1991;2:45–50.
8. Gani O, Visvisian C. Apical canal diameter in the first upper molar at various ages. *J Endod.* 1999;25:689–91:68.
9. Foreman PC, Soames JV. Structure and composition of tubular and non-tubular deposits in root canal systems of human permanent teeth. *Int Endod J.* 1988;21:27–36.
10. Le May O, Kaqueler JC. Scanning electron microscopic study of pulp stones in human permanent teeth. *Scanning Microsc.* 1991;5:257–67.
11. Smith AJ. Ch 3. Dentine formation and repair. In: Hargreaves KM, Goodis HE, editors. *Seltzer and Bender's dental pulp.* Berlin: Quintessence; 2002.
12. Allen PF, Whitworth JM. Endodontic considerations in the elderly. *Gerodontology.* 2004;21:185–94.
13. Acosta Vigouroux SA, Trugeda Bosaans SA. Anatomy of the pulp chamber floor of the permanent maxillary first molar. *J Endod.* 1978;4:214–9.
14. Leeb J. Canal orifice enlargement as related to biomechanical preparation. *J Endod.* 1983;9:463–70.
15. Weller RN, Hartwell GR. The impact of improved access and searching techniques on detection of the mesiolingual canal in maxillary molars. *J Endod.* 1989;15:82–3.
16. Clark D, Khademi J. Modern molar endodontic access and directed dentin conservation. *Dent Clin North Am.* 2010;54:249–73.
17. Krishan R, Paqué F, Ossareh A, Kishen A, Dao T, Friedman S. Impacts of conservative endodontic cavity on root canal instrumentation efficacy and resistance to fracture assessed in incisors, premolars, and molars. *J Endod.* 2014;40:1160–6.
18. Bonessio N, Arias A, Lomiento G, Peters OA. Effect of root canal treatment procedures with a novel rotary nickel titanium instrument (TRUShape) on stress in mandibular molars: a comparative finite element analysis. *Odontology.* 2016. [Epub ahead of print] PubMed PMID: 26847080.
19. Barbizam JV, Ribeiro RG, Tanomaru Filho M. Unusual anatomy of permanent maxillary molars. *J Endod.* 2004;30:668–71.
20. Caliskan MK, Pehlivan Y, Sepetcioglu F, Turkun M, Tuncer SS. Root canal morphology of human permanent teeth in a Turkish population. *J Endod.* 1995;21:200–21.
21. al Shalabi RM, Omer OE, Glennon J, Jennings M, Claffey NM. Root canal anatomy of maxillary first and second permanent molars. *Int Endod J.* 2000;33:405–14.
22. Skidmore AE, Bjorndal AM. Root canal anatomy of the human mandibular first molar. *Oral Surg Oral Med Oral Pathol Oral Radiol Endod.* 1971;32:778–84.
23. Vertucci FJ. Root canal anatomy of the human permanent teeth. *Oral Surg Oral Med Oral Pathol.* 1984;58:589–99.

24. Weine FS, Healey HJ, Gerstein H, Evanson L. Canal configuration in the mesiobuccal root of the maxillary first molar and its endodontic significance. *Oral Surg Oral Med Oral Pathol.* 1969;28:419–25.
25. Ross IF, Evanchik PA. Root fusion in molars: incidence and sex linkage. *J Periodontol.* 1981;52:663–7.
26. Carlsen O, Alexandersen V. Radix mesiolingualis and radix distolingualis in a collection of permanent maxillary molars. *Acta Odontol Scand.* 2000;58:229–36.
27. Christie WH. Canal configuration in the mesiobuccal root of the maxillary first molar: a clinical study. *J Endod.* 1994;20:135–7.
28. Cleghorn BM, Christie WH, Dong CC. Root and root canal morphology of the human permanent maxillary first molar: a literature review. *J Endod.* 2006;32:813–21.
29. Fogel HM, Peikoff MD, Christie WH. Canal configuration in the mesiobuccal root of the maxillary first molar: a clinical study. *J Endod.* 1994;20:135–7.
30. Hartwell G, Bellizzi R. Clinical investigation of in vivo endodontically treated mandibular and maxillary molars. *J Endod.* 1982;8:555–8.
31. Neaverth EJ, Kotler LM, Kaltenbach RF. Clinical investigation (in vivo) of endodontically treated maxillary first molars. *J Endod.* 1987;13:506–12.
32. Nosonowitz DM, Brenner MR. The major canals of the mesiobuccal root of the maxillary 1st and 2nd molars. *N Y J Dent.* 1973;43:12–5.
33. Sempira HN, Hartwell GR. Frequency of second mesiobuccal canals in maxillary molars as determined by use of an operating microscope: a clinical study. *J Endod.* 2000;26:673–4.
34. Buhrey LJ, Barrows MJ, BeGole EA, Wenckus CS. Effect of magnification on locating the MB2 canal in maxillary molars. *J Endod.* 2002;28:324, 28:3.
35. Stropko JJ. Canal morphology of maxillary molars: clinical observations of canal configurations. *J Endod.* 1999;25:446–50.
36. Wolcott J, Ishley D, Kennedy W, Johnson S, Minnich S. Clinical investigation of second mesiobuccal canals in endodontically treated and retreated maxillary molars. *J Endod.* 2002;28:477–9.
37. Yoshioka T, Kobayashi C, Suda H. Detection rate of root canal entrances with a microscope. *J Endod.* 2002;28:452–3.
38. Setzer FC, Kim S. Comparison of long-term survival of implants and endodontically treated teeth. *J Dent Res.* 2014;93:19–26.
39. Maggiore F, Jou YT, Kim S. A six-canal maxillary first molar: case report. *Int Endod J.* 2002;35:486–91.
40. Gu Y, Lu Q, Wang P, Ni L. Root canal morphology of permanent three-rooted mandibular first molars: part II – measurement of root canal curvatures. *J Endod.* 2010;36:1341–6.
41. Jerome CE, Hanlon Jr RJ. Dental anatomical anomalies in Asians and Pacific Islanders. *J Calif Dent Assoc.* 2007;35:631–5.
42. Jung HJ, Lee SS, Huh KH, Yi WJ, Heo MS, Choi SC. Predicting the configuration of a C-shaped canal system from panoramic radiographs. *Oral Surg Oral Med Oral Pathol Oral Radiol Endod.* 2010;109:e37–41.
43. Manning SA. Root canal anatomy of mandibular second molars. Part II C shaped canals. *Int Endod J.* 1990;23:40–5.

Shaping, Disinfection, and Obturation for Molars

6

Ove A. Peters and Ana Arias

Abstract

Shaping the canal system to promote disinfection and obturation is the cornerstone of molar endodontics. Clinical outcomes, both long and short term, hinge on the technical quality and attention to detail invested into this step. This chapter summarizes currently understood best practices, independent from specific instruments or technologies. A historically proved lead principle here, as in medicine in general, is “do not harm.”

Building on other chapters in this book, the rationale and literature supporting the must-haves and must-dos, techniques to fulfill the objectives for pertinent steps of shaping, cleaning, and filling during root canal treatment are described.

Guiding Reference

Ng Y-L, Mann V, Gulabivala K. A prospective study of the factors affecting outcomes of nonsurgical root canal treatment: part 1: periapical health. *Int Endod J*. 2011;44:583–609.

This study on a large number of root canal treatments provides insight into pre- and perioperative factors associated with the successful management of apical periodontitis, both in initial treatment and nonsurgical retreatments. Existing microbial contamination reduces the probability of success and several perioperative factors appear to have only mild impact. Certain clinical steps, such as achieving patency and avoiding overfills and other significant procedural errors, appeared to be associated with higher

O.A. Peters, DMD, MS, PhD (✉)
Department of Endodontics, University of the Pacific, Arthur A. Dugoni School of Dentistry,
155 5th Street, San Francisco, CA 94103, USA
e-mail: opeters@pacific.edu

A. Arias, DMD, MS, PhD
Conservative Dentistry, School of Dentistry, Complutense University, Madrid, Spain

odds for success. Irrigation with chlorhexidine is not beneficial and neither is short fill. In summary, success as determined by the absence of periapical periodontitis was about 83% and 80% for initial treatment and retreatment, respectively. A restoration of good quality significantly increases odds for success.

6.1 Introduction

The aim of this chapter is not to give detailed information of all the devices and instruments that are available to clean, shape, and fill the root canal system, but to illustrate the best practices to achieve the goals of cleaning, shaping, and filling.

The starting point to incorporate such best practices in our routine is to understand what is positive for outcomes and what is negative, using appropriate literature describing clinical data [1, 2] and own experience. Understanding what we are exactly looking for every time that we have a specific file, syringe, plugger, or tapered gutta-percha in our hands will help to achieve the outcome (Fig. 6.1).

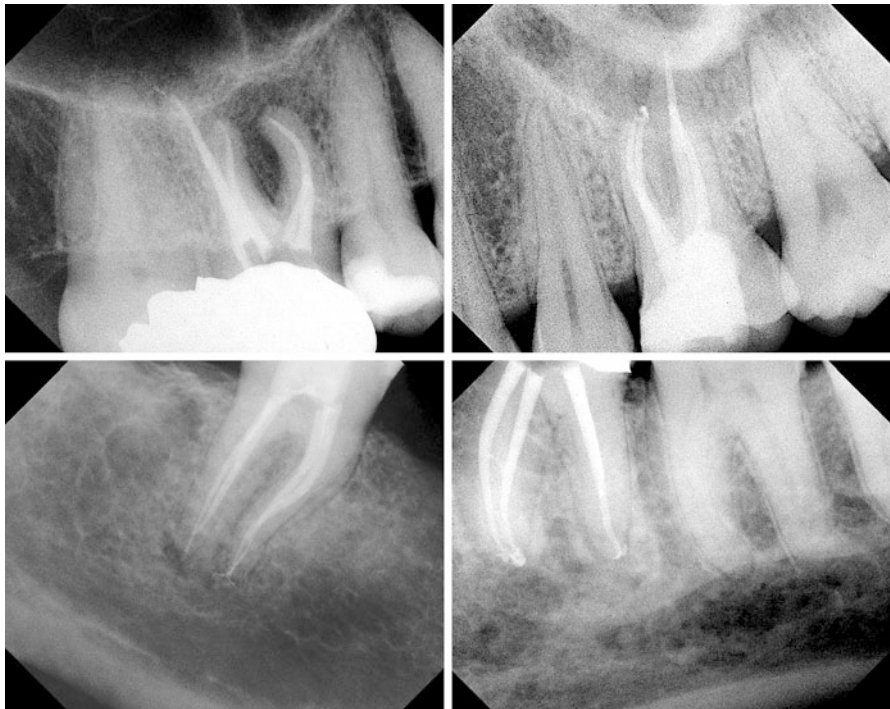

Fig. 6.1 Examples of cases of molar endodontics following the principles discussed in this chapter

Clinical procedures outlined in this chapter are selected to serve their purpose in light of the two goals for endodontic treatment that are to preserve the natural dentition for the lifetime of the patient (“retention”) and to treat or prevent apical periodontitis (“healing”). These are not mutually exclusive goals and both are obviously important. Therefore, clinicians should evaluate any treatment step and clinical guideline for their effect for overall outcomes, in both dimensions mentioned above.

There is solid evidence in the literature that, debriding all canals to working length (WL) [3] or achieving patency [1] is efficient in treating apical periodontitis, while committing overpreparation errors [4] or filling beyond the confines of the root canal system [5] is an obstacle in this process. Appropriate clinical procedures should be selected to produce these outcomes.

Molar endodontics is inherently more difficult than root canal treatment for central maxillary incisors for several reasons, notably the more complex anatomy and the location of the teeth in the patients’ mouth, among other factors. Adherence to a routine sequence and sound general principles will increase clinical outcomes; however, a successful clinician will consider the specific patient’s needs and be prepared for the unusual occurrence. The content of this chapter is divided into three parts: root canal preparation, disinfection, and obturation. These steps depend on each other; for example, canal preparation itself partly removes pulp tissue and microorganisms. Similarly, with contemporary techniques, only a prepared canal can be appropriately obturated. Therefore, the objectives for the chemomechanical preparation of molars are to:

1. Create space for disinfection by chemical means
2. Provide conditions for appropriate obturation
3. Minimize damage to coronal and radicular structures

6.2 Shaping the Molar Root Canal System

Current best practices for root canal shaping promote efficient disinfection and prepare a smooth flowing shape for complete fill of the canal system, while preserving the original canal path and retain structural integrity. A systematic approach to molar root canal preparation contains the steps described below:

1. Analysis of the specific anatomy of the case
2. Canal scouting
3. Coronal modifications
4. Negotiation to patency
5. Determination of working length
6. Glide path preparation
7. Root canal shaping to desired size
8. Gauging the foramen, apical adjustment

6.2.1 Step 1: Analysis of the Specific Anatomy of the Case

Elsewhere in this book, the radiographic appearance of molar root canal systems is described in detail. For successful shaping, it is essential to integrate understanding dental anatomy in general with the specific information gleaned from preoperative radiographs as well as direct intraoral visualization. Taken together with an adequate access cavity (see Chap. 5), the clinician can begin to select a general preparation strategy that serves both the immediate need to disinfect and clean the radicular spaces as well as setting up the tooth for long-term retention.

The analysis of the specific clinical situation in molar endodontics will facilitate shaping of the root canal system and help to avoid mishandling of natural difficulties that could create procedure mishaps, which are then more difficult to manage. Specifically the presence of coronal interferences, possible bifurcations, or lateral topographical exits of the apical foramen should be anticipated before bringing an instrument in a delicate root canal.

A root canal that seems to be straight in a radiograph can have multiple curvatures in three dimensions that cannot be captured in a two-dimensional film. A clinician unaware of this fact is susceptible to errors during length determination and can end with canal transportation during the shaping procedures.

Today's technology, specifically the availability of nickel-titanium (NiTi) rotary instruments, apex locators, the operating microscope, and most recently CBCT, has altered the landscape of endodontics. Sound principles for the use of each technology have been established and should be followed. For example, at the onset of molar root canal treatment, the desired minimal apical preparation size needs to be considered. With current technology, an apical size equivalent to #25 with a minimum taper of .06 facilitates sufficient irrigation with fine irrigation needles, while preventing coronal overpreparation and shaping errors in highly curved canals. Current best evidence suggests that there is no specific apical size that predictably results in complete eradication of bacteria and no specific apical size leads to better outcomes [1]. Consequently, selection of a desired apical size has to be viewed considering multiple factors, such as canal curvature, radicular wall dimension, irrigant flow, and others.

Uniformly outcomes studies described poor results when canal fillings are over-extended, therefore preoperative analysis must include the desired apical end point of all shaping and obturation procedures, as described in detail below.

6.2.2 Step 2: Canal Scouting

Right after the access cavity preparation and before the enlargement of the coronal third, it is recommended to scout the canal with a #10 K-file, not with the intention of negotiating the canal to its full length, but merely to orientate the placement of the rotary instrument that is going to accomplish the coronal flaring of the canal. Care needs to be taken here to stay short of significant binding; this step is designed also to prevent ledges during the coronal flaring that will make the step of negotiation difficult to accomplish.

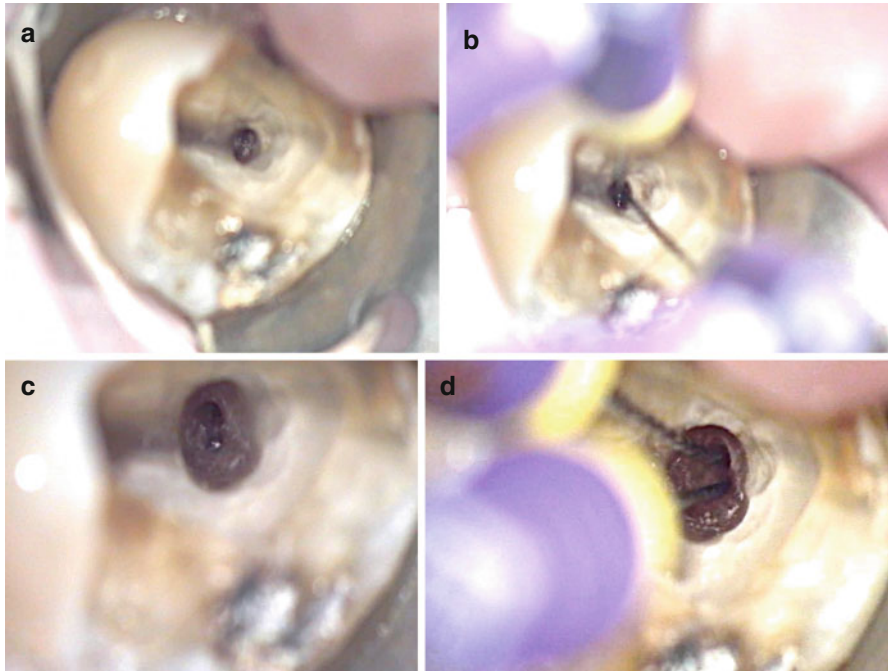


Fig. 6.2 The effect of orifice modification on clinical condition during molar root canal treatment. Coronal flaring allowed the straight advancement of #10 K-files in both MB and DB canals. Note the ability to extend both size #10 K-files deep into the root canals after orifice modification. (a, b) Before coronal flaring. (c, d) After coronal flaring

A typical example for a situation where this step is beneficial are mesiobuccal canals in maxillary molars, specifically the so-called MB2, which often exits the pulp chamber toward the mesial under a dentin shelf and then curves toward the distal (see Chap. 1). The management of this curvature with a Gates-Glidden drill before scouting an MB2 canal in an upper molar is a common practice among inexperienced clinicians that often leads to ledges in a small-diameter root canal and prevents negotiation to length; a previous assessment of the initial direction of the canal; using contemporary NiTi orifice modifiers instead of Gates-Glidden drills will help avoiding this common mishap.

6.2.3 Step 3: Coronal Modifications

Frequently in molar endodontics dentin triangles prevent the introduction of files into the canals in a straight line, which would be clearly identified in the previously described clinical step (Fig. 6.2). These dentin triangles may be removed by enlarging the access (see Chap. 5) but considering the goal of dentin preservation, a more conservative approach is indicated. Coronal flaring was historically emphasized to prevent procedural error or fractures with tapered rotary instruments; the procedure

blends the access cavity into the coronal portion of the root canal while removing coronal dentin obstacles and relocating the orifice of the canal away from the furcation (also known as “danger zone”).

This is in principle a beneficial practice before negotiating the root canal to its entire length when a canal is constricted, mineralized, or difficult to access. It facilitates tactile control of the instruments responsible for negotiation, diminishing the chances of accidents in the apical third by reducing the contact surface of the instrument with the canal walls. On the other hand, it has been demonstrated that overflaring reduces dentinal wall’s thickness [6] and therefore structural strength.

When done well, early coronal flaring, also known as *Orifice Modification*, is beneficial for the following reasons [7, 8]:

1. Easier placement of rotary instruments into orifices
2. Minimal working length changes during canal preparation
3. Earlier access of disinfecting irrigation solutions
4. Easier access of files to the apical third
5. Better tactile control of hand instruments during negotiation

Coronal flaring was historically performed with Gates-Glidden drills. These have largely been superseded by dedicated NiTi rotaries that have comparatively larger tapers and small tips. These instruments are laterally cutting and typically have triangular cross sections. Alternatively, specific burs or ultrasonic tips may be used to create a more direct entry into the coronal root canal third.

Only recently the mechanics of lateral cutting of flaring instruments has been discussed in detail. A study compared the cutting efficacy of radial-landed and triangular cross sections and found that triangular designs were more cutting efficient compared to radial-landed design; furthermore, flexible martensitic alloy cut more rapidly than conventional NiTi alloys [9].

6.2.4 Step 4: Negotiation to Patency

In spite of all the new instruments and devices manufactured in recent years to clean and shape canals, negotiation is all about having a profound knowledge and understanding of root canal anatomy (Fig. 6.3). This is probably one of the key factors during cleaning and shaping. If the clinician cannot negotiate the root canal to the terminus, there are a lot of chances of failure in spite of the use of the most modern and expensive devices to clean and shape. Experience enhances the ability to negotiate root canals with difficult anatomy to the terminus. The canal must be explored to patency, that is, until a small negotiation file (#8 or #10) reaches the periodontal ligament, as indicated by a “zero” reading from an apex locator. Recommendations for best practices during canal negotiation include the use of the following:

1. A viscous chelator during negotiation to prevent pulp tissue blockage
2. An apex locator connected to each instrument to know when the apical foramen is passed
3. Hand movements that preserve apical patency and do not push dentin shavings apically

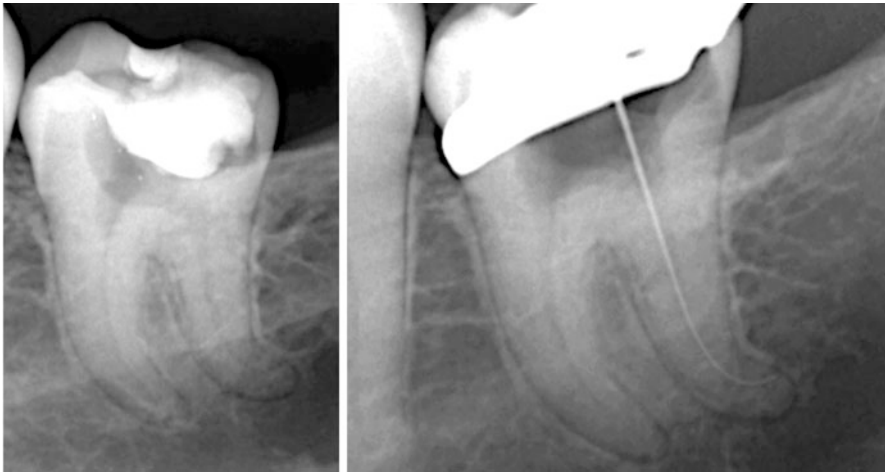


Fig. 6.3 All three root canal thirds, coronal, middle, and apical should be evaluated for possible impediments during canal shaping. This will help clinicians to select best practices for each specific situation. In the case shown, a significant curve in the apical third was managed in a staged approach

4. Application of appropriate curves to the negotiation instruments
5. Selection of the shortest file that can realistically reach patency

The patency concept (Box 6.1) has historically been controversial but accumulating evidence both in vitro [10, 11] and in vivo [1] strongly suggests that keeping canals patent is associated with better outcomes. Maintaining apical patency decreases the chance of postoperative pain [12]; while patency in vitro may be connected to small amounts of irrigant to reach the periodontium, maintaining patency does not appear to increase the chance of irrigation accidents clinically [13] and therefore its benefits appear to outweigh possible risks.

Further advantages of this procedure for achieving patency include:

1. Lower risk of loss of length, reduces canal transportation, and other accidents such as ledges [14]
2. Maintaining the anatomy of the apical constriction [15]
3. Improvement of clinicians' tactile sense during apical shaping [16]
4. Less apical transportation when using a #8 or a #10 K-file to maintain apical patency [17]
5. Better delivery of irrigants to the apical third [18, 19]
6. Reduction of gas bubbles that may prevent the advancement of irrigant to working length [20]

However, the mere presence of NaOCl in the apical root canal third does not guarantee the proper cleaning of the root canal, as it will be discussed later in this chapter. It is well known that sufficient time and surface contact is needed for the dissolution of organic matter that NaOCl provides [21].

Negotiation itself is done with a light touch and rotational back-and-forth file movements, also known as “watch-winding.” Precurving the negotiating

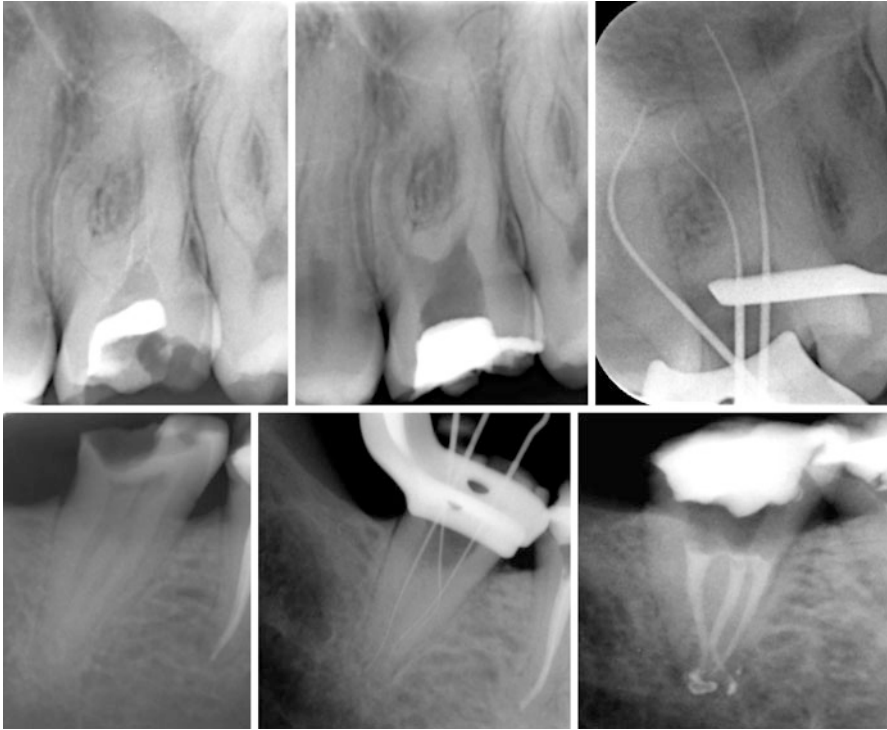


Fig. 6.4 Proper coronal flaring of root canal promotes their negotiation to working length (WL). *Top*, In this case significant curves in MB and DB canals were managed successfully. *Bottom*, In this case the instrument was initially not advancing to WL in the MB canal. Additional orifice modification was needed to allow negotiation and glide path preparation of the canal before taking rotary instruments to WL

instrument at this step is not essential but may be needed in cases of moderate to severe curvature (Fig. 6.4); in case the file stops before the estimated working length (see below), either the file should be precurved to be able to bypass an impediment or more space needs to be created midroot or in the apical third. These two conditions are defined by the tactile feedback the clinician gets from the file; a loose resistance indicates the presence of a ledge or acute curve, while so-called rubbery resistance suggests the presence of a tight canal space or the presence of compacted soft tissue that prevents the file from penetrating deeper into the canal.

West [22] differentiates four specific conditions that require technique modifications:

1. Apical blockage
2. Mismatch between canal curve and instrument
3. Too large file tip
4. Presence of restrictive coronal dentin

All these conditions may be remedied by either changing the negotiation file, its curvature, or by modifying the coronal two-thirds of the canal.

Box 6.1

Apical patency

According to the AAE Glossary, patency is a “technique where the apical portion of the canal is maintained free of debris by recapitulation with a small file through the apical foramen.” It is believed that with patency, less or no blockage by hard or soft debris exists and the canals are free of ledges or acute curves that subsequent files would not be able to negotiate.

A patency file, which may be defined as a small and flexible K-file, can passively be moved through the apical constriction without widening it.

6.2.5 Step 5: Determination of Working Length

Working length (WL) is defined as the distance from a coronal reference point to a point at which canal preparation and obturation should terminate [23]. Both end points included in this definition are important and require attention in this chapter; however, the apical endpoint of the prepared shape in relation to the apical anatomy has been one of the most discussed topics in the endodontic literature.

The apical endpoint of root canal treatment should ideally be at the *apical constriction*, the narrowest diameter of the canal. This point is believed to coincide with the cement-dentinal junction (CDJ), based on histologic sections and ground specimens. However, the position and anatomy of the CDJ varies considerably from tooth to tooth, from root to root, and from wall to wall in each canal. Moreover, the CDJ cannot be located precisely on radiographs. For this reason, some have advocated terminating the preparation in necrotic cases at 0.5 to 1 mm short of the radiographic apex and 1–2 mm short [24, 25] in cases involving irreversible pulpitis, although there is no definitive validation for this strategy at present [26].

Best current evidence suggests that incomplete canal shaping and filling may result in clinically acceptable outcomes in vital cases, that is, not bacterially contaminated canal systems, but in the presence of microorganisms working short may well contribute to persistent or recurrent apical periodontitis [27, 28] or posttreatment disease [29, 30].

Using an electronic apex locator has helped clinicians identify the position of apical foramina more accurately and allow safe canal shaping as close as 0.5 mm to the canal terminus.

Best clinical practice for working length determination and maintenance includes:

1. Estimate the working lengths from properly angulated preoperative radiographs
2. Select an adequate coronal reference point for each root canal

3. Determine WL electronically with an apex locator in a canal that contains an appropriate amount of electrically conducting medium (chelator or ion-containing irrigation solution)
4. Verify electronically determined working lengths with a periapical radiograph [31]

While specific manufacturer guidelines may vary, electronic apex locators work best in molars after drying the pulp chamber with a cotton pellet. A small file is advanced until the apex locator marks apical patency and then pulled back about 0.5 mm to determine the working length of the canal. It is best to start with a #8 or #10 K-file depending on the size of the canal and confirm the length with a flexible #15 file. Apex locator can produce irregular signals in large canals and so it is desirable to check the working length with larger files that come closer to binding at the foramen. The better the adaptation of the tip of the instrument to the foramen, the more accurate the length determination (Fig. 6.4).

6.2.6 Step 6: Glide Path Preparation

It is recommended to explore and shape a root canal at least to a #15 size instrument before the use of a rotary NiTi instrument to full working length [32] to create a *glide path* for the safe advancement of the rotary instrument tip [33]. Such a glide path reduces the contact area between subsequent shaping instruments and the canal wall and therefore the torsional loads induced by shaping rotary instruments [34]. In fact, the presence of a glide path is essential for the predictable use of rotary instruments in canal shaping.

Typically, K-files sizes #10 and #15 are used in watch-winding or balanced-force motion to create and secure the glide path. However, recently NiTi rotary instruments with small tip diameter have been designed specifically to simplify the process of glide path preparation. Due to their limited torsional resistance, these small-diameter rotaries should be used only after a size #10 K-file is placed to working length.

The presence of an appropriate glide path is indicated by the fact that a straight, not precurved size #15 K-file can passively and smoothly travel to working length. This should be tested from 1 to 2 mm off working length, as well as from 5 to 6 mm away.

For long-oval or flat canals, often found in distal roots of mandibular molars, the preparation of two glide paths and ultimately two canal pathways is indicated. These will be located in the far buccal and far lingual aspects of the canal [35]; such a shape promotes canal wall contact, facilitates debridement, and ultimately simplifies obturation.

6.2.7 Step 7: Root Canal Shaping to Desired Size

The process quality of molar root canal treatment has drastically increased since the advent of nickel-titanium instruments, most likely because even in anatomically complex situations, preparation errors are less likely with NiTi files compared to stainless steel instruments [4, 36]. Also, preparation of root canals with ISO hand

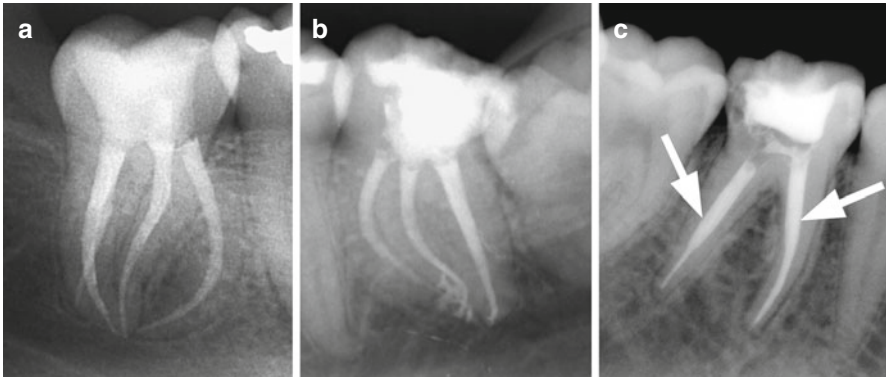


Fig. 6.5 Shapes after NiTi rotary preparation (a, b) and shaping with stainless steel hand files and Gates-Glidden drills (c). Note excessive coronal enlargement (*arrows*)

instruments is tedious and clinicians use to combine them with Gates-Glidden drills and with the step-back technique to increase the canal taper. The resulting shape is overextended in the coronal third debilitating the tooth and making it more prone to subsequent vertical fractures (Fig. 6.5). Shaping with NiTi rotary instruments, the final shape can be more conservative in the coronal third and sufficient in the middle third, enhancing therefore the efficiency of irrigating solutions and obturation. The taper of the last instrument that reaches working length creates a resistance form in the apical millimeters of the root canal that allows a more predictable filling technique than the punctual apical stop created with manual instrumentation (Fig. 6.5).

In order to successfully use NiTi rotaries, clinicians should understand the details of the specific instrument they are using. A discussion of the alloy and specific instrument designs is beyond the scope of this book and the reader is referred to current endodontic textbooks for further information on this topic. Clinicians are further advised to carefully consider the directions of use for the specific instruments they use. In general, no instrumentation should occur in a dry canal; during shaping with NiTi rotaries, good practice dictates always to have a reservoir of sodium hypochlorite, acting as a lubricant, in the access cavity and the root canal system.

Increasing instrument taper simplified the creation of an appropriate shape with the use of fewer instruments and in a shorter period of time. In vitro data clearly demonstrates that NiTi rotaries are superior to stainless steel files in that they create less preparation errors and this fact translates to better conditions for the treatment of apical periodontitis [4, 36], specifically for molar root canal treatment.

Selective removal of dentin in the coronal canal portion retains more structural strength [37]. Clinicians should consider the use of instruments with a limited maximum flute diameter (MFD), which limit preparation sizes to a conservative dimension. Considering that conditions such as root fracture and nonrestorable carious defects are most frequently cited for the reason to extract root canal-treated teeth [38, 39], retaining structural integrity after completion of root canal treatment determines potential longevity (Fig. 6.5).

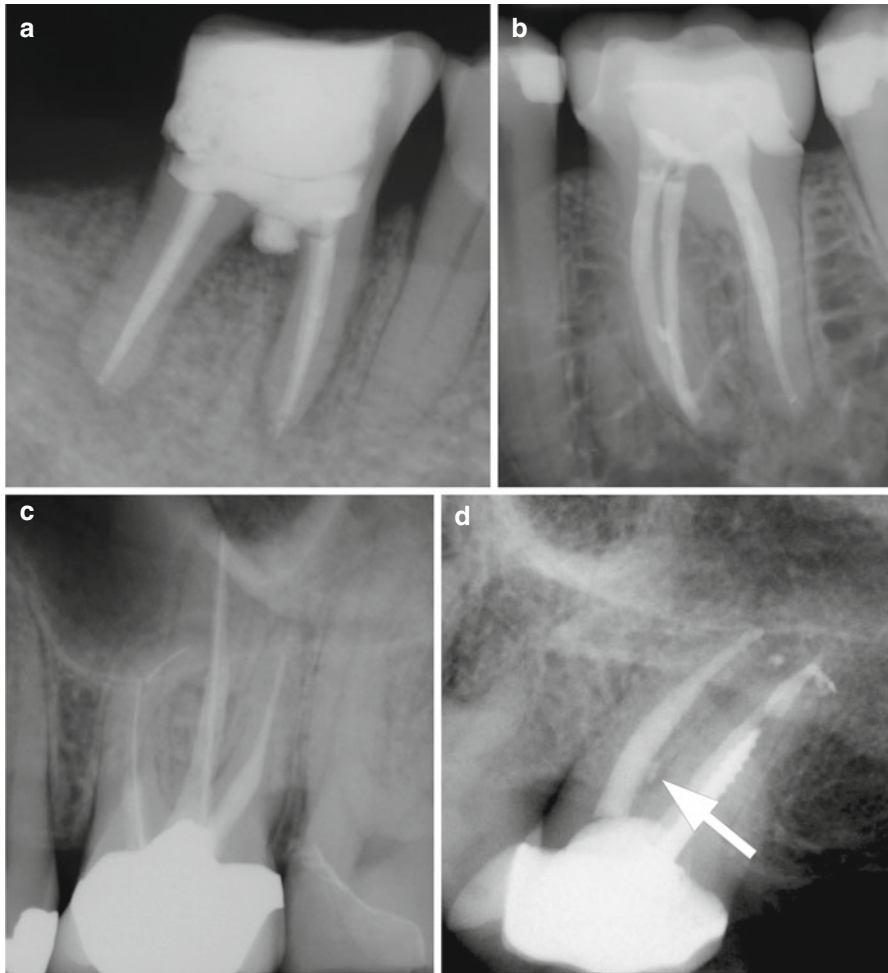


Fig. 6.6 Improper canal shaping may lead to overt preparation errors such as perforation (a), instrument fracture (b), ledge formation (c), and strip perforation (d, see arrow)

6.2.8 Step 8: Gauging the Foramen, Apical Adjustment

The steps outlined above predictably create well-shaped canals; however, there are certain procedural errors that complicate molar endodontics. Ledges and canal blockage, as well as instrument fracture, are such undesirable outcomes (Fig. 6.6).

The best way to deal with instrument fracture is prevention (Box 6.2) [40]. Working under the operating microscope, using specific ultrasonic tips, and specifically designed armamentarium will help to retrieve broken instruments from the root canal; however, this procedure is often associated with an extensive removal of dentin. In case of a failing endodontic treatment, nonsurgical or surgical procedures may be indicated (see Chaps. 9 and 10).

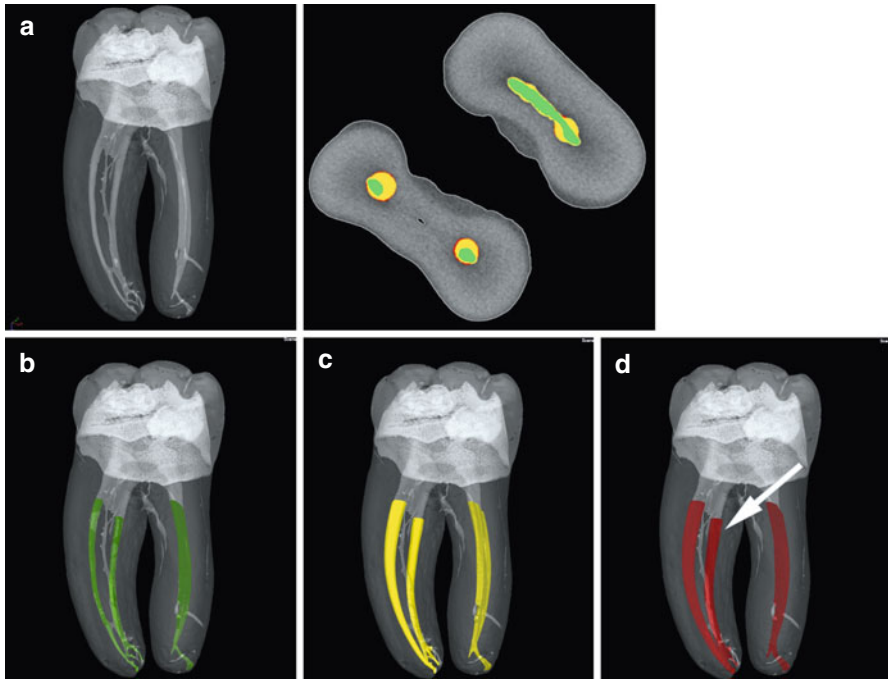


Fig. 6.7 Micro-computed tomography images of molar root canal systems (a). Separate canals are shown before shaping (b, green) and at an apical sizes #20 (c, yellow) and #30 (d, red). Note the different shapes coronally with preservation of coronal structure evident in the canal prepared with TRUShape (Dentsply Tulsa Dental, arrow). Inset shows a cross section in the coronal third with the different stages of canal preparation indicated by colors with the TRUShape-prepared canal to the right in the mesial root, corresponding to images (b–d)

Every root canal system is unique and therefore desired final canal sizes will vary (see Chap. 1 in this book). Best clinical practice is, after creating an overall tapered shape, to determine apical canal sizes by gently probing to working length with hand files. For example, after achieving an apical size #25, a set of flexible K-files sizes #25, 30, and 35 is used, with rubber stoppers preset to working length. If the canal is fully prepared at size #25, that size K-file will stop just at WL, while the two larger files will stay progressively short of WL. If larger sizes go to WL, additional canal shaping is indicated to facilitate root canal debridement and filling. After final adjustment of the apical preparation, patency is again verified with a precurved size #10 K-file that is gently rotated to break up accumulated dentin debris and probe accessory anatomy. Figure 6.7 illustrates progressive enlargement of molar root canals to appropriate apical sizes and tapers without overpreparing the coronal root canal third or excessively thinning radicular walls. Tactile verification, using hand files, of the apical preparation size and a gradually increasing taper is mandatory to ensure that so-called tug-back occurs in the appropriate place, that is, apically, to avoid the overextension of gutta-percha during filling (see below).

Box 6.2

Recommendations to avoid NiTi rotary instruments fracture are as follows:

1. Choose the right strategy and instruments depending on the case.
2. Understand the characteristics and limitations of the selected instrument.
3. Avoid cyclic fatigue by reducing instrument diameter and usage time around sharp curves.
4. Avoid torsional stress with a correct glide path preparation.
5. Using appropriate settings for rotational speed, torque, and motion is mandatory.
6. Use gauzes to clean the debris that loads the flutes and reirrigate the canals frequently.

6.3 Debridement of the Molar Root Canal System

Despite substantial improvements in endodontic technology in recent years, the outcome of root canal treatments remain substantially similar, likely because of the difficulty in microbial eradication inside the challenging root canal anatomy [1]. This explains why the success rate of a root canal treatment in a tooth with a vital pulp is higher than in a tooth diagnosed with necrotic pulp and periradicular pathosis [1].

Microorganisms that establish themselves in the root canal space are the cause for apical periodontitis. Therefore removal of these causative agents, and organic material that can support their growth, is essential for treatment of disease. However, tooth anatomy and morphology are significant impediments preventing a complete removal of intracanal microorganisms. Canal debridement is done both during mechanical canal preparation and through the application of irrigation solution and medicaments, in conjunction with mechanical preparation as described before.

An ongoing debate exists regarding final apical sizes. Canal size impacts the ability to advance the needle of an irrigation syringe deeper into the root canal, which in turn is relevant for the ability to deposit antimicrobial solution to the apical canal portion. However, there are obvious physical limits to the enlargements of small curved canals of molar teeth. Clearly, larger canal shapes will not result in complete circumferential canal preparation [41]. Indeed, certain aberrations, like lateral and accessory canals, canal curvatures, canal wall irregularities, fins, cul-de-sacs, and isthmuses, make total debridement virtually impossible. Therefore, a realistic objective of cleaning is to significantly reduce the irrigants more, than totally eliminate them.

Current best practices suggest to use small-diameter side-vented irrigation needle; a final canal size and taper that allow that needle tip to be close to WL is appropriate. Shaping to larger sizes may lead to dentin shavings compacted into canal portions that then become inaccessible for irrigation solution.

A systematic approach to molar root canal disinfection contains these following steps:

1. Achieve an appropriate apical size
2. Select efficient antimicrobial solutions and medicaments

3. Maintain irrigant in extended contact with radicular walls
4. Perform activated irrigation
5. Manage smear layer
6. Consider accessory anatomy

6.3.1 Step 1: Achieve an Appropriate Apical Size

Canal preparation, while by itself not sufficient for debridement, significantly reduces intracanal microorganism. No specific size has been shown to be associated with better outcomes, however diameters for irrigation needles and devices suggest an apical size #25 or #30 with at least an .06 taper to be the minimum enlargement that permits placement of a small irrigation needle 1–2 mm short of WL. In vitro studies demonstrate that only very small volumes of irrigant will travel to the apical canal part beyond the needle tip [42], therefore canal preparation through a reservoir of irrigant and frequent turnover is recommended. During rinsing, the needle, loose in the canal, should be moved apical and coronally with constant and slight movements; such movement produces agitation and prevents binding of the needle, that way avoiding extrusion of toxic solution beyond the apex.

The two factors that have been directly correlated with the efficiency of irrigation are the irrigant solution and the delivery system [43]. Therefore, after choosing the correct irrigants for disinfection and smear layer management, attention should be paid to its delivery and activation. The effectiveness of root canal irrigation in terms of debris removal and eradication of bacteria depends on several factors: penetration depth and diameter of the needle, irrigation pressure, viscosity of the irrigant, velocity of the irrigant at the tip of the needle, and type and orientation of the needle bevel. The size and length of the irrigation needle must be related to root canal dimensions for an effective irrigation. Narrow needles require more pressure onto the plunger and extrude the irrigant with higher velocity than large needle sizes, which deliver greater amounts of irrigants but cannot be introduced very deep; however, irrigation tips with external diameters of 0.32 mm (30 gauge) are available and needed in small canals.

6.3.2 Step 2: Select Efficient Antimicrobial Solutions and Medicaments

Solutions used in root canal treatment should be highly efficient against microorganisms in their planktonic state and in biofilms, inactivate endotoxin, be nontoxic when they come in contact with vital tissues, and not cause anaphylactic reactions [44]. Irrigation strategies aim to dissolve both organic and inorganic tissue. Best practice in endodontics is to use sodium hypochlorite (NaOCl) as the main irrigant [45]. Reported advantages of NaOCl, also known as bleach, include the ability of the solution to dissolve vital [46] and necrotic tissue [47], the antimicrobial action of the solution [48], and the lubricating action [49]. In addition, it is inexpensive and readily available [50]. There is no defined ideal concentration of NaOCl, but

concentrations ranging from 0.5 to 6% have been recommended. As an amount of free chlorine determines the action of the irrigant, any decrease in the concentration should be compensated with an increase in the volume.

The use of other antimicrobials, such as chlorhexidine (CHX) or hydrogen peroxide, has in clinical studies not convincingly been associated with better outcomes [1]. It should be considered that irrigants interact chemically with each other and also with dentin substrate. For example, the combination of NaOCl and CHX causes color changes and formation of a possibly toxic precipitate [51].

6.3.3 Step 3: Maintain Irrigant in Extended Contact with Radicular Walls

Considering the complexity of the root canal system and the inability to completely prepare the radicular walls by mechanical means, good clinical practice suggests to bring sodium hypochlorite in contact with the canal wall for as long as feasible. A minimum contact time of up to 40 min has been discussed [52]; such long times require that bleach is available to be moved deep into the canal system and to be replenished regularly. Therefore it is recommended to instrument through a reservoir of bleach whenever possible.

6.3.4 Step 4: Perform Activated Irrigation

Irrigant solutions may be delivered passively/statically or combined with the use of some instrument or devices for its activation or agitation [53]. While a limitation in the penetration and efficacy of irrigants within the root canal system when using traditional positive passive irrigation has been demonstrated [54], the agitation techniques may help the irrigating solution to reach the apical third improving the cleaning efficiency of the irrigating solution by reaching irregularities in the root canal system (Fig. 6.8). Most of the currently used agitation techniques [53], ultrasonics [55], sonic devices, laser-assisted irrigation [56], and apical negative-pressure irrigation are used to promote apical penetration of irrigation solution.

The EndoActivator System (a device containing noncutting polymer tips in a subsonic handpiece) provides sonically activated irrigation. The main mechanism of so-called passive ultrasonic irrigation appears to be acoustic streaming that occurs close to the instrument. The difference between sonic and ultrasonic activation mainly lies in the amplitude of the oscillating movements that varies from 1500 to 6000 Hz in sonic devices to vibrations greater than 20,000 Hz in ultrasonic devices. Another approach to afford better access of irrigating solution is the so-called negative-pressure irrigation where a fine needle connected to a dental unit's suction device is placed inside the root canal and transports the solution deposited in the pulp chamber apically.

A new erbium laser technique, photon-induced photoacoustic streaming (PIPS), advocates to place the tip in the access cavity without advancing in the root canal [57]. Initial *ex vivo* experimental data for this technique is encouraging [56].




Fig. 6.8 Sequential enlargement of a simulated root canal in a plastic block promotes deeper penetration of irrigation solution. Images show determination of working length (a), initial irrigation with a red dye using a 30 Gauge irrigation needle (b), and irrigation after preparation to working length with sizes #15.04 (c), 25.04 (d), and 35.04 (e) (Courtesy Dr. F. Paqu )

The *Self-adjusting File* (Redent Nova, Ra'anana, Israel) is a hollow endodontic file, and hence may be also considered an irrigation device since a continuous irrigation is performed while shaping the canal. A continuous flow of fresh irrigant eliminates the debris generated by the use of the file while the canal is being disinfected. At the same time the main canal is circumferentially prepared [58].

More recently, *Gentlewave* (Sonendo, Laguna Hills CA, USA) was commercialized as a cleaning device that only requires pulp chamber access. It promises complete debridement without any canal instrumentation at all of the root canal system and is currently tested clinically with promising results [59].




Fig. 6.9 Scanning electron micrograph of a section of root canal wall. The areas of the radicular wall that was instrumented and had smear layer removed (*left*) is clearly visible compared to an area that was not mechanically instrumented, as indicated by so-called calcospherites of the mineralization front

6.3.5 Step 4: Manage Smear Layer

Smear layer is the surface film of debris produced during the instrumentation of the root canal system that consists of dentin particles, remnants of vital and necrotic pulp tissue, bacterial components, and retained irrigant [23] and is deposited on the radicular canal wall, producing an amorphous and irregular layer.

The advantages and disadvantages of the smear layer removal remain controversial; however, evidence generally supports removing the smear layer prior to obturation [60, 61]. The maintenance of the smear layer predisposes to leakage due to the inhibition of the direct contact between the sealer and the canal walls and its further disintegration by acids and enzymes that are produced by viable bacteria left in the tubules or that enter via coronal leakage [62]. Moreover, the presence of organic debris in the smear layer might constitute a substrate for bacterial growth and viable microorganisms present in the dentinal tubules may use the smear layer as a substrate for sustained growth. The presence of a smear layer may also interfere with the action and effectiveness of root canal irrigants and interappointment disinfectants [63].

On the other hand, if smear layer is removed (Fig. 6.9), the likelihood for coronal and apical leakage are reduced [60, 64] due to the better adaption of the filling materials to the canal wall and to the proper adhesion of sealers to dentin and tubular penetration [65, 66].

Ethylenediamine tetraacetic acid (EDTA) [67] is the most frequently used irrigant for smear layer removal (Fig. 6.6) because it is able to chelate and dissolve its mineralized content, although the action has been demonstrated to be more effective in the coronal and middle thirds of the canal and diminished in the apical third [67] due to the narrower canal size or anatomic variations such as irregular or sclerotic tubules [68]. Irrigation with 17% EDTA for 1 min followed by a final rinse with NaOCl [69] or saline is a recommended method. However, alternating both irrigants or using EDTA-based lubricants during the shaping procedure seems

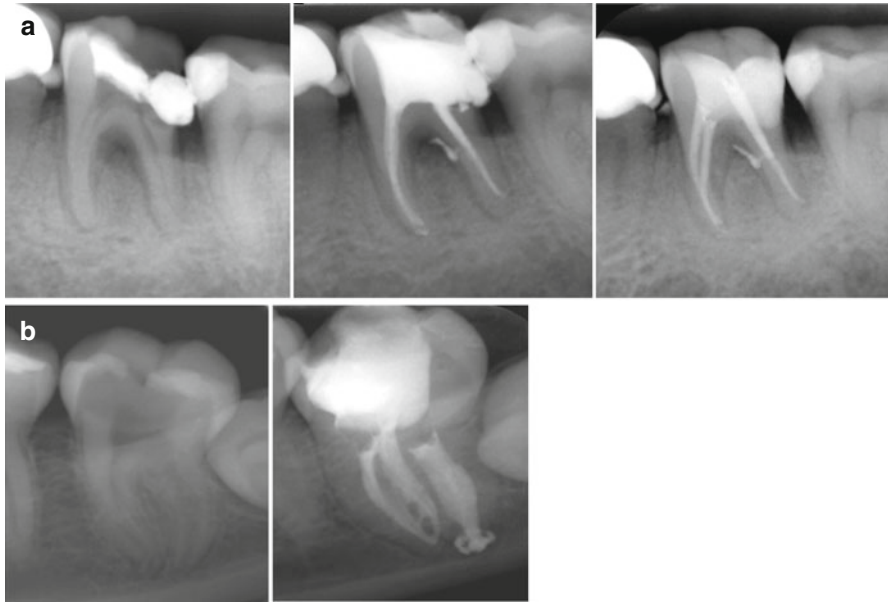


Fig. 6.10 Accessory anatomy in molars may be cleaned and subsequently filled when spaces can be reached by irrigation solution. **(a)** Furcal radiolucent area associated with a large accessory canal shows bone fill at a 6-month recall appointment. **(b)** The isthmus in the mesial root canal system and a long-oval canal in the distal root were disinfected and filled

to be counterproductive, because EDTA blocks the tissue-dissolving capacity of NaOCl [70].

There are also paste-type lubricants incorporating EDTA or other chelators. Such pastes can be used when negotiating root canals with vital pulp remnants; they do not help with smear layer removal. The use of such a paste during rotary shaping is also counterproductive because, as stated before, it deactivates NaOCl by reducing the available chlorine and perhaps even increases torsional load on rotary instrument. The use of a gel-type lubricant indeed resulted in similar torque compared to dry, nonlubricated canals [49, 71], while tap water and 2.5% NaOCl solutions increased cutting efficiency of rotary shaping instruments.

EDTA or other chelators should also be used previous to a last flush with NaOCl or saline [21] to remove the smear layer.

6.3.6 Step 5: Consider Accessory Anatomy

Another important factor that should be considered during irrigation is not only whether the irrigation system can deliver the irrigant to the apical third of the root canal, but also if it is capable of debriding areas that could not be reached with mechanical instrumentation, such as lateral canals and isthmi. Figure 6.10a shows the resolution of a periradicular and a furcal radiolucency after obturation of the lateral and furcal canal.

Clinicians may suspect of the presence of lateral canals after the diagnosis of a previously existent periradicular radiolucency. A recommended strategy during patency confirmation is to precurve the patency file at the end of the preparation in the presence of the irrigant to try to get the file in lateral portals of exit and therefore remove debris from lateral canals. However, the clinician will commonly not be aware of the proper cleaning of anatomic irregularities until their filling is demonstrated in a radiograph.

6.4 Obturation of the Molar Root Canal Systems

A well-shaped and well-debrided canal system would create the conditions for intact periapical tissues. On the other hand, this root canal system is inaccessible to the body's immune system and therefore cannot combat coronal leakage. Best practices therefore dictate that root canals should be filled as completely as possible in order to prevent ingress of nutrients or oral microorganism. None of the established techniques for root canal filling provides a definitive coronal, lateral, and apical seal [72]. For this reason, a permanent coronal restoration should be placed as soon as possible after the endodontic treatment (see Chap. 7).

Ideally, a root canal filling should seal all foramina leading to the periodontium, be without voids, adapted to the instrumented canal walls, and end at WL. The following steps will help to provide a fluid-tight seal of the cleaned and prepared molar root canal system in order to protect periradicular tissues from bacterial recontamination.

There are many clinically acceptable materials and techniques for root canal filling; the spectrum of root canal fillings includes:

1. Sealer (cement/paste/resin) only
2. Sealer and a single cone of a stiff or flexible core material
3. Sealer coating combined with cold compaction of core materials
4. Sealer coating combined with warm compaction of core materials
5. Sealer coating combined with carrier-based core materials

Several of these techniques have shown comparable success rates regarding apical bone fill or healing of periradicular lesions, so that a clinician may choose from a variety of techniques and approaches that work best for each specific case and/or clinician. The following list the main steps in molar root canal obturation:

1. Choosing a technique and timing the obturation
2. Selection of master cones
3. Canal drying and sealer application
4. Filling the apical portion (lateral and vertical compaction)
5. Completing the fill
6. Assessing the quality of the fill

Existing research directs clinicians toward preparation and disinfection of the root canal as the single most important factor in the treatment of endodontic

pathosis and no particular technique can claim superior healing success [1]. Decisions on which system to employ may be based on such factors as:

1. Clinicians' skill and comfort in using a certain technique
2. Efficiency of treatment
3. Simplicity of procedures involved
4. Costs incurred
5. Case selection

6.4.1 Step 1: Choosing a Technique and Timing the Obturation

The molar root canals to be filled should be assessed before choosing a technique. In the presence of open apices or procedural errors such as apical zipping and also for teeth with apices in close proximity to the mandibular canal, there is the potential for overfills. In order to avoid such mishaps, a non-expert clinician may better obturate these cases with cold lateral condensation to avoid overfilling. In some instances, for example an apical foramen size #60 or larger, MTA (ProRoot MTA, Dentsply Tulsa Dental, Tulsa OK) may be placed as barrier (Fig. 6.11). Molar canals frequently have accessory anatomy (see Chap. 1) and therefore a thermo-plastic obturation or injectable technique may allow better filling of these complex ramifications (see Fig. 6.10).

In general, canals should only be filled where there are no symptoms of acute apical periodontitis or an apical abscess, such as significant pain on percussion or not drable secretion into the canal.

6.4.2 Step 2: Selection of Master Cones

Before gutta-percha cones may be tried in a root canal, they should be disinfected by submerging them in sodium hypochlorite (NaOCl) solution for 60 s. The cones are marked at WL and placed on sterile gauze to dry until they are used (Fig. 6.12).

Most sealers are toxic in the freshly mixed state, but this toxicity is reduced after setting. When in contact with tissues and tissue fluids, zinc oxide eugenol-based sealers are absorbable while resin based materials typically are not absorbed [73]. Some by-products of sealers may adversely affect and delay healing. Therefore, sealers should not be routinely placed in periradicular tissues.

Cones are available in several tapers and often times a cone with taper larger than the ISO-norm standard of 0.02 is selected. The goal is to fit cones to the best wall contact at WL, as indicated by the sensation of tug-back, or resistance to pulling the cone out. If a cone is too tapered for the preparation, it will make contact with the canal wall away from WL. If it is not tapered enough, it will be loose, and looks crimped at the tip. A good primary fit (apical tug-back) of a master cone that is adjusted to fit both the apical size and the taper of the preparation is critical to promote a good fill.

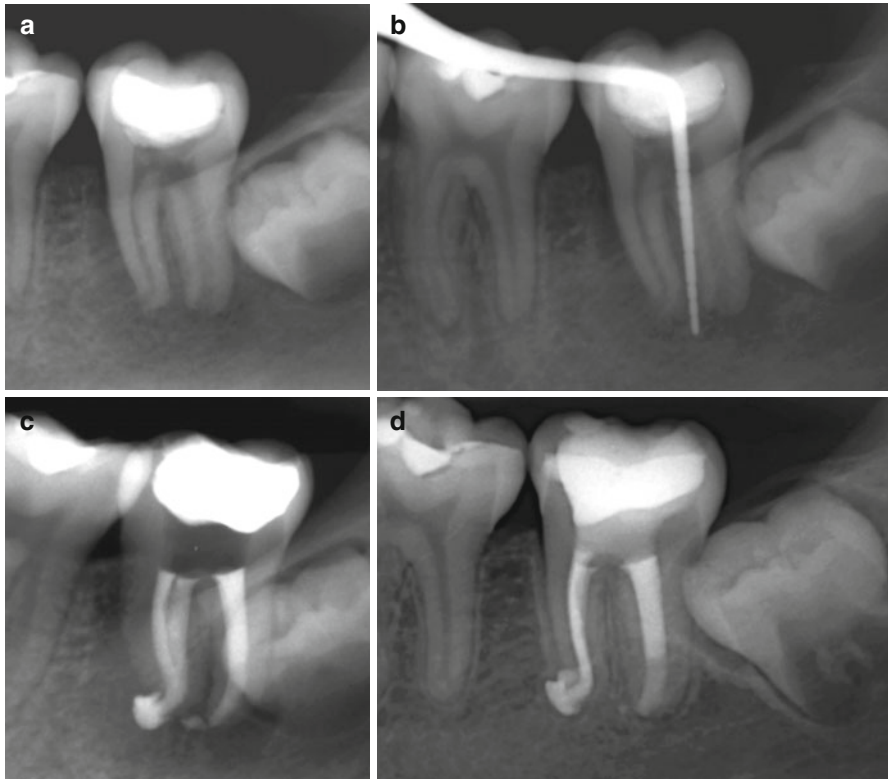


Fig. 6.11 Clinical treatment of a mandibular second molar with pulp necrosis and a large apical canal size (a). The periodontal probe was placed in a deep periodontal pocket (b). The final radiograph (c) and a 2-year follow-up (d) show placement of a MTA barrier in the distal canal and evidence of osseous healing

Adapting the master cone to fit correctly at the apical end of the preparation often means that the tip needs to be cut back to increase the diameter. A more precise way to modify the cone is to insert it into a gutta-percha gauge (Fig. 6.12) and to cut the cone to the same tip size as the last file that was taken to working length.

If the cone looks buckled or crimped, the taper of the preparation may have been insufficient and tug-back was experienced in the middle third of the root canal instead of at the most apical level.

6.4.3 Step 3: Canal Drying and Sealer Application

At this point in the clinical procedure, the root canal system should be dried, first by removing excess fluid with a suction cannula and a series of paper points that are placed to WL. Molar canals have often multiple communications and so all canals must be dried completely before any one canal may be filled. There is no clinical evidence to suggest the use of alcohol or any other solution at this stage.

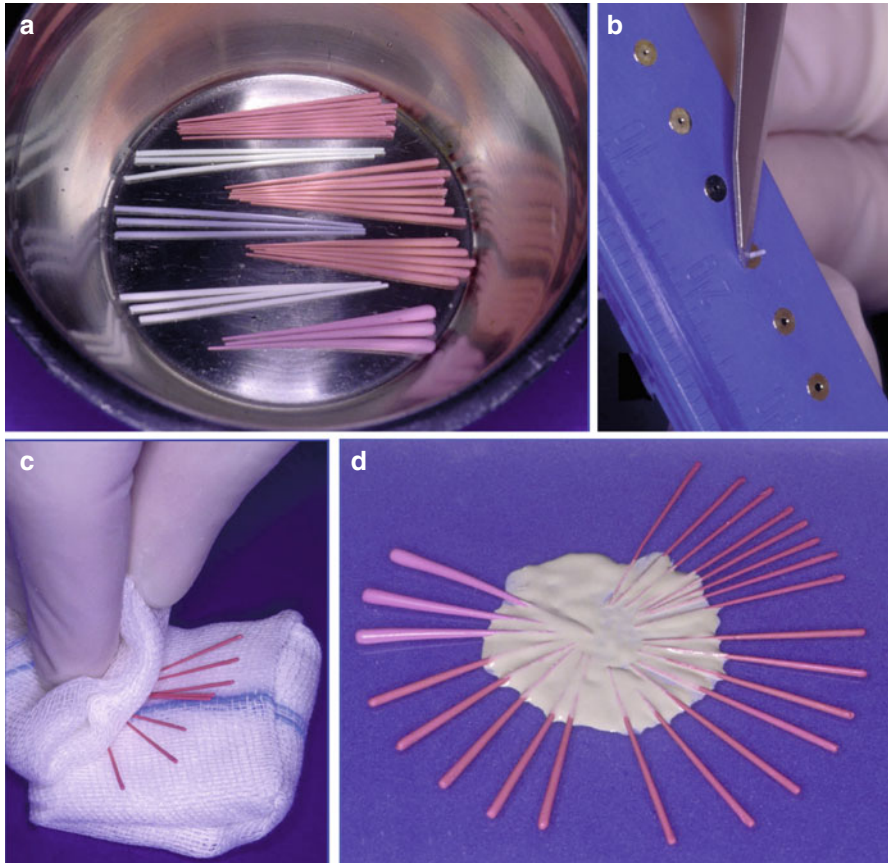


Fig. 6.12 In preparation for obturation, gutta-percha cones are disinfected by immersion in NaOCl (a), cut to the needed tip size (b), and dried with gauze (c). Prior to the obturation, cones can be dipped in the sealer (d)

The appropriate amount of sealer is then deposited into the canal system. This may be done using a lentulo spiral, a K-file, or the master cones themselves; either method is acceptable, provided that an appropriate amount of sealer is deposited (Fig. 6.13). If the master cones are the primary carrier for sealer, they should be once removed and inspected for a complete coating with sealer.

6.4.4 Step 4: Filling the Apical Portion (Lateral or Vertical Compaction)

The master cones are placed close to WL using a slight pumping motion to allow trapped air and the excess sealer to flow in a coronal direction. The marking on the cone should be close to the coronal reference point for WL determination.

For lateral compaction, a preselected finger spreader is then slowly inserted alongside the master cone to the marked length and held with measured apical

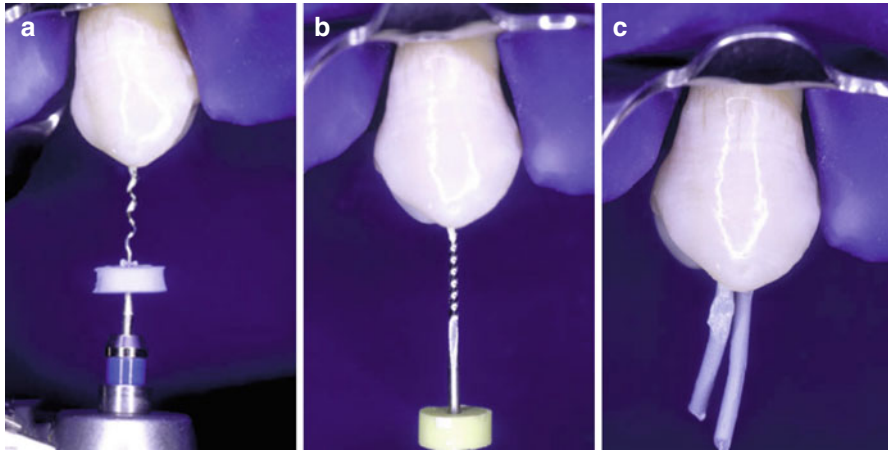


Fig. 6.13 Sealer may be placed into molar root canal systems with a lentulo spiral (a), a K-file (b), or the main gutta-percha cone (c)

pressure for about 10 s. During this procedure, the master cone is pushed laterally and vertically as the clinician feels the compression of the gutta-percha. Rotation of the spreader around its axis will disengage it from the gutta-percha mass and facilitate removal from the canal.

The space created by the spreader is filled by inserting a small, lightly sealer-coated accessory gutta-percha cone (Fig. 6.14). Using auxiliary cones larger than the taper of the spreader will produce voids or sealer pools in the filling and should be avoided. The procedure is repeated inserting several fine cones and moving to larger spreaders and cones until the entire canal is filled.

For vertical compaction, electrically heated pluggers are used to melt a master cone fitted to length. Tapered gutta-percha cones optimize the hydraulic forces that arise during compaction of softened gutta-percha with pluggers of a similar taper. After fitting the master cone as before, a hand plugger and a heated plugger are tried into the root canal. The goal is to find pluggers that fit to within about 4–7 mm from the apical constriction.

The depth of plugger binding should be marked with a rubber indicator, as this is where the instrument touches the canal wall. Heat control is extremely important and manufacturer's guidelines should be strictly adhered to, as heat is rapidly conducted into the periodontal ligament if the heat is activated for too long a time period. Also, strong compaction forces while a hand plugger is binding against the root wall could possibly lead to vertical root fractures.

After activating the heat switch, the electrically powered plugger is driven into the seated master cone, partially melting it and pushing softened gutta-percha in an apical and lateral direction. The plugger should stop at the premeasured depth and held for several seconds to compensate for shrinkage while the gutta-percha cools to body temperature. After briefly activating the power one more time to separate the apical fill from the plugger, the instrument is withdrawn and excess gutta-percha

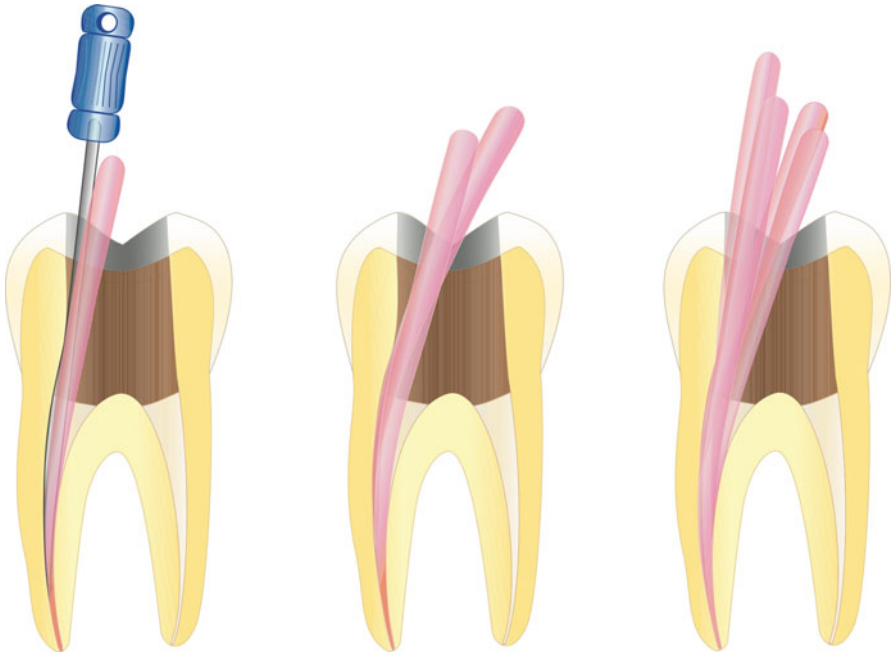


Fig. 6.14 For lateral compaction, space generated by deep spreader penetration is filled by progressively adding gutta-percha cones in the space created by the finger plugger (Reprinted from Arens et al., 2009, with permission)

wiped off. The apical portion of the canal is now filled and is compacted with the selected hand plugger (Fig. 6.15).

6.4.5 Step 5: Completing the Fill

For lateral compaction, the coronal canal portion is filled by adding cones placed to progressively smaller depths. When a cone with a taper larger than .02 was selected, only a few accessory cones are often sufficient to completely fill for example a distobuccal canal in a maxillary molar or a mesial canal in a mandibular molar that was prepared to a round cross section. In contrast, several more accessory cones or two master cones will have to be used in oval canals.

Such nonround or generally irregularly shaped canals in molars may also be filled using vertical compaction. After placement of the apical gutta-percha mass, a small amount of sealer is placed and the remainder of the canal is readily filled with melted gutta-percha from an extruder. Voids in the interface between the apical mass and the backfill gutta-percha are typically a result of the following errors:

1. Needle of the extruder was too large or not warm enough to melt apical gutta-percha.
2. Extruder was pulled back instead of maintaining apical pressure.

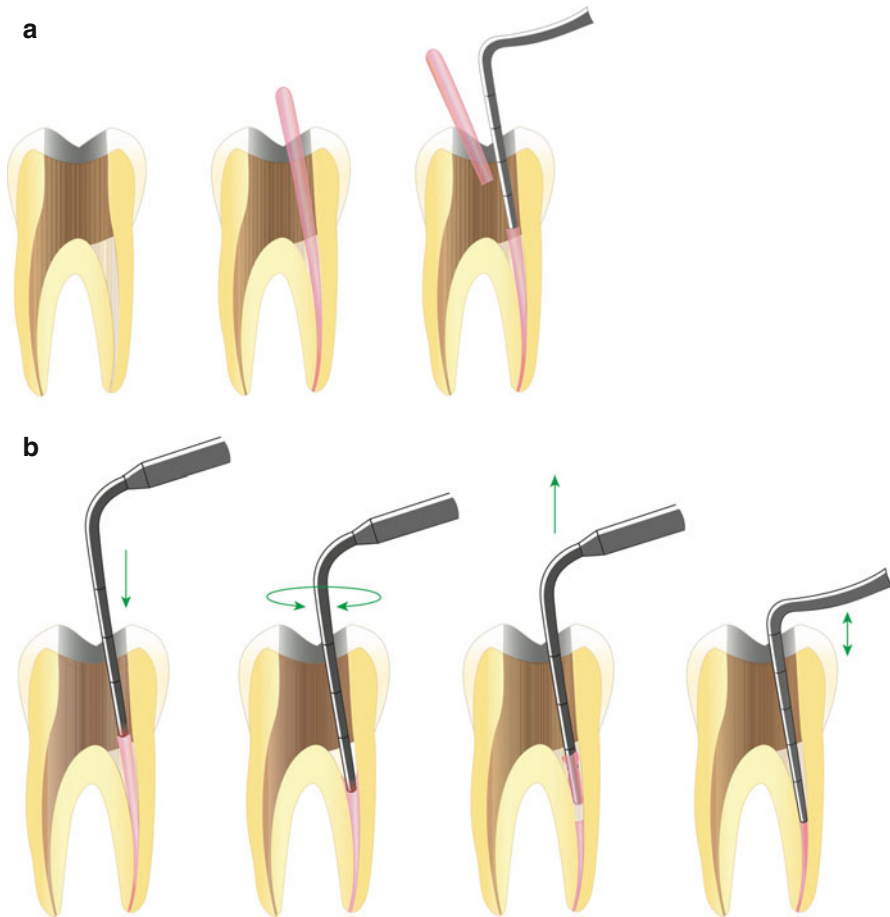


Fig. 6.15 For vertical compaction, the main cone coated with sealer is placed to working length and excess removed at the orifice level (a). The next sequence compacts the warmed gutta-percha mass and removed more excess, completely filling the apical canal segment (b). The coronal canal portion may be filled with various methods, most often with plastified gutta-percha from an extruder (not shown) (Reprinted from Arens et al., 2009, with permission)

3. Apical gutta-percha mass was not compacted to a flat contact surface.
4. Insufficient sealer was placed to the contact surface.

For both lateral and vertical compaction, the gutta-percha mass in each canal should end about 1 mm below the pulpal floor, leaving a small dimple. Only in cases where placement of a post is planned (see Chap. 7), gutta-percha is confined to the apical 5 mm. All molar canals that do not receive a post should be covered with an orifice barrier (Fig. 6.16) to protect from leakage prior to placement of a definitive restoration [74], promoting healing of apical periodontitis [75]. Materials that are suitable for such a barrier include light-curing glass ionomer, flowable composite, or fissure sealant. Placement of these materials requires a clean and bondable

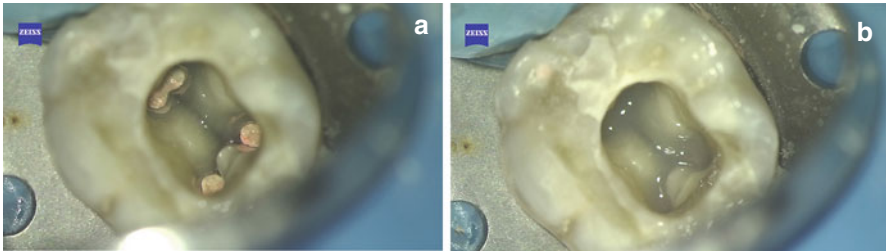


Fig. 6.16 Clinical appearance of the access cavity after a molar root canal system was filled with gutta-percha (a). To prevent coronal leakage, the orifices are covered with a thin layer of light-curing glass ionomer (b) (Courtesy of Dr. P. Bahrami)

surface; this can be achieved by removing sealer remnants with alcohol, a mini-sandblaster, or a fine-grain round diamond bur. A short treatment with phosphoric acid is also indicated. In order to facilitate retreatment, it becomes necessary such a barrier should be thin so that the gutta-percha fill is just visible (Fig. 6.16).

6.4.6 Step 6: Quality Criteria After Obturation

Prepared and filled canals should demonstrate a homogenous radiopaque appearance, free of voids and importantly filled to working length. The fill should approximate canal walls and extend as much as possible into canal irregularities such as an isthmus or a C-shaped canal system. The fill of accessory canals is not predictable and not per se a prerequisite for success [76]. However, in molar cases with larger accessory spaces, in addition to the main canals, procedures such as the ones described in this chapter typically result in debridement and often radiographically visible fill (see Figs. 6.1, 6.4 and 6.10).

In order to avoid overextension of root filling material into the periapical tissue, specifically in the mandibular canal, it is recommended to accurately determine working length to prevent destruction of the apical constriction. For infected root canal systems, the best healing results are achieved when the working length is between 0 and 0.5 mm from the tip of the root as visible on a radiograph [1, 2].

In molar endodontics, determination of apical canal anatomy is often difficult. It may be appropriate for second mandibular molars that are in close proximity to the mandibular canal to deemphasize patency and even block apical foramina to avoid large overfills (Fig. 6.17). Large overfills may be an impediment to healing and in the worst case may be associated with nerve damage.

In general, undesirable and uncorrectable outcomes of molar root canal treatment, identifiable on the final radiograph, include:

1. Excessive dentin removal during access and instrumentation
2. Overt preparation error such as perforation, ledge formation, and apical zipping
3. Presence of an instrument fragment in not fully disinfected canals
4. Overfill and overextension

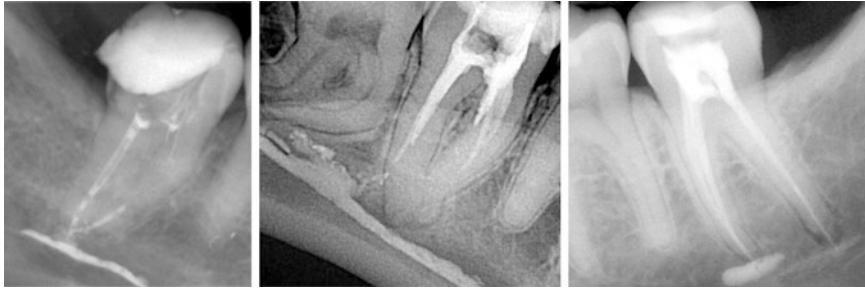


Fig. 6.17 Examples of molar root canal treatment that resulted in significant overfill. Such a condition can result in permanent damage when sealer is placed close to the infraalveolar nerve. All cases shown resulted in paresthesia (Courtesy of Dr. A. Gluskin)

Each of these outcomes must be documented and the patient notified as they may reduce the odds for a successful outcome. In cases such as par- or dysesthesia after an overfill, immediate attention and possibly referral is indicated.

6.5 Special Considerations for Different Canal Configurations

As described before, detailed knowledge of anatomic structures and an optimal case selection strategy is mandatory to assess the difficulty of the shaping procedure in molar endodontics. The relevant steps differ shaping root canals with varying levels of difficulty. Specific strategies, recommendations, and concerns are described below for specific situations.

6.5.1 Cases With Relatively Low Complexity

It may not be necessary to follow all steps of the list described earlier for canal shaping in all cases; indeed steps 2 and 3 may not be needed. For molar canals with comparatively low complexity (Fig. 6.18), these following modified checklist may be applied:

- *Step 1: Analysis of the specific anatomy of the case*
- *Step 4: Negotiation to patency*
- *Step 5: Determination of working length*

Consider using larger files for working length determination with an apex locator. The better the adaptation of the tip of the instrument to the foramen, the more accurate the length determination.

- *Step 6: Glide path preparation*
- *Step 7: Root canal shaping to desired size*

The more recently advocated simplification of using a single-file, single-length technique may work well in this anatomy, where a single rotary or reciprocating

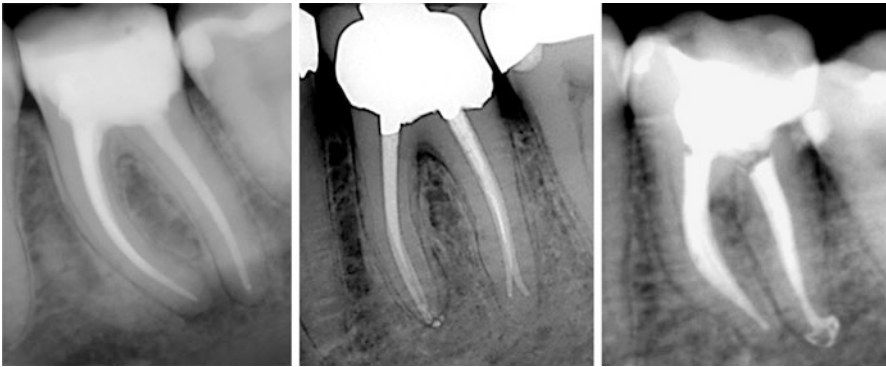


Fig. 6.18 Cases with low level of complexity. Protocol described for “Cases with relatively low complexity” was followed

instrument may perform the whole shaping procedure. However, it is especially important to check the amount of debris accumulated in the last millimeters of the file. The absence of dentin indicates that the foramen is larger than the tip of the file and a larger file may be needed to complete the shaping procedure.

- *Step 8: Gauging the foramen, apical adjustment*

It is more difficult to perform this step correctly in a canal with a large apical third compared to a small-diameter one. A gauging .02-tapered K-file with the same diameter of an inadequate master apical file could bind short of WL due to a lack of a continuous taper increasing progressively from the apical to the coronal third in a large canal. This mistake can impede the improper selection of the apical file size and therefore can create problems during vertical compaction of gutta-percha.

6.5.2 Cases With Moderate Complexity

For more complex cases (Fig. 6.19), all eight steps of the generic checklist should be included and carefully followed. Special attention should be given to certain steps as listed below:

- *Step 1: Analysis of the specific anatomy of the case*
- *Step 2: Canal scouting*
- *Step 3: Coronal modifications*
- *Step 4: Negotiation to patency*

Careful precurving any negotiation file may be needed to ensure patency without creating procedural errors during this stage.

- *Step 5: Determination of working length*
- *Step 6: Glide path preparation*
- *Step 7: Root canal shaping to desired size*

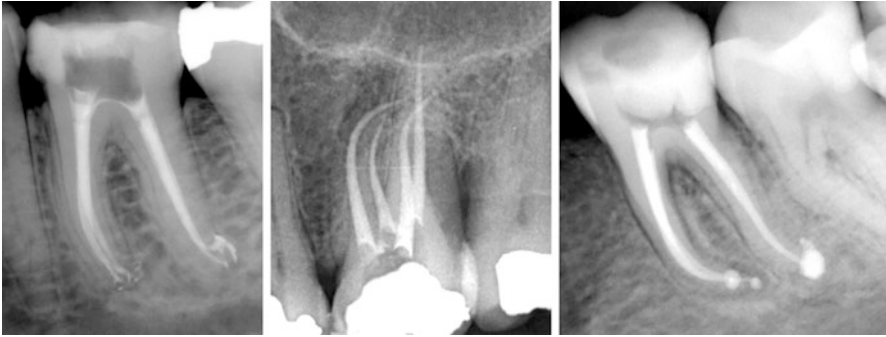

Fig. 6.19 Cases with medium level of complexity. Protocol described for “Cases with moderate complexity” was followed

A single-file technique is typically not appropriate in molar cases of moderate difficulty. The fact that there will be wide variations in the anatomical complexity does not allow reducing the number of preprogrammed apical size to 1 or 2. Consider adapting the tools to the anatomy of the specific canal system, rather than adapting the canal to the tool.

- *Step 8: Gauging the foramen, apical adjustment*

6.5.3 Cases with High Complexity, Including Challenging S-Curves

In cases of significant complexity, such as shown in Figure 6.20, attention should be focused on several steps in the generic checklist as outlined below:

- *Step 1: Analysis of the specific anatomy of the case*
- *Step 2: Canal scouting*
- *Step 3: Coronal modifications*

When shaping very difficult canals with significant and multiplanar curvatures, shaping procedures can be simplified by dividing the entire root canal in two different root canals or shaping stages. Procedural accidents in the apical third during negotiation can be avoided when the coronal two-thirds of the root canal are preenlarged before the negotiation of the apical third. Preenlargement procedures may be done as if the root canal were two different canals. After scouting the canal with a #08 or #10 file, first shape the straight coronal portion (first part of the curvature or first stage) as an easy canal and this will allow a better negotiation of a shorter difficult apical third and an easier shaping of this third alone after removing the restrictive dentin in the coronal and middle third.

Generally speaking, the overall length of a molar ranges from 19 to 25 mm, with around 10 mm the length of the clinical crown and the rest (9–15 mm) the length of the root. If this 9–15 mm is divided between the three-thirds of a root canal, it makes a total of 3–5 mm for the coronal, middle, and apical root third, respectively.

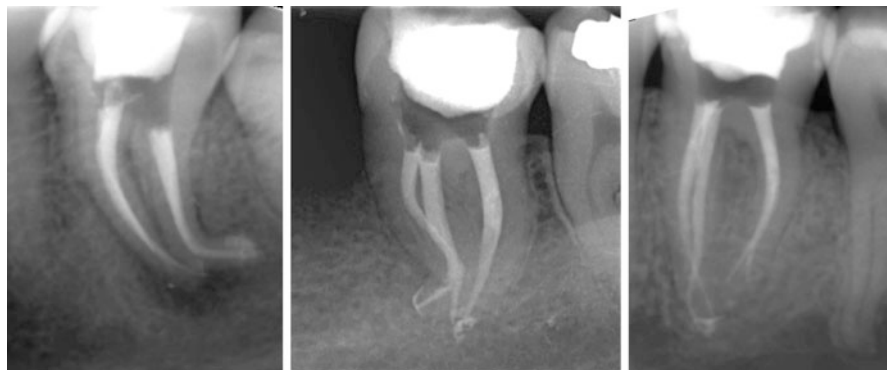


Fig. 6.20 Cases with high level of complexity. Protocol described for “Case with high complexity, including challenging s-curves” was followed

When shaping a difficult root canal, the most challenging anatomy is often located in the apical third of the root canal. If we break down the root canal in the three segments described above and prepare the two coronal thirds before even trying to scout the apical third with a small file, procedural accidents are predictably avoided and preparation of the most delicate area is facilitated. With the coronal two-thirds optimally prepared, we can then scout the rest of the canal with small instruments, reach the working length with precurved files, confirm apical patency, and decide if the apical third can be shaped with rotary techniques (if a glide path is achieved) or manual instrumentation [77].

- *Step 4: Negotiation to patency*

Apart from the strategies for negotiation mentioned above, the following can be of great help when working with extreme anatomies:

Files with large soft handles help reduce fingers fatigue (Senseus, Dentsply Maillefer, Ballaigues, Switzerland) during the arduous task of negotiating the most difficult curvatures, for example # 08 and # 10 K-files with silicon handles.

In difficult canals it is desirable to use also #08 files. If negotiation with a #08 or #10 file is not possible due to an impediment, place a short curvature at the last mm of the file and look for the passive way to length when a “sticky” feel is noticed with the curved portion in order to bypass the impediment. Once bypassed, use a #10 file with the same bend and push pull to reduce the impediment. Many times, the actual problem in difficult canals is that the apical foramen is 90° from the main canal.

Keep the canal patent throughout the procedure. The more difficult the canal, the more important it is maintaining apical patency to avoid blocking the apical foramen and posterior accidents when trying to reach the appropriate length again.

- *Step 5: Determination of working length*

- *Step 6: Glide path preparation*

After sizes #8 and #10, different strategies have been suggested to get a #15 file to WL and achieve a glide path. There is a big jump between #10 and #15 when

shaping difficult canals. The use of a Golden Mediums instrument (Dentsply Maillefer) with a half size 0.12 will help the #15 file to reach working length.

Step back with #20 and #25 files with balanced force techniques to remove the resistance coronal to the WL that is not allowing the #15 instrument to reach the full length.

Creating a glide path with rotary instruments as Pathfile #1 and #2 (Dentsply Tulsa Dental) after reaching the working length with a #10 file helps to manage the difficulties avoiding the transportation of the apical foramen in these extreme cases.

- *Step 7: Root canal shaping to desired size*

Selecting flexible and resistant rotary instruments is very important not to deform the apical third of these more complicated canals after achieving a glide path. Thoroughly follow the instructions recommended in the step “root canal preparation” to avoid flexural fatigue of the instruments when shaping extreme curvatures.

Different rotary systems have manual instrument sets (ProTaper, GT, both Dentsply Tulsa Dental) with the same characteristics, tapers, and diameters than corresponding rotaries that provide the same shape as the rotary instruments. This reduces the risk of instrument fracture when no predictable glide path was created. If manual instrumentation is performed with such hand instruments rather than the classic ISO files, the resistance form along the root canal is maintained.

- *Step 8: Gauging the foramen, apical adjustment*

References

1. Ng Y-L, Mann V, Gulabivala K. A prospective study of the factors affecting outcomes of non-surgical root canal treatment: part 1: periapical health. *Int Endod J.* 2011;44:583–609.
2. Ricucci D, Russo J, Rutberg M, Burleson JA, Spångberg LS. A prospective cohort study of endodontic treatments of 1,369 root canals: results after 5 years. *Oral Surg Oral Med Oral Pathol Oral Radiol Endod.* 2011;112:825–42.
3. Karabucak B, Bunes A, Chehoud C, Kohli MR, Setzer F. Prevalence of apical periodontitis in endodontically treated premolars and molars with untreated canal: a cone-beam computed tomography study. *J Endod.* 2016;42:538–41.
4. Pettiette MT, Delano EO, Trope M. Evaluation of success rate of endodontic treatment performed by students with stainless-steel K-files and nickel-titanium hand files. *J Endod.* 2001;27:124–7.
5. Sjögren U, Hagglund B, Sundqvist G, Wing K. Factors affecting the long-term results of endodontic treatment. *J Endod.* 1990;16:498–504.
6. Kuttler S, McLean A, Dorn S, Fischzang A. The impact of post space preparation with Gates-Glidden drills on residual dentin thickness in distal roots of mandibular molars. *J Am Dent Assoc.* 2004;135:903–9.
7. Leeb J. Canal orifice enlargement as related to biomechanical preparation. *J Endod.* 1983;9:463–70.
8. Stabholz A, Rotstein I, Torabinejad M. Effect of preflaring on tactile detection of the apical constriction. *J Endod.* 1995;21:92–4.
9. Peters OA, Morgental RD, Schulze KA, Paqué F, Kooper PMP, Vier-Pelisser FV. Determining cutting efficiency of nickel-titanium coronal flaring instruments used in lateral action. *Int Endod J.* 2014;47:505–13.

10. Izu KH, Thomas SJ, Zhang P, Izu AE, Michalek S. Effectiveness of sodium hypochlorite in preventing inoculation of periapical tissues with contaminated patency files. *J Endod.* 2004;30:92–4.
11. Souza R. The importance of apical patency and cleaning of the apical foramen on root canal preparation. *Brazil Dent J.* 2006;17:6–9.
12. Arias A, Azabal M, Hidalgo JJ, la Macorra de JC. Relationship between postendodontic pain, tooth diagnostic factors, and apical patency. *J Endod.* 2009;35:189–92.
13. Zhu WC, Gyamfi J, Niu LN, Schoeffel GJ, Liu SY, Santarcangelo F, et al. Anatomy of sodium hypochlorite accidents involving facial ecchymosis - a review. *J Dent.* 2013;41:935–48.
14. Cailleteau JG, Mullaney TP. Prevalence of teaching apical patency and various instrumentation and obturation techniques in United States dental schools. *J Endod.* 1997;23:394–6.
15. Flanders DH. Endodontic patency. How to get it. How to keep it. Why it is so important? *N Y State Dent J.* 2002;68:30–2.
16. Buchanan LS. Management of the curved root canal. *J Cal Dent Assoc.* 1989;17:18–25. –7.
17. Sanchez JAG, Duran-Sindreu F, Matos MA, Carabaño TG, Bellido MM, Castro SM, et al. Apical transportation created using three different patency instruments. *Int Endod J.* 2010;43:560–4.
18. Vera J, Hernández EM, Romero M, Arias A, van der Sluis LWM. Effect of maintaining apical patency on irrigant penetration into the apical two millimeters of large root canals: an in vivo study. *J Endod.* 2012;38:1340–3.
19. Vera J, Arias A, Romero M. Effect of maintaining apical patency on irrigant penetration into the apical third of root canals when using passive ultrasonic irrigation: an in vivo study. *J Endod.* 2011;37:1276–8.
20. Vera J, Arias A, Romero M. Dynamic movement of intracanal gas bubbles during cleaning and shaping procedures: the effect of maintaining apical patency on their presence in the middle and cervical thirds of human root canals—an in vivo study. *J Endod.* 2012;38:200–3.
21. Haapasalo M, Endal U, Zandi H, Coil JM. Eradication of endodontic infection by instrumentation and irrigation solutions. *Endod Topics.* 2005;10:77–102.
22. West J. Endodontic update 2006. *J Esthet Restor Dent.* 2006;18:280–300.
23. American Association of Endodontists. Glossary of Endodontic Terms 2015 [accessed 2/27/2016]. Available from: <http://www.nxtbook.com/nxtbooks/aae/endodonticglossary2015/>.
24. Ricucci D, Langeland K. Apical limit of root canal instrumentation and obturation, part 2. A histological study. *Int Endod J.* 1998;31:394–409.
25. Wu MK, Wesslink PR, Walton RE. Apical terminus location of root canal treatment procedures. *Oral Surg Oral Med Oral Pathol Oral Radiol Endod.* 2000;89:99–103.
26. Schaeffer MA, White RR, Walton RE. Determining the optimal obturation length: a meta-analysis of literature. *J Endod.* 2005;31:271–4.
27. Nair PNR. On the causes of persistent apical periodontitis: a review. *Int Endod J.* 2006;39:249–81.
28. Siqueira JF. Aetiology of root canal treatment failure: why well-treated teeth can fail. *Int Endod J.* 2001;34:1–10.
29. Wu MK, Dummer PMH, Wesslink PR. Consequences of and strategies to deal with residual post-treatment root canal infection. *Int Endod J.* 2006;39:343–56.
30. Friedman S. Management of post-treatment endodontic disease: a current concept of case selection. *Aus Endod J.* 2000;26:104–9.
31. Elayouti A, Weigner R, Löst C. The ability of root ZX apex locator to reduce the frequency of overestimated radiographic working length. *J Endod.* 2002;28:116–9.
32. Tan BT, Messer HH. The quality of apical canal preparation using hand and rotary instruments with specific criteria for enlargement based on initial apical file size. *J Endod.* 2002;28:658–64.
33. Patiño PV, Biedma BM, Liébana CR, Cantatore G, Bahillo JG. The influence of a manual glide path on the separation rate of NiTi rotary instruments. *J Endod.* 2005;31:114–6.
34. Blum JY, Machtou P, Micallef JP. Location of contact areas on rotary Profile instruments in relationship to the forces developed during mechanical preparation on extracted teeth. *Int Endod J.* 1999;32:108–14.

35. Paque F, Balmer M, Attin T, Peters OA. Preparation of oval-shaped root canals in mandibular molars using nickel-titanium rotary instruments: a micro-computed tomography study. *J Endod.* 2010;36:703–7.
36. Cheung GS, Liu CS. A retrospective study of endodontic treatment outcome between nickel-titanium rotary and stainless steel hand filing techniques. *J Endod.* 2009;35:938–43.
37. Bonessio N, Arias A, Lomiento G, Peters OA. Effect of root canal treatment procedures with a novel rotary nickel titanium instrument (TRUShape) on stress in mandibular molars: a comparative finite element analysis. *Odontology.* 2016. epub ahead of print.
38. Ng YL, Mann V, Gulabivala K. A prospective study of the factors affecting outcomes of non-surgical root canal treatment: part 2: tooth survival. *Int Endod J.* 2011;44:610–25.
39. Landys Boren D, Jonasson P, Kvist T. Long-term survival of endodontically treated teeth at a public dental specialist clinic. *J Endod.* 2015;41:176–81.
40. Di Fiore PM. A dozen ways to prevent nickel-titanium rotary instrument fracture. *J Am Dent Assoc.* 2007;138:196–201.
41. Peters OA. Current challenges and concepts in the preparation of root canal Systems: a review. *J Endod.* 2004;30:559–67.
42. Abou-Rass M, Piccinino MV. The effectiveness of four clinical irrigation methods on the removal of root canal debris. *Oral Surg Oral Med Oral Pathol.* 1982;54:323–8.
43. Boutsioukis C, Kishen A. Fluid dynamics of syringe-based irrigation to optimise anti-biofilm efficacy in root-canal disinfection. *Roots.* 2012;4:22–31.
44. Basrani B, Haapasalo M. Update on endodontic irrigating solutions. *Endod Topics.* 2012;27(1):74–102.
45. Zehnder M. Root canal Irrigants. *J Endod.* 2006;32:389–98.
46. Rosenfeld EF, James GA, Burch BS. Vital pulp tissue response to sodium hypochlorite. *J Endod.* 1978;4:140–6.
47. Svec TA, Harrison JW. Chemomechanical removal of pulpal and dentinal debris with sodium hypochlorite and hydrogen peroxide vs normal saline solution. *J Endod.* 1977;3:49–53.
48. Waltimo T, Trope M, Haapasalo M, Ørstavik D. Clinical efficacy of treatment procedures in endodontic infection control and one year follow-up of periapical healing. *J Endod.* 2005;31:863–6.
49. Boessler C, Peters OA, Zehnder M. Impact of lubricant parameters on rotary instrument torque and force. *J Endod.* 2007;33:280–3.
50. Jungbluth H, Peters CI, Peters OA, Sener B, Zehnder M. Physicochemical and pulp tissue dissolution properties of some household bleach brands compared with a dental sodium hypochlorite solution. *J Endod.* 2012;38:372–5.
51. Basrani BR, Manek S, Sodhi RNS, Fillery E, Manzur A. Interaction between sodium hypochlorite and chlorhexidine gluconate. *J Endod.* 2007;33:966–9.
52. Retamozo B, Shabahang S, Johnson N, Aprecio RM, Torabinejad M. Minimum contact time and concentration of sodium hypochlorite required to eliminate *Enterococcus faecalis*. *J Endod.* 2010;36:520–3.
53. Gu L-S, Kim JR, Ling J, Choi KK, Pashley DH, Tay FR. Review of contemporary irrigant agitation techniques and devices. *J Endod.* 2009;35:791–804.
54. Boutsioukis C, Lambrianidis T, Kastrinakis E. Irrigant flow within a prepared root canal using various flow rates: a computational fluid dynamics study. *Int Endod J.* 2009;42:144–55.
55. Gutarts R, Nusstein J, Reader A, Beck M. In vivo debridement efficacy of ultrasonic irrigation following hand-rotary instrumentation in human mandibular molars. *J Endod.* 2005;31:166–70.
56. Peters OA, Bardsley S, Fong J, Pandher G, DiVito E. Disinfection of root canals with photon-initiated photoacoustic streaming. *J Endod.* 2011;37:1008–12.
57. DiVito E, Peters OA, Olivi G. Effectiveness of the erbium: YAG laser and new design radial and stripped tips in removing the smear layer after root canal instrumentation. *Lasers Med Sci.* 2012;27:273–80.
58. Peters OA, Paque F. Root canal preparation of maxillary molars with the self-adjusting file: a micro-computed tomography study. *J Endod.* 2011;37:53–7.

59. Haapasalo M, Wang Z, Shen Y, Curtis A, Patel P, Kakpour M. Tissue dissolution by a novel multisonic ultracleaning system and sodium hypochlorite. *J Endod.* 2014;40:1178–81.
60. Clark-Holke D, Drake D, Walton R, Rivera E. Bacterial penetration through canals of endodontically treated teeth in the presence or absence of the smear layer. *J Dent.* 2003;31:275–81.
61. Torabinejad M, Handysides R, Khademi AA, Bakland LK. Clinical implications of the smear layer in endodontics: a review. *Oral Surg Oral Med Oral Pathol Oral Radiol Endod.* 2002;94:658–66.
62. Delivanis PD, Mattison GD, Mendel RW. The survivability of F43 strain of *Streptococcus sanguis* in root canals filled with gutta-percha and Procosol cement. *J Endod.* 1983;9:407–10.
63. Ørstavik D, Haapasalo M. Disinfection by endodontic irrigants and dressings of experimentally infected dentinal tubules. *Endod Dent Traumatol.* 1990;6:142–9.
64. Cobankara FK, Unlu N, Cetin AR, Ozkan HB. The effect of different restoration techniques on the fracture resistance of endodontically-treated molars. *Oper Dent.* 2008;33:526–33.
65. Okşan T, Aktener BO, Şen BH. The penetration of root canal sealers into dentinal tubules. A scanning electron microscopic study. *Int Endod J.* 1993;26:301–5.
66. Wennberg A, Ørstavik D. Adhesion of root canal sealers to bovine dentine and gutta-percha. *Int Endod J.* 1990;23:13–9.
67. Hülsmann M, Heckendorff M, Lennon A. Chelating agents in root canal treatment: mode of action and indications for their use. *Int Endod J.* 2003;36:810–30.
68. Paqué F, Luder HU, Sener B, Zehnder M. Tubular sclerosis rather than the smear layer impedes dye penetration into the dentine of endodontically instrumented root canals. *Int Endod J.* 2006;39:18–25.
69. Baumgartner JC, Mader CL. A scanning electron microscopic evaluation of four root canal irrigation regimens. *J Endod.* 1987;13:147–57.
70. Grawehr M, Sener B, Waltimo T, Zehnder M. Interactions of ethylenediamine tetraacetic acid with sodium hypochlorite in aqueous solutions. *Int Endod J.* 2003;36:411–7.
71. Peters OA, Boessler C, Zehnder M. Effect of liquid and paste-type lubricants on torque values during simulated rotary root canal instrumentation. *Int Endod J.* 2005;38:223–9.
72. Li GH, Niu LN, Zhang W, Olsen M, De-Deus G, Eid AA, et al. Ability of new obturation materials to improve the seal of the root canal system: a review. *Acta Biomater.* 2014;10:1050–63.
73. Ricucci D, Rocas IN, Alves FR, Loghin S, Siqueira Jr JF. Apically extruded sealers: fate and influence on treatment outcome. *J Endod.* 2016;42:243–9.
74. Wolcott JF, Hicks ML, Himel VT. Evaluation of pigmented intraorifice barriers in endodontically treated teeth. *J Endod.* 1999;25:589–92.
75. Yamauchi S, Shipper G, Buttke T, Yamauchi M, Trope M. Effect of orifice plugs on periapical inflammation in dogs. *J Endod.* 2006;32:524–6.
76. Ricucci D, Siqueira Jr JF. Fate of the tissue in lateral canals and apical ramifications in response to pathologic conditions and treatment procedures. *J Endod.* 2010;36:1–15.
77. Ruddle C. Shaping for success...everything old is new again. *Dent Today.* 2006;25:120–7.

Considerations for the Restoration of Endodontically Treated Molars

7

Julian G. Leprince, Gaetane Leloup, and Chloé M.F. Hardy

Abstract

The restoration of endodontically treated teeth must be considered as integral part of the endodontic treatment, since it plays a major role in the long-term success of the procedure, as well as in tooth longevity. In order to maximize the chances of success, the specificities of endodontically treated molars need to be carefully considered, as well as the recent advances in adhesion, digital technologies, and biomaterials. This chapter will critically discuss important aspects such as reinforcement, restoration retention, the need for a ferrule and/or for posts, and the importance of cuspal coverage. Best-practice recommendations will be made, with particular focus on tissue preservation.

Guiding Reference

van Dijken JW, Hasselrot L. A prospective 15-year evaluation of extensive dentin-enamel-bonded pressed ceramic coverages. *Dent Mater.* 2010;26:929–39.

This prospective study on molars with long-term follow-up investigated the durability of ceramic restorations that were luted with different bonding systems. More restorations failed in root canal-treated molars compared to vital counterparts (21 and 39 %, respectively). Other relevant factors for failure included the bonding agent used, gender, and parafunctional habits. The technique investigated showed advantages like less destruction of healthy tissue, and avoiding of endodontic treatment and/or deep cervical placement of restoration margins to obtain retention.

J.G. Leprince, DDS, PhD (✉) • G. Leloup, DDS, PhD • C.M.F. Hardy, DDS
School of Dentistry, Cliniques Universitaires Saint Luc – Université catholique de Louvain,
Avenue Hippocrate 10, Brussels, Belgium
e-mail: Julian.leprince@uclouvain.be

7.1 Introduction

Root canal treatment should not be considered finished until the tooth in question is restored in a timely and adequate fashion. It is clear from the literature that any delay between endodontic treatment and tooth restoration should be as brief as possible, since significantly reduced change of survival after endodontic treatment was reported for teeth restored with temporary restorations, compared to those receiving a permanent restoration [1]. Regarding the way endodontically treated molars should be restored, we lack a clear response to several important questions, which will be listed in the next section of this chapter.

Best clinical practice should refer to the highest level of evidence, that is, randomized controlled clinical studies. This is exemplified in the conclusion of authors dealing with the restoration of endodontically treated teeth. For example, Al-Omiri and others state [2]: “Most guidelines were based mainly on *ex vivo* studies and to a lesser extent on limited *in vivo* studies. The lack of long-term controlled randomized clinical studies was the main hindrance to reaching a conclusive and undisputable opinion regarding endodontic posts in terms of tooth fracture and biomechanical behaviour.” While Peroz and others find [3]: “These guidelines are based mainly on *in vitro* studies with an evidence level of IIa or IIb, as there is a lack of randomized clinical studies available.”

Even from clinical studies, it is difficult to extract clear clinical guidelines. For example, in a recently published practice-based study, it is stated that the influence of tooth type on the survival of endodontically treated teeth is not well established in the literature [4]. The authors found that restorations placed on premolars and anterior teeth were more successful compared with restorations in molars, but this is not universally accepted [5, 6].

In fact, lack of consideration of some factors prevents clear evidence-based guidelines for the restoration of endodontically treated teeth. To give a specific example, in a meta-analysis (high level of evidence) evaluating the prognostic factors for tooth survival after endodontic treatment, the placement of crowns or cast restorations was reported to improve tooth survival compared to direct restorations [7]. Nevertheless, some important parameters were not taken into account in the analysis in that study, notably the tooth type, the amount and distribution of residual tooth structure, or the type of final restoration.

Confounding variables further compromise these results. For example, it has been argued that teeth with preoperative periapical lesions are less likely to receive a crown compared to those without lesion and anterior teeth are more likely to be restored with a filling and sooner than posterior teeth [8]. This indicates a treatment selection bias and highlights that considering restorations of endodontically treated teeth must be specific to the type of tooth and the amount and distribution of remaining tissue.

The present chapter will focus on the literature dealing specifically with the restoration of molars after endodontic treatment. With the limitations pointed out above, the following aims at providing best-practice considerations in the restoration of endodontically treated molars, with particular focus on the most recent scientific data and technological innovations and relate that to clinical questions.

7.2 Questions That Arise in Daily Practice

Providing a fluid-tight seal and long-term stability of the root canal treatment is only one of many factors that the restorative dentist needs to fulfill. In general dental practice, patient expectations are more related to the restoration of masticatory function, the aesthetics, the longevity of the restoration, or to more practical factors such as chair-side time or the cost of the restorative procedure [9]. Hence, several questions come to mind when considering how an endodontically treated molar should be restored. The subsequent paragraphs will provide some clinical questions with briefly remarked answers that will be revisited later in the chapter.

- *Should all endodontically treated teeth be restored with a cast crown?*

While cuspal coverage is typically recommended, this may not be necessary in many instances, since such a decision should depend on the amount of remaining coronal tissue. In teeth with little tissue loss, for example, limited to the access cavity, a direct restoration is a valid option. It is less expensive for the patient, conserves tooth structure, and is faster, and efficient, since the patient leaves the practice with a permanent restoration in a single appointment.

- *Where is the limit, deciding between a direct and indirect restoration for endodontically treated molars?*

Historically, in teeth with substantial tissue loss, which is frequently the case when a root canal treatment is required, the use of metal posts was often necessary. This was to provide retention for nonadhesive materials such as silver amalgams (Fig. 7.1a) or other precious metal core materials to support cast crown (Fig. 7.1b, c).

- *Are posts required for the restoration of endodontically treated molars? Which posts, for example, which type, shape, size, or diameter?*

The placement of certain posts usually requires additional dentin removal, and may therefore result in a weakening of the tooth (Fig. 7.1c). The stiffness of metal posts materials could also generate inappropriate stresses on the thin remaining dentin walls, which may result in root fracture (Fig. 7.1d).

- *Do posts reinforce or weaken endodontically treated molars?*

It must be kept in mind that retention of a restoration (survival) does not necessarily mean clinical success. In some instances, even if the retention provided by the post is sufficient to maintain the restoration in place, the loss of marginal seal should already be considered as a failure, and restoration repair or replacement should be performed. This is illustrated by a very extreme situation in Fig. 7.1e, but more moderate cases of this very situation are not uncommon. While reinforcement of

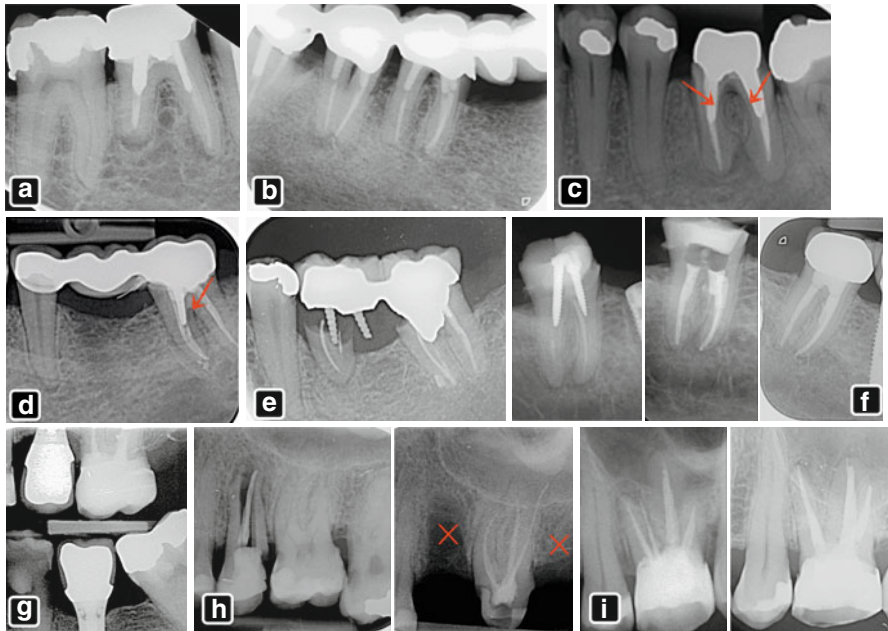


Fig. 7.1 Selection of clinical cases of molar endodontics with (a) a right mandibular first molar (46 FDI, #30 Universal) with inadequate root canal treatment, periapical lesions on both roots and a large amalgam restoration retained by two metal posts; (b) a long-span bridge restoration including three molars, with metal posts in multiple root canals; (c) tooth 36 (#19) with cast post and core in precious alloy before crown placement. Note the very thin remaining dentin layer toward the furcation of both roots indicated by arrows; (d) three-unit bridge placed 3 years ago with metal post and resin core in tooth 37 (#18). Note vertical root fracture indicated by the red arrow; (e) example of bridge restoration anchored by root canal posts, but with massive destruction of tooth structure due to recurrent caries; (f) *left*: inadequate root canal treatment with periapical radiolucent areas and resin composite restoration with two large metallic screw posts; *center*: same case after removal of the posts, endodontic retreatment; immediately after crown placement and 4-year follow-up showing periapical healing; (g) endodontically treated upper molar with large coronal tissue loss restored with bonded overlay composite restoration after preliminary margin relocation (Courtesy of Dr. T. Hollaert); (h) *left*: tooth 25 (#13) with vertical root fracture, 26 (#14) and 27 (#15) with mesial decay; *right*: same case after extraction of 25 (#13) and 27 (#15); crown preparation of 26 (#14) resulting in loss of tooth structure and pulpal inflammation requiring root canal treatment; the remaining composite material will have to be replaced; (i) *left*: tooth 26 (#14) with apical radiolucency on MB root, with a carrier-based fill in a pulp-floor perforation; *right*: tooth after endodontic retreatment, removal of the carrier, repair of the perforation, and lesion healing at the 1 year follow-up. The initial large composite restoration was maintained, and the access cavity filled by a direct composite

thin, fragile root walls with a bonded fiber post is possible, posts often weaken teeth due to nonphysiological forces exerted and further loss of dentin to prepare the post space. This leads to a more general transition in modern dentistry, now giving more importance to the tooth survival than to the restoration survival, the former being certainly more important from a patient perspective.

- *Can an endodontically treated molar with extensive tissue loss be restored solely by a bonded restoration? Are posts required for root canal-treated molars?*

Dental material technologies have evolved tremendously over the last decades. In particular, resin-based composites, which can be micromechanically and chemically bonded to the dental tissues, have become more and more reliable. By tradition, some dentists keep using metal posts to retain bonded composite restorations (Fig. 7.1f), while they accordingly should be replaced by fiber-reinforced resin-based posts, or possibly by no posts at all, either in case of a composite core covered by a full crown, or more recent adhesive strategies such as the so-called endocrowns or overlays in general (Fig. 7.1g).

- *Is adhesive technology sufficient to reinforce the tooth?*

The preparation of a full crown frequently results in additional removal of sound tooth structure (Fig. 7.1h). Fiber posts rely on luting resin that fills discrepancies, so that additional widening of the space becomes unnecessary. This is supported by the fact that a ferrule should be obtained on endodontically treated teeth. If a 2 mm ferrule can be obtained, a post is not needed to retain the buildup.

- *Is a ferrule a must in endodontically treated molars or is tissue preservation more important? Is partial restoration a valid alternative to full crown? Should the cusps be covered?*

A ferrule is generally admitted to be a must to prevent dislodging forces that will lead to coronal leakage. Cusps should be covered if structure loss is the size of an MOD preparation, or larger, and in undermined coronal walls. It should be considered in cases with loss of marginal ridges.

- *After endodontic (re-)treatment through an existing restoration, should the latter be replaced or repaired?*

Very often, endodontic treatment is performed through an existing restoration, either a crown or a filling (Fig. 7.1i), which in some instances are still serviceable. Here preservation of the previous restoration and the direct restoration of the occlusal cavity may suffice.

- *Can endodontically treated molars be part of a multiunit restoration?*

Despite the development of implant technology, endodontically treated teeth are still valid abutments in large-span restoration. This chapter focuses on single-tooth restoration for endodontically treated molars; detailed considerations for complex treatment plans likely require multispecialty discussion and are beyond the scope of this book.

- *Finally, how should a tooth with poor endodontic prognosis be restored?*

Despite the high success rate of endodontic procedures, some teeth are compromised due to problems such as broken instruments, perforation, or stripping, which may result in a poorer prognosis of the endodontic treatment. A direct restoration for teeth with a poor prognosis may be an appropriate solution.

This list of question is not exhaustive, and the answers not comprehensive, but they illustrate part of the decision-making process of the dentist restoring a molar after root canal procedure, which offers specific challenges (Box 7.1). This chapter will provide considerations to help practitioners answer these questions, and make the best possible clinical decision.

Box 7.1. Specific Properties and Findings Regarding Endodontically Treated Molars

- They differ from other tooth types, since they endure most of the vertical masticatory forces (100–300 N), and are protected from lateral forces by anterior teeth through anterolateral guidance.
- Root canal therapy itself does not seem to weaken dental structures; increased susceptibility to fracture appears to be due in majority to coronal and pericervical hard tissue removal, not to local changes of dentin characteristics.
- Three major technological developments are challenging the way endodontically treated molars have so far been restored:
 - Adhesive dentistry and the development of increasingly more reliable dental adhesives
 - The rise of digital technology, enabling the rapid and reliable design and manufacture of restoration in practice
 - The development of “Bio-”materials, with characteristics closer to the replaced tissues

7.3 Molar Restoration in an Era of Adhesive Dentistry, Digital Technology, and Biomaterials

Molar teeth endure the majority of the vertical masticatory forces, while most of the time, they are protected from lateral forces by anterior teeth through anterolateral guidance [10]. Occlusal loads sustained by molars during normal function range roughly between 100 and 300 N, while they do not exceed 50 N for premolars, and are lower yet for anteriors [11]. Higher values for maximum voluntary bite force have also been reported (500–800 N) [12], and can potentially reach even higher levels in case of parafunctions [10]. The variability is due to factors such as the type of food [13], age [12], or gender [14].

This underlines that restorative concepts should be specific to each tooth type, since each is submitted to very different challenges. Molar teeth are mostly submitted to axial forces of high intensity. Since root canal treatment weakens teeth due to loss

of structure, there is a particular need to adequately protect endodontically treated molars against tooth fracture. In this regard, it is to some extent surprising that most reviews and guidelines dealing with restoration after endodontic treatment propose general concepts of restoration for all teeth, and not specific to each tooth type [15].

Tooth weakening following endodontic treatment seems to have little [10] or nothing to do [16] with local changes of dentin characteristics following endodontic treatment (e.g., loss of moisture, use of chelators, irrigants, or medicaments). The major cause for increased susceptibility to fracture of endodontically treated teeth appears to be the loss of hard tissue [10]. Endodontically treated teeth indeed very often undergo additional dentin removal in the process of the restoration, for example:

- Creating post space
- Preparation for full crowns
- Occlusal reduction of thin dentin walls

In this regard, it is quite sobering that a major cause of further tissue damage is iatrogenic, especially given the efforts that are currently invested in developing strategies to regenerate dental tissues in order to strengthen tooth structure.

In light of this paradox, it is important to weigh the necessity or rationale of additional tissue sacrifice. The ultimate goal of dentistry is to retain a healthy complement of teeth for a lifetime; therefore, appropriate strategies should be “conservative” in order to control, rather than eliminate a condition, with existing tissues preserved as much as possible [17]. Indeed, it appears that habits, heritage, and/or traditions sometimes lead to a “conservative” dentistry in the sense of holding to traditional attitudes and values and cautious about change or innovation. In this regard, it is significant to consider certain advances and evolutions made over the past few decades that are of prime importance when considering the best way to restore endodontically treated molars: adhesive dentistry, digital technology, and biomimetics.

Adhesive dentistry started in 1955 with Buonocore, and bonding materials and strategies have since considerably evolved. Dental adhesives are now more and more reliable and predictable [18]. Specifically regarding restoration of endodontically treated molars, composite restorations enable us to do more and more without mechanical, nonadhesive, retention features such as cavity taper, grooves, or posts. Retention elements necessary in the era of silver amalgam are no longer needed, and this allows for more tissue preservation.

Another major breakthrough that is very likely to greatly affect tooth restoration is the advent of digital technology, specifically the CAD/CAM technology. Clearly, digital technology is changing dentistry and it is likely that the use of computers will replace manual tasks with the hope to get results faster and with fewer errors [19]. For endodontically treated teeth, with a likely further spread of CAD/CAM devices, clinicians may have the option of placing a permanent indirect restoration immediately after completion of endodontic treatment. As mentioned above, this approach is highly desirable in terms of endodontic success, as it limits or avoids temporary restoration failure.

Finally, another interesting evolution is the advent of “bio”-materials. Far more than just a buzzword, the addition of these three letters in front of the word “material” has a clear meaning, in that materials should not only be considered for their intrinsic qualities, but in the context of their integration in a living organism. Biomaterials are expected to behave and perform in a similar fashion as the tissue they replace. Therefore, their characteristics should be as close as possible to the tissues replaced. This should be kept in mind by clinicians when choosing the best strategy and most adapted material for tooth restoration. The current trend is to use materials whose mechanical properties are as close as possible to the dental tissues they replace [20], this is sometimes implied by the expression “biomimetics.”

For example, an important property to consider is the elastic modulus, which is the tendency of a material to be reversibly deformed when a force is applied to it. A significant difference of elastic modulus between the replacement material and the tissue replaced might result in inappropriate interfacial stress generation. The elastic modulus was determined to be about 19 GPa for dentin and 80–94 GPa for enamel [21]. In comparison, it is much higher in metals and other dental materials, for example, about 110 GPa for titanium, 200 GPa for stainless steel, 200 GPa for zirconium, and 300 GPa for aluminum oxide. This major difference in modulus suggests that metal posts in roots should be used with caution. In contrast, the elastic modulus of fiber posts ranges between 10 and 25 GPa, which is much closer to that of dentin [22].

The elastic moduli of currently available materials for coronal restoration are as follows: 10–15 GPa for hybrid resin-based composites [23], 10–17 GPa for glass ionomer [24], about 20 GPa for amalgam [25], 71 GPa for feldspathic porcelain, and 224 GPa for zirconia [26]. Interestingly, it has been shown that an increase in elastic modulus of the restoration from 5 to 20 GPa actually results in a 30% reduction of stress at the tooth-restoration interface under occlusal load [27]. Hence, it seems to make sense that the deformation under load of the restorative materials should be as close as possible to that of the tooth, which according to the above values points to resin-based composites for dentin, and feldspathic porcelain for enamel. As illustrated, many clinical situations show that a lack of respect of these biomimetic concepts can result in a failure. Nevertheless, it is also possible to find other clinical cases where these concepts of integration are not respected, but where the restoration can still be considered a clinical success. In fact, clinical experience seems to illustrate that in dentistry, a treatment might be successful despite what we do, not because of what we do. Therefore, and given the lack of clear clinical evidence, risks pointed out by *in vitro* data need to be carefully appraised when restoring root canal-treated molar teeth.

7.4 Objectives of the Restoration of Endodontically Treated Teeth

Generally, goals of the restoration of teeth after endodontic treatments can be summarized in three main objectives: to restore tooth functions, to prevent infection or reinfection of the root canal space by providing a fluid-tight seal and to protect the remaining tooth structure against further tissue damage (Box 7.2).

Although these general objectives are not specific to molars, the latter appear to be the most commonly extracted teeth among endodontically treated teeth (81 %) compared to premolars (16 %) and incisors/canines (3 %) [28]. Here, particular attention should be paid to the reasons for extraction, which were mainly nonrestorable caries (>60 %), far ahead of persistent endodontic failure, nonrestorable root or cusp fracture, and iatrogenic perforation, which were in that study cited in about 9–12 % each.

The major tooth functions that need to be restored include mastication, occlusal stability, and protection of the marginal periodontal tissues by providing appropriate contact points with neighboring teeth. At the same time an esthetic result must be achieved, while this is typically less critical in the posterior than in the anterior dentition. The restoration of these functions is not specific to endodontically treated teeth, but common to all damaged teeth and will not be the focus of this chapter.

The second objective, to prevent infection or reinfection of the root canal space, is of prime importance regarding the long-term success of endodontic treatment, as will be discussed in the next section.

Finally, the third objective, to protect the residual tooth structure against further tissue damage (cariou or noncariou causes), is particularly relevant to endodontically treated teeth. In cases of structural loss after caries removal or preparation, endodontically treated teeth require protection against fracture. This third objective is particularly important and critical in molars, since they receive most of the masticatory forces, as will be described further. Hence, this chapter will propose considerations to prevent this major cause for endodontic treatment failure.

7.5 Fluid-Tight Seal of the Root Canal System

After completion of endodontic treatment, the priority is to establish an adequate coronal seal to prevent any infection or reinfection of the root canal space. This important aspect is not specific to molars but common to all types of teeth. Is the

Box 7.2. Objectives for the Restoration of Endodontically Treated Molars

- To restore function
 - Mastication
 - Occlusal stability
 - Contact points with neighboring teeth to ensure protection of the marginal periodontal tissues
 - Aesthetics (to a lower extent in the posterior sector)
- To prevent the infection or reinfection of the root canal space by providing a fluid-tight seal
 - An adequate tooth restoration increases the chances of healing when combined with an adequate root canal treatment and obturation
- To protect the remaining tooth structure against further tissue damage, in particular tooth fracture
 - Increase of tooth longevity

quality of coronal restoration of equal importance as the quality of the root canal filling regarding the outcome of endodontic treatment? This question has been the subject of debate in the endodontic literature (Fig. 7.2). The discussion arose from a report that cases with good coronal restoration, regardless of the quality of endodontic treatment (conditions 3 and 4 in Fig. 7.2) were associated with a significantly higher success rate based on the absence of periapical lesion in a radiograph than the opposite situation (80 %, conditions 2 and 4 in Fig. 7.2) [29]. The same authors find, comparing the worst- and best-case scenarios (situations 1 and 4 in Fig. 7.1, respectively), success rates of about 20 % and 90 %, respectively.

Gillen and others [30] conducted a systematic literature review and meta-analysis of all papers published on this topic since the original work by Ray and Trope [29]. Based on new statistical analyses based on data from nine papers, they concluded that a better treatment outcome can be expected when performing both high-quality root canal treatment and restoration (situation 4 in Fig. 7.2) compared to either insufficient filling or root canal treatment (situations 2 and 3 in Fig. 7.2), where no significant difference in the odds of healing was observed [30].

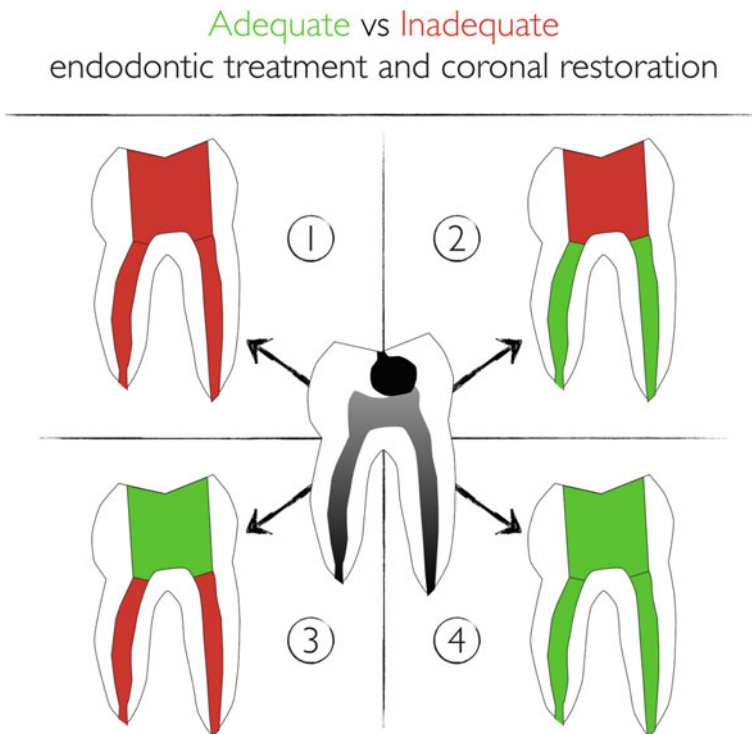


Fig. 7.2 Schematic diagram of possible clinical situations when restoring a root canal-treated molar (*center*). Clinical outcomes shown in cases 1–4 depend on the quality of both endodontics and restorative work, with better outcomes when both parts are done to quality criteria (*red/green*). See text for more details

In a best-practice approach, since it is clear that the highest treatment quality in both aspects results in the best chances of success, the joint and coordinated efforts of both endodontists and restorative dentists are necessary to achieve the best possible outcome. Importantly, these elements point out to endodontic specialists that a quality restoration is important for success of the endodontic treatment he/she performed. As mentioned above, a major reduction of survival after endodontic treatment is anticipated for teeth restored with temporary restorations compared to the teeth receiving a permanent restoration [1].

Along the same lines, *in vitro* data have pointed out that temporary materials (neither Cavit, conventional glass ionomer, or a combination of both) were unable to prevent bacterial leakage over a 2-month period, whereas a bonded-resin-based material was able to do so [31]. This problem becomes particularly striking, considering that nowadays the endodontic and restorative phases are more often in the hands of two different practitioners and treatment decisions are influenced by insurance coverage also. Hence, the joint and coordinated efforts of both endodontists and restorative dentists are necessary to achieve the best possible outcome for the patient.

Even when under the control of one general dentist, endodontic and restorative procedures are usually performed in two separate appointments. Therefore, one needs to consider approaches that can ensure immediate, reliable, and definitive sealing of the root canal system, very likely through an adhesive procedure. One possible approach is the one proposed by Magne's group, called immediate dentin sealing (IDS). This procedure may consist of immediate placement of a bonding system at the surface of freshly cut dentin and was demonstrated to improve bond strength of indirect restorations as compared with delayed bonding procedure at the next appointment, when placing the restoration [32]. Hence, in the context of restoring endodontically treated teeth, IDS has a dual advantage: providing an immediate seal, and improving bond strength for the restoration to come (see Box 7.3). The additional placement of a thin layer of flowable resin-based composite at the entrance of the root canals and on the pulp chamber floor can also be recommended. It must finally be kept in mind that IDS requires the final restoration to be placed within the next 2 weeks after bonding placement. After longer periods, a reduction of the cohesion between bonding and resin-based composite was indeed observed [33], possibly due to the decay of free radicals within the adhesive layer, which reach undetectable levels in less than 1 month after light-curing [34]. An additional procedure including the placement of a silane agent is then required, as well as a fresh layer of bonding agent [35].

Box 7.3. Sealing the Endodontic Space

- The combination of both good endodontic treatment and good coronal restoration results in significantly better endodontic treatment outcome
- The placement of an adhesive resin-based composite layer at the entrance of root canals and over the whole surface of pulp-chamber and cavity immediately after completion of endodontic treatment represents the best

way to prevent reinfection of the root canal system. This initial layer will serve as substrate for the subsequent adhesive restoration.

- Immediate dentin sealing (IDS) is indicated first to reduce the risk of contamination of the root canal system associated with temporary restorations, and second, to increase bond strength of the future coronal restoration.
- Ideally, the endodontist could/should take care of the placement of this initial layer. The subsequent placement of the permanent restoration as soon as possible requires agreement between both the endodontist and restorative dentist, both on best-practice restorative procedure and sequence.

As mentioned earlier, one of the objectives of the restoration of endodontically treated teeth is to protect the remaining tooth structure against further tissue damage, in particular tooth fracture. The major cause for increased susceptibility to fracture of endodontically treated teeth is the loss of hard tissue; it is important to weigh the impact of caries removal, preparation for coronal restorations, access cavities, or root canal preparation on tooth stiffness. This issue was evaluated in premolars in the classic work by Reeh and others [36], and the residual tooth stiffness relative to an unaltered tooth (100 %) was sequentially: 95 % after access cavity only, 80 % after occlusal cavity preparation, 54 % after two-surface cavity preparation, 37 % after MOD cavity preparation, 33 % after access cavity preparation, 34 % after root canal instrumentation, and only 32 % after root canal obturation.

In molars, the average residual tooth stiffness was reported to range between 81 and 95 % after an MO cavity preparation, and between 60 and 61 % after an MOD cavity preparation, depending on the cusp considered [37]. This is lower than what was observed for premolars, although it is problematic to directly compare the values of two separate studies. Nevertheless, it may be concluded that the reduction in tooth stiffness results mainly from cumulative tissue loss at the coronal level. To address this tooth weakening, three important clinical concepts need to be considered: the ferrule effect, the placement of post(s), and cuspal coverage.

7.6 The Ferrule Effect in Molars

The dental ferrule refers to a circumferential band of dentin of at least 1–2 mm of dentin coronal to the margin of the preparation for a full crown (Fig. 7.3). It has been suggested that the presence of a ferrule may reinforce endodontically treated teeth, the “ferrule effect,” especially in teeth restored with cast post and core [38]. It was also observed that an adequate ferrule lowers the impact of the other factors (post and core system, luting agents, or crown material) on the survival of endodontically restored teeth [39].

Most research was done with single-rooted teeth and comparatively little data are available on molars. In the two major literature reviews that focus on the importance of the ferrule effect, one did not mention a single work devoted to molars [38] and the other reported the critical need for more clinical trials that investigate an effect on molars [39]. Only one clinical study focused specifically on endodontically treated, restored molars, and concluded that the amount of tooth structure available for ferrule (evaluated retrospectively from bitewing radiographs) may not be a significant prognostic parameter [40]. However, two other clinical studies included molars [41, 42] and both reported improved survival for teeth with ferrule (93 % at 3 years [41] and 98 % at 5 years [42]) compared to teeth without ferrule (74 % [41], 93 % [42]). Notably, in these two studies molars represented less than half of the teeth and a minority of the failures [42].

Therefore, while from a mechanical standpoint a ferrule is logical and recommended whenever possible, it is somewhat speculative to generalize and recommend ferrules for all molars based on these data alone. Moreover, it should be kept in mind that occlusal loads on molars are mostly axial, whereas the ferrule effect has mostly been demonstrated to be effective in protecting single-rooted teeth against lateral and oblique forces.

Interestingly, in an *in vitro* study comparing the importance of ferrule in endodontically treated molars restored with full metal crowns, it was reported that the presence of a 2 mm ferrule was a determinant factor on the fracture resistance and fracture mode. However, the forces required to induce fracture were well above the

The ferrule effect in molars

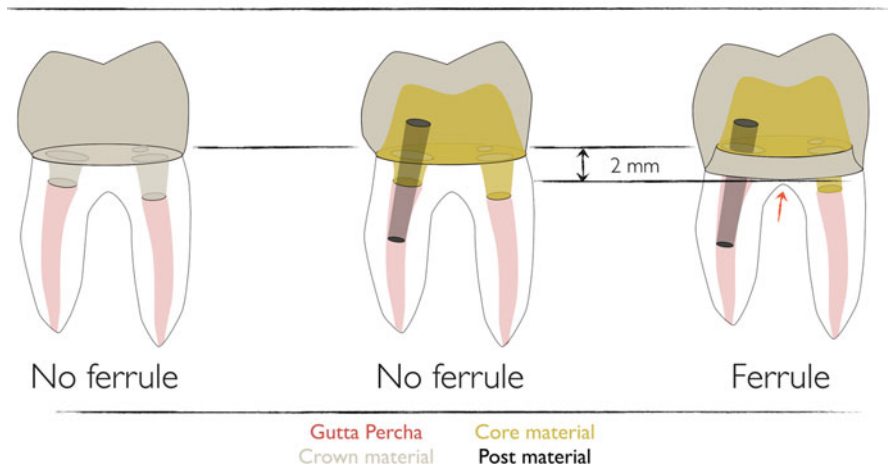


Fig. 7.3 From left to right, an endocrown (no ferrule), a post and core (either fiber post and resin composite core or metal cast post and core) covered by a full crown (no ferrule), and a crown covering a post and core with apical extension of preparation margin, providing a 2 mm ferrule. The red arrow symbolizes the risks the apical extension may represent, here regarding the furcation, but in general regarding the respect of the biological width space

physiological forces, or even parafunctional levels, either in the ferrule group (2035–2934 N) or in the no-ferrule group (1528–1879 N) [43]. As stated before, results based on one type of teeth should no longer be generalized to all endodontically treated teeth without any distinction, as it is often the case in the literature.

Hence, given the lack of solid evidence in favor of the need of ferrule in molars, it is questionable whether it should be achieved at the expense of the remaining tooth structure (Fig. 7.3) and it is questionable to make the decision to extract a molar based solely on the lack of ferrule. Interestingly, when dentists are made aware of the additional tissue loss (3–45 %) associated with complete versus partial coverage restoration in molars, over 50 % of the clinicians altered their initial choice of restoration design from full to partial coverage [44]. Besides, the preparation of a ferrule at any cost in case of little remaining coronal tissue might be associated with additional problems. Notably, the subgingival margin placement can lead to a reduction of the biologic width space (distance between crown margin and alveolar crest) below the required 2–3 mm and to difficulties with the margin impression, excess luting cement removal, and cleaning of the area by the patient. The alternatives, crown lengthening or orthodontic extrusion, represent additional costs and delay for the patient; details of these procedures are beyond the scope of this text. Given the significant progress made in adhesive dentistry, preservation of coronal tissue should be contemplated instead of ferrule preparation in molars, and alternative approaches such as so-called endocrowns should be considered, as will be described further.

Admittedly, endodontic treatment in molars is typically rendered when a major portion of enamel and dentin has been already lost due to caries. Moreover, there are molars that may have a guarded prognosis (see also Chaps. 2 and 8) but still require a restoration (Fig. 7.4). Obviously, there is a range of clinical scenarios in the restoration of molar endodontics, and a variety of possible solutions will be discussed below.

7.7 Post Placement in Endodontically Treated Molars

The question whether post placement is indicated in the restoration of endodontically treated teeth is quite difficult to answer with a clear *yes* or *no* based on the available literature. There are numerous factors involved, such as the post material or diameter, the quality of the bonding interface between post and dentin, the core material, the crown material, the amount of residual tooth structure, and others. This makes studies difficult to compare, and probably accounts for the contradicting results found in the literature. Importantly, tooth type is a major factor to consider, and most of the studies evaluating post placement were done on single-rooted teeth. The results obtained for incisors or premolars are not directly transferable to molars, and each tooth type has specific characteristics, notably the major differences in occlusal load intensity and directions [45]. Hence, only studies involving molars will be considered here. As regards the type of post, fiber-reinforced composite posts present characteristics that support their use instead of metal posts, since as

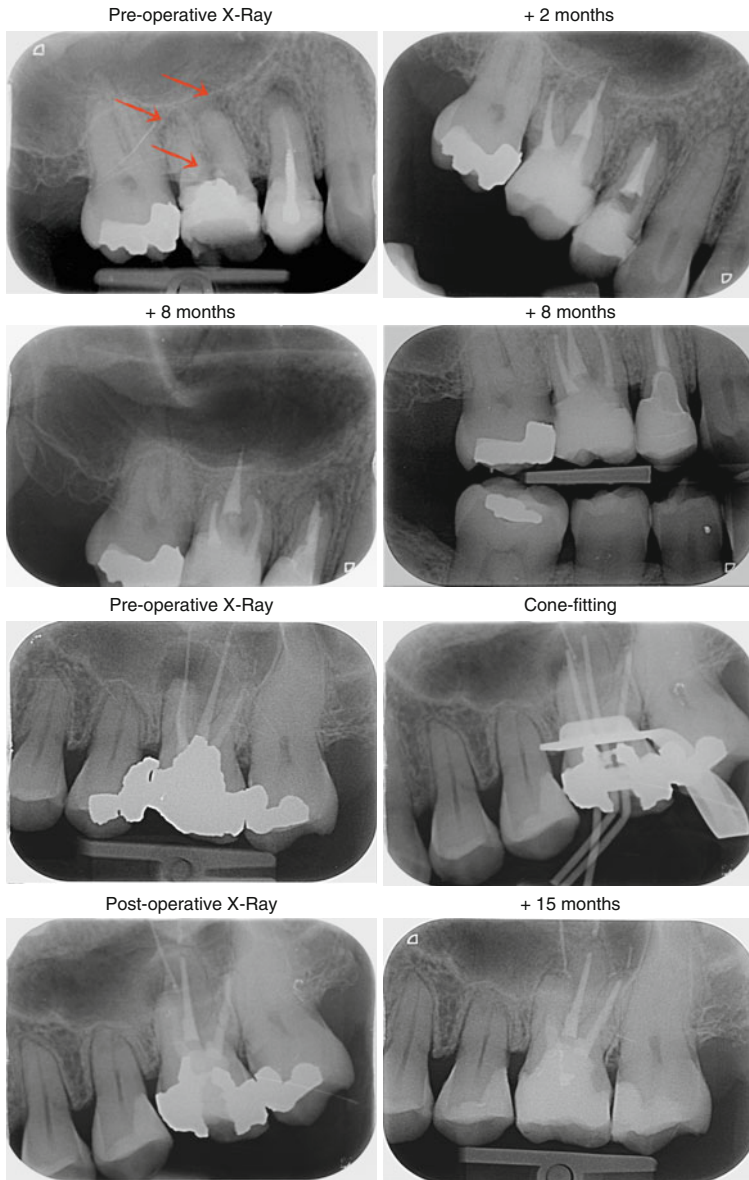


Fig.7.4 (a) Teeth 15 and 16 (#4, 3) with periapical lesions, 16 (#3) with a perforation of pulp chamber floor (arrows). Both teeth received root canal (re-) treatment, and the perforation of tooth 16 (#3) as well as the vestibular canals were obturated. Direct composite restoration on tooth 16 (#3) and composite endocrown placed on tooth 15 (#4). Teeth are clinically asymptomatic at 8 months, and there are no signs of pathosis either in the periapical or in the furcal regions. (b) Tooth 26 (#14) presenting with a large periapical lesion with overextended fill and inadequate coronal obturation. The apical size of the MB root canal was very large and an apical plug was placed, followed by the placement of a direct composite restoration. At the 1-year follow-up, the tooth is asymptomatic and there is evidence of bone fill; the patient decided to keep the composite restoration

already mentioned their elastic modulus is much closer to dental tissues, while at the same time displaying a fracture strength of 600–1100 MPa [22, 46], in other words, lower than metal posts (around 1400 MPa) but still much higher than dentin (200 MPa) [46]. It has also been suggested that the consequences of root fracture are more severe with metal posts than with fiber-reinforced composite posts [47]. In addition, the latter can be bonded to both root canal surface and resin-based restorative materials, which is not the case of their metallic counterparts. Hence, even if metal posts have been used for years in the clinics, the present chapter will only address the interest of using or not fiber posts in molar restoration.

7.8 Bonding in the Root Canal: The Worst-Case Scenario

Even in the event that a post is required (which as will be discussed below, does not seem to be clearly the case in molars), several aspects make its bonding procedure difficult.

First, it is not trivial to clean the root canal dentin and prepare it for bonding. Following endodontic treatment, obturation, and post space preparation, large areas of the root canal walls were indeed shown to be covered with smear layer, debris, and materials (sealer or gutta-percha) [48], which interfere with the post bonding efficiency. Since NaOCl was also demonstrated to decrease the bond strength [49], there may be an interest of neutralizing this effect by use of antioxidant such as sodium ascorbate [50, 51]. In Lai's work, control of abundant rinse with water prior to bonding is lacking, while in Vongphan's paper, there is no significant difference between control and when abundant water rinse is performed after NaOCl. Hence, it is still unclear whether or not this additional step is really beneficial.

Second, the ease of bonding procedure (etching, rinsing, primer application, drying, bonding application), resin-material injection, and photopolymerization is not as straightforward in the root canal space as in the coronal portion, which can result in lower bonding quality, more voids, or suboptimal resin polymerization [52].

Third, another major limitation of the bonding procedure in the root canal is related to the well-known polymerization shrinkage of resin-based composite, and the resulting stresses generated on the surrounding tooth structure. If the shrinkage stress exceeds the bond strength of the adhesive system to dentin, gaps form along the interface [52]. The magnitude of shrinkage stress is related to a parameter called "C-factor," which refers to the ratio of the bonded surfaces to the unbonded ones [53]; the higher the C-factor, the greater is the shrinkage stress [54]. Significant bond strength reduction is already observed when increasing C-factor from 1 to 3 [55], and the C-factor values in root canals are expected to be much higher, since theoretically every dentin wall can be considered to have an opposing wall, and therefore very few surfaces are unbonded [52]. It is interesting to notice that the addition of a post as compared to filling the root canal with only resin results not only in a massive increase of C-factor, but also to a significant reduction of micro-tensile bond strength to root canal dentin (7.3–9.6 MPa with a post compared to 20.4–39.8 MPa without a post) while variations of resin volume by modifications of root canal width did not seem to affect bond strength [56].

Finally, higher bond strength values have been reported in coronal compared to apical dentin [57]. This questions the interest of preparing long post spaces, as compared to using only the coronal portion of the root canals, such as in the endocrown strategy, which will be described further.

All these limitations explain why bonding posts in the root canal is probably the worst-case scenario, with a particularly important risk of debonding and gap formation between post and root canal dentin, and low dentin bond strength. Additionally, there is concern of the stability of this little predictable bond with time, especially after repeated thermal, chemical, and mechanical stresses [58]. Indeed, Bouillaguet et al. [57] state that “clinical failure is not seen when sufficient coronal dentin is available because the restoration does not rely heavily on the bonding of the post to the root dentin.” This then logically questions the rationale of using posts to increase the restoration retention and/or reinforce the teeth.

7.8.1 Do Posts Reinforce Endodontically Treated Molars?

Based on *in vitro* studies, it is generally considered that the use of posts does not increase the fracture resistance of endodontically treated teeth [3], but these data are mostly based on metal post restorations, which do not bond to the dentin structure. Hence, it is worth revisiting this question with fiber-reinforced composite posts, and specifically regarding molar restoration.

Unlike for metal posts, *in vitro* data seem to highlight a possible strengthening effect of fiber posts on endodontically treated teeth. Again, a large majority of works addressing the use of posts to reinforce teeth included single-rooted teeth. Let us consider those specifically focused on molars. In an *in vitro* work quoted earlier regarding the role of ferrule, a significantly higher fracture resistance was observed for teeth with posts (around 2900 N with ferrule, around 2000 N without ferrule and no significant difference between glass fiber and cast posts) than without posts (around 2000 N with ferrule, around 1500 N without ferrule).

Cast posts were associated with the highest rate of nonrestorable failures (80–100%), whereas nonrestorable failures were reported in only 10–30% of teeth with fiber posts or without posts (25° load direction) [43]. In another *in vitro* study, it was concluded that fiber post placement does not increase fracture resistance of endodontically treated mandibular molars with one or two remaining cavity walls in case of indirect composite overlay placement (fracture resistance around 1000 N for restored teeth after fatigue compared to 2992 N for intact teeth) [59]. However, they also observed that fiber post insertion could lead to more restorable fractures in case of extra axial loads (65% nonrestorable fractures without post and 30% with post) (45° load direction). Similar observations were again made when comparing different onlay materials (gold, composite, and ceramics) on MOD cavities with buccal and lingual cusp coverage, that is, fracture resistance ranging from about 1600 N (for ceramic and composite inlays) to 2900 N (for gold inlays), again well above physiological and parafunctional forces in all cases [60]. The effect of fiber post placement was not significant for composite or ceramic onlays, but well for gold

onlays (about 2300 N without post and about 2900 N with post). Another study investigated direct composite restorations of root canal-treated molars with or without fiber posts, and reported fracture resistance ranging from 700 to 1600 N, depending on the number of remaining cavity walls [61]. They concluded that fracture resistance is not affected by the presence of fiber posts, but depends mostly on the number of residual walls, with a significant reduction of fracture resistance observed with less than two remaining walls. A higher proportion of nonrestorable failure was observed for restorations with fiber posts (0–50%) than without (40–70%). Another study by the same group investigated fracture resistance of root canal-treated molars restored with zirconia crowns, with different degrees of coronal tissue loss. They reported a significant improvement in fracture resistance with fiber posts (average ranging from about 1200 to 1450 N, with 20–33.3% of nonrestorable fractures) compared to without posts (average ranging from about 1150 to 1250 N, with 6.7–20% of nonrestorable fractures) [62].

In summary, based on *in vitro* studies, there is no consensus on the effect of fiber posts on endodontically treated molars, since some of them support a reinforcement and others do not. The common finding of all these *in vitro* data points is that failure occurs above normal intraoral forces, or even parafunctional forces which have a range from 700 to 1000 N in the posterior mandible. Hence, it is questionable whether or not the differences observed well above physiological forces, as well as the conclusions regarding restorability after failure, are in any way related to the clinical reality. All the conditions might very well be equivalent under physiological forces.

Considering clinical data, a meta-analysis on the subject concluded that the use of post retention had no significant influence on tooth survival after endodontic treatment, and a substantial heterogeneity among the included studies was deplored [7]. By contrast, a prospective study on tooth survival by the same group reported that teeth with cast post-and-core restorations were 2.6 times more likely to be extracted [1]. Since almost 90% of the extracted teeth with cast post and core were premolars and molars, they concluded that the use of such retention systems should better be avoided in posterior teeth, and replaced by alternative treatment options [1]. They also reported that despite the large number of teeth included (1,617 teeth), the statistical power was not sufficient to test the interaction between factors, notably tooth type or post and core material, due to the small number of failures. The lack of consideration of tooth type in the majority of the clinical studies on endodontically treated teeth survival is a major limitation to determine whether or not the placement of posts participate in the reinforcement of endodontically treated molars specifically. As pointed out earlier [3], more clinical studies taking into account tooth type are required to determine whether or not a post should be used.

Among the few studies including molars, two reported no influence of post placement on restoration survival, one comparing at 5 years between cast post and core, direct post and composite core restoration and post-free all-composite core restorations [42], and the other direct composite resin-core-crown reconstructions with or without prefabricated metal posts [63]. However, the use of metal posts with composites is not an appropriate association, as mentioned earlier, and molars represented only 20–25% of the teeth in both studies.

Several other studies investigating fiber posts included molars, but all were lacking appropriate controls, that is, molars with comparable tissue loss and without fiber post were not included. For example, Mancebo et al. evaluated the survival of root-treated teeth restored with fiber post and composite core covered by a crown, but molars represented only 18 % of the teeth included, only 3/14 failures, and most importantly no control without posts were investigated [41]. Another retrospective study evaluated the long-term performance of three types of fiber posts after a service period of 7–11 years. Almost 1,000 posts were in the study, with a total of 79 failures, 39 for endodontic reasons and 40 actual restoration failures. It was concluded that fiber posts “*may be* used routinely for restoring endodontically treated teeth” [64]. The evidence provided is again insufficient to determine if fiber posts *should* be used, since again no control without posts were considered, and only about 20 % of the teeth were molars, which represented only 13 of the 40 restoration failures, all due either to post debonding or to crown dislodgement.

In fact, to clearly determine whether fiber posts participate in endodontically treated molar reinforcement, a randomized clinical study would need to evaluate restoration with and without posts, *for a given tooth type, and for similar levels of tissue destruction*. To our knowledge such study does not exist for molars. This is further underlined in a prospective study evaluating the risk factors for failure of glass-fiber-reinforced composite post restorations, which concluded that tooth and restoration type as well as remaining cavity walls were significant predictors of endodontically teeth restoration failure [6]. In their work, a two to three times higher failure rate was observed in restorations placed in incisors or canines compared to those placed in premolars or molars. Though, as mentioned by the authors themselves, some limitations such as small sample size and small number of failures led to small statistical power. Once more, no control without posts was considered, and no specific focus was put on molars. The authors explain the higher failure rate in anterior teeth by the fact that fatigue fractures are caused by tension stress and not by compression, and the anterior region is therefore considered to be an area of higher risk, compared to molar areas, which bear less nonaxial forces. However, their results are in contradiction with the meta-analysis by Ng et al. [7] and the practice-based research by Skupien et al. [4], which report increased survival of nonmolar endodontically treated teeth, irrespective of the presence or absence of a post.

Bitter et al. considered the level of tissue loss and compared restorations with or without fiber posts (mean observation period of 32.4 months, 90 patients, 120 teeth). They concluded that fiber post placement is useful to reduce restoration failures of endodontically treated teeth with no remaining coronal wall, whereas no significant effect was shown in teeth with one or more remaining coronal walls [65]. Unfortunately, tooth type was again not considered, and the low number of failures of molars restored without posts (3/37) and with posts (0/25), which again is insufficient to conclude regarding the advantages of using posts in molars. The result of a recent practice-based study (almost 800 teeth, mean observation time 4.5 years, 50 % were molars, 700 without posts, 100 with post, post type not specified) concluded that the use of posts had no significant effect on either tooth survival or restoration success [4], though again the influence of post specifically on molar teeth could not

Restorative options in endodontically-treated molars with large tissue loss

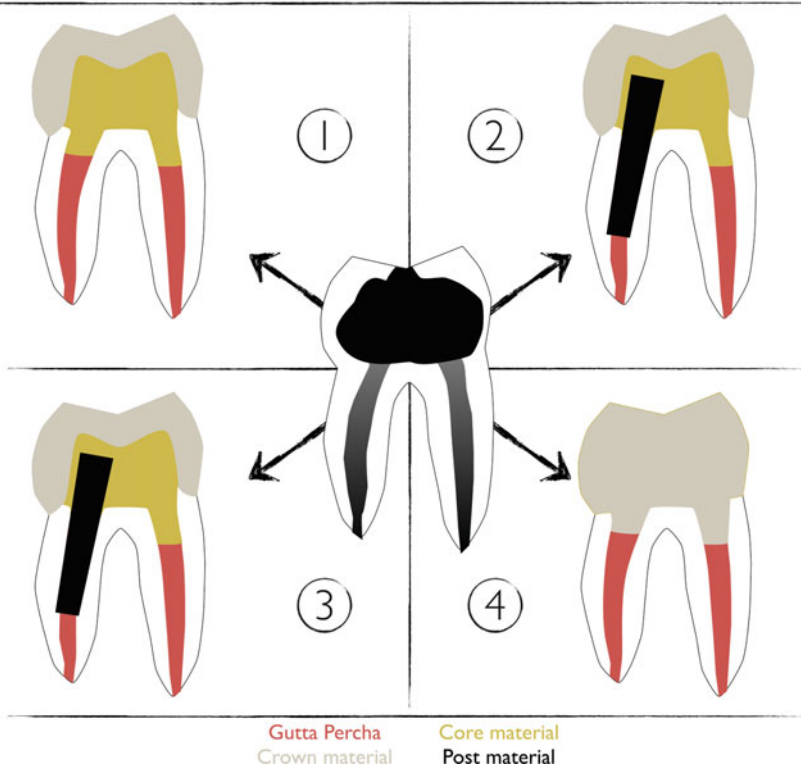


Fig. 7.5 Schematic of the various restorative options when restoring endodontically treated molars with large tissue loss. (1) No post placement, core buildup without root canal anchorage, and full crown. (2) No post placement, core buildup with root canal anchorage, and full crown. (3) Placement of one or several post(s) in the root canals and core buildup, or placement of a cast post and core, and full crown. (4) Endocrown

be evaluated. The authors bring up the fact that the longevity of teeth and restorations do not only depend on the restorative considerations but also on factors related to the practitioner and the patient [66]. This is a very important aspect, since, as mentioned by Skupien et al., the dentist's decision making may for example result in teeth with a more important coronal breakdown receiving a post [4].

In summary, it appears that clinical data are insufficient to justify the use of posts to reinforce endodontically treated molars. As stated by Al-Omiri and others, the guidelines are mainly based on in vitro studies and only limited in vivo material [2]. More long-term randomized controlled clinical trials taking into account tooth type and the loss of coronal structure are clearly required to reach an irrefutable conclusion regarding the use of posts to prevent fracture of endodontically treated molars [2].

7.8.2 Do Posts Increase Restoration Retention?

Posts are generally suggested to increase retention in case of large hard tissue loss, usually with less than two remaining cavity walls [3]. Several restorative strategies are in fact possible, as summarized in Fig. 7.5.

To our knowledge, there is no clear consensus on which of these strategies provides the best restoration retention. A first issue is the variability of materials used for each of these strategies. Considering Fig. 7.5, it is clear that depending on the materials selected for the crown, the core, and the post, different behaviors and performances can be expected. Specifically, in situations 1–3, the properties of the core composite material, which will account for an important part of the flexural behavior of the coronal part of the tooth, may vary significantly (e.g., flexural strength from 57 to 125 MPa, and elastic modulus from about 3 to 13 GPa) [67]. Often, flowable dual-cured or self-cured materials are used by practitioners both for post bonding and for a fast one-step core buildup.

The mechanical properties of these materials are often inferior to those of highly filled light-cured composites. In addition, the multiplication of interfaces (Fig. 7.5, situation 3: dentin-post, dentin-core, core-crown, etc.) might increase the probability of flaws, and partial restoration debonding. On the contrary, the endocrown (Fig. 7.5, situation 4) allows the use of a single high-performance material (indirect composite or ceramics) and a single interface (crown-dentin). This variability of materials and interfaces between the different restorative options might account for the fact that the most frequently reported reasons for clinical failures of fiber post restorations were post debonding and post fractures, in some cases with core fracture [65]. This is probably linked to the difficulty to predictably bond in the root canal, as it was earlier alluded to. Since the loss of restoration retention was associated in most cases with the presence of little remaining coronal tissue, the authors concluded that the mechanical failures were due to the lack of coronal tooth structure [65]. These observations clearly question the added value of fiber posts, since the lack of tooth structure is precisely when the use of posts is recommended. Unfortunately, no control without post was included and it is therefore unclear whether posts are really appropriate to improve restoration retention. Finally, as previously mentioned regarding the risk of fracture, there are major issues accounting for the absence of consensus regarding the use of fiber posts, mainly the lack of consideration of tooth type and level of tissue loss in the majority of the clinical studies, as well as the limited number of failures in some studies.

Hence, even if it cannot be completely excluded that fiber posts may participate to increase restoration retention in molars, the evidence is very weak. It seems that endodontically treated molars rarely, if ever, require a post for restoration retention [58]. First, molars provide more coronal tooth structure, hence a larger bonding area as compared to anterior teeth and in general a large pulp chamber. Second, as already mentioned, they are mostly submitted to vertical forces [58, 68], while fiber posts may resist mainly against lateral forces. Third, the use of adhesive strategies has become more and more reliable (see Fig. 7.6); the necessity of using posts is therefore questioned by current *in vitro* data and clinical results using adhesive restorative strategies.

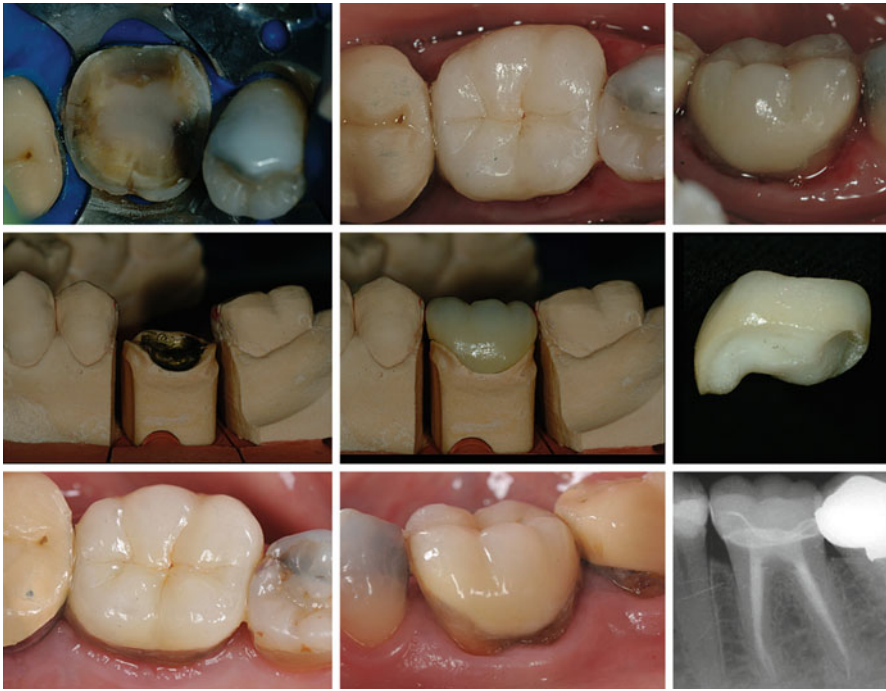

Fig. 7.6 Placement and 8.5-year follow-up of an all-ceramic crown bonded on flat occlusal surface (Courtesy of Dr. A. Mainjot)

7.9 A New Treatment Option: The Endocrown

The absence of requirement of post placement in molars is further highlighted by recent promising results reported for a new type of adhesive restoration called the “endocrown.” Endocrowns are in fact large adhesive inlay-onlay restorations used to restore endodontically treated teeth with large tissue loss. They can either extend to the pulp chamber when present (Fig. 7.7), or in case of very shallow or inexistent pulp chamber, they may also be bonded on an almost flat surface after obliteration of the root canal entrances (Fig. 7.6).

According to in vitro data, endocrown restorations in molar teeth are quite promising compared to conventional crowns associated with fiber posts. Finite element analyses in a molar model revealed lower levels of stress (compressive, tensile, and shear) in teeth restored with ceramic endocrowns than in those restored with either fiber or cast post and a conventional full crown [69], the highest stresses occurring in teeth restored with fiber posts. In any case, contact stresses around the restorations were not higher than 1.6 MPa, which is much lower than the bonding strength reported between the bonding system and tooth tissues (around 30 MPa). Hence, according to the authors, ceramic endocrowns in molars have a low risk of fracture or debonding under physiological loads [69]. They further underline the interest of such adhesive restorations in molars by stressing first their minimally

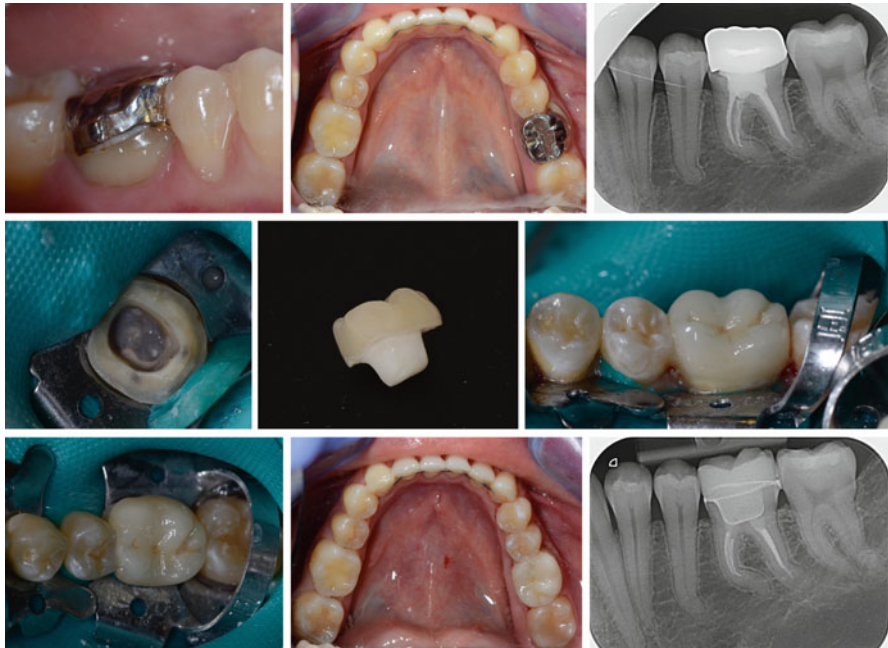

Fig. 7.7 Replacing an inadequate metal crown by a ceramic endocrown on tooth 46 (#30) (Courtesy of Dr. B. Lambert)

invasive preparation of tooth structures and lower risk of root damage, and second, the more favorable ratio between crown height and width in molars, which leads to smaller forces exerted on restorations compared to incisors for example, with a much larger restoration-tooth interface. Of course, any flaw within the material can increase the risk of restoration fracture, and any procedural mistake during the bonding procedure can favor debonding. Moreover, the reduction of bond strength with time under load and temperature changes, which is material specific, needs to be kept in mind [70]. In fracture strength experiments, ceramic endocrowns were shown to be more resistant to compressive forces than teeth restored with fiber posts, composite core, and conventional full crowns. In both cases, failure occurred by fracture of the tooth in most cases [71]. Again, fracture strength values were higher than physiological forces and the compression load was applied with a 45° load direction, which may not correspond to most situations in the molar region, where most forces are probably axial.

These promising *in vitro* results are confirmed by clinical studies. One study investigated CAD/CAM ceramic crowns placed in posterior teeth ranked in three different groups with various stump height (bondable and retentive surface) with one group of 70 molars that had only a pulp chamber retention cavity [72]. Among the molars, no significant difference in survival was observed between the three groups, with a survival of up to 94% after a mean service life of 55±15 months. As mentioned by the authors, comparable survival rates have been previously documented for conventional metal-ceramic or all-ceramic crowns. Of the 70 molar endocrowns,

nine were lost due to adhesive failure, two because of vertical root fractures (similar same as conventional crowns), two for other reasons. In that study the major cause for failure was debonding, which is a restorable failure. Interestingly, while molars in the classic and reduced groups presented some fracture of ceramics (five molars), no ceramic fracture could be observed in the endocrown group [72]. This is in accordance with *in vitro* data, reporting superior fracture resistance of monolithic ceramic restorations compared to their porcelain-veneered counterparts [73].

In another clinical study including mostly molars (142 molars, 40 premolars), it was reported that large ceramic bonded restorations placed in endodontically treated teeth showed a similar failure rate compared to those placed in vital teeth (5-year failure rate of about 10% for endodontically treated teeth and about 7% for vital teeth) [74]. A 15-year prospective study by the same group included different groups depending on the degree of tooth preparation, among which 14 premolars and 14 molars were endodontically treated, without retention or post and core treatments (64 premolars and 188 molars total) [75]. Contrary to the short-term study, it was reported that ceramic restorations failed significantly more on nonvital teeth (39%) than on vital teeth (21%) after a mean observation period of about 13 years. Interestingly, the main reasons for failure were restoration loss and ceramic fracture (without differentiation between vital or nonvital teeth), which were easy repairable; only three root fractures were reported.

Another clinical study evaluated the survival of 53 endodontically treated and morphologically compromised molars restored with monolithic CAD/CAM ceramic endocrowns, and reported a success rate of 94% after 4 years [76]. Failures were due to debonding (one tooth, restorable failure), restorable fracture (one tooth), secondary caries (one tooth, restorable failure), and one extraction due to persistent pain. Finally, another study investigating the survival of indirect composite onlays in posterior endodontically treated teeth (158 molars and 31 premolars) reported about 97% restoration survival over a period of 24–52 months [77], which is in the same range at the survival reported for all-ceramic and metal-ceramic crowns at 5 years (up to 96%) in a systematic review [78]. These data seem to indicate that overlay restorations are a reasonable option to restore endodontically treated molars.

Beyond the promising survival rates, this restoration strategy presents other advantages; importantly it does not require significant tissue removal for the placement of the restoration. It must be kept in mind that in molar endodontics, each restorative procedure significantly increased the amount of lost hard tissue volume [79]. Endocrowns are clearly a more conservative approach, which reduces the risk of procedural accidents such as root perforations or loss of the apical canal seal [58]. Moreover, post space preparation may increase the chances of root fracture [68]. Finally, deep cervical placement of restoration margins is not needed, which enables maximum conservation of enamel. This is crucial to obtain a predictable and efficient bond.

In conclusion, there is a lack of clear evidence regarding the need to use posts to restore endodontically treated molars. Even if there is not sufficient evidence to say that fiber posts should be avoided, evidence is accumulating to show that the loss of tooth structure is a factor favoring tooth fracture. Hence, if in view of the pros and cons presented above for the use of a fiber post, clinicians are still convinced that a post is necessary to restore endodontically treated molars, they should by all means

avoid any further tissue loss; removal of root canal filling material should be sufficient and NO additional space for the post should be created using drills. However, given their promising results and specific advantages of the endocrown option, it is our opinion that these adhesive procedures appear as a preferable choice.

7.10 Placement of Full Crowns After Molar Endodontics: Clinical Data and Study Biases

According to several studies, the presence of full or partial, direct or indirect restoration does not seem to affect the success of endodontic treatments [4, 8, 80]. However, there is a general assumption that survival of endodontically treated teeth is improved when systematically providing a full crown after the endodontic treatment. In a systematic literature review, it was reported that tooth survival for root canal-treated teeth restored with a crown or with a direct restoration decrease to about $81 \pm 12\%$ and $63 \pm 15\%$, respectively, at 10 years [81]. However, that study made no distinction regarding the amount of tissue loss or the type of tooth. Moreover, the authors actually considered mainly survival of the restoration, not of the tooth, since failure was considered as: fracture of the tooth, fracture of the restoration, post fracture, post decementation, dislodgment of the restoration, marginal leakage of the restoration, and tooth loss, and several of these failure events are restorable.

The assumption that a crown is systematically required after root canal treatment is supported either by prospective studies without randomization [1] or by retrospective studies. For example, in a large epidemiological study including almost 800,000 molars [82], it was reported that among the 3% of extracted teeth at 8 years, the number of teeth without crown (large amalgam or composite restoration, or no restoration at all) was more than sixfold higher compared to teeth with crowns. However, such comparison was not provided among the 97% of retained teeth. The lack of randomization between full indirect restorations and partial direct restorations in the available studies represents a major bias [8], since the amount of remaining tissue and/or the tooth prognosis play a major and subjective part in the decision making. This is clearly illustrated by a recent Cochrane review, concluding that “there is insufficient evidence to support or refute the effectiveness of conventional fillings over crowns for the restoration of root filled teeth. Until more evidence becomes available clinicians should continue to base decisions on how to restore root filled teeth on their own clinical experience, while taking into consideration the individual circumstances and preferences of their patients” [83]. Hence, personal guidelines or preferences followed by the practitioners for the restoration of endodontically treated teeth will affect the outcomes one way or the other. For example, on the one hand, a practice-based study reported that the survival of endodontically restored teeth restored with resin composite was superior to crowns [4]. Interestingly, the authors specify that endodontically treated teeth were restored routinely with a direct composite and that the placement of crowns was limited to severely damaged teeth, the latter being therefore more at risk of fracture.

On the other hand, other studies used the exact opposite reasoning; for example, teeth with poor prognosis may be considered not worth the investment of a crown [5].

This is supported by the observation that teeth presenting a periapical lesion before the restoration were significantly less likely to receive a crown (64%) than teeth without a lesion (76%) [8]. Therefore, teeth with a better long-term prognosis may be more likely to receive a crown, which introduces an important risk of bias in the conclusions drawn from observational studies and can lead to an overestimation of the effect of crown restoration on tooth longevity. Moreover, it has been suggested that patients who can afford crown placement might have a higher socioeconomic status and dental awareness, both potentially affecting tooth longevity [5]. In addition, cuspal coverage is provided in all cases for full crown restorations, whereas it is not a routine procedure when performing a more conservative direct restoration.

High-quality randomized controlled clinical trials are needed, which have to consider tooth type and remaining coronal tissue, to evaluate the importance of partial direct, indirect or full-crown restoration (Box 7.4).

Box 7.4. Tooth Reinforcement and Restoration Retention

- There is insufficient evidence to support the necessity to systematically establish a ferrule in ET molars.
- Fibers posts do not seem to reinforce endodontically treated molars. In vitro works, report that failure with or without posts occurs well above normal intraoral forces, or even parafunctional forces. In clinical studies, the data are insufficient to justify the use of posts to reinforce endodontically treated molars.
- Endodontically treated molars rarely, if ever, require a post for restoration retention since molars provide a large bonding area and are mostly submitted to vertical forces (whereas fiber posts help resist against lateral forces).
- If practitioners still want to place fiber posts, they should not remove additional tissue to prepare the post space and avoid any procedural errors, such as root perforation.
- Adhesive strategies such as “endocrown” or overlays are considered increasingly as a reliable option, based on the accumulating evidence of in vitro and clinical works. They represent an efficient and more conservative approach, although more clinical studies are needed to fully confirm this trend.

7.11 The Relevance of Cuspal Coverage

One current strategy suggested to make endodontically teeth less susceptible to fracture is to provide cuspal coverage. This is supported by some studies that suggest improved longevity of fully crowned teeth, but one has to consider the mentioned study biases. As concluded by Ng et al. [1], the systematic provision of full crown coverage is probably a large exaggeration of the true need, since it requires further removal of tooth tissue from an already weakened tooth. These authors recommend that the restoration preparation should try to preserve as much remaining

tooth tissue as possible, and partial cuspal coverage by overlays appears therefore as the restoration of choice for many endodontically treated molars.

Regarding in vitro data, the interest of covering the cusps these teeth has first been described by Linn and others [37], who reported that cusp coverage with gold or amalgam overlays protects teeth with MO and MOD cavities against fracture. A finite element analysis reported that the reduction of buccal and lingual cusps and their coverage by an overlay results in a fourfold reduction of stresses generated in the dentin as compared with an inlay restoration without cuspal reduction [84]. Another in vitro study compared fracture resistance of root canal-treated molars with MO cavities, restored with either direct or indirect composite restoration with cuspal coverage [85]. They reported no significant difference, once again with values well above physiological forces (around 1400 N). Interestingly, values in the same range were reported when using direct composite to restore cavities with two or more remaining walls, but without cuspal coverage (from 1200 to 1600 N) [61]. However, the resistance values dropped significantly for teeth with one or no remaining wall (700–800 N), though still above physiological values.

The importance of remaining tooth structure is also highlighted in a clinical study, investigating the success of direct restoration without cusp coverage ($n=220$ teeth, 195 composite, 14 amalgam, 11 IRM), as a function of three types of remaining tooth structures [86]:

- Type I: maximum remaining tooth structure, approximately Class I cavity, the remaining walls being more than 2 mm thick
- Type II: moderate remaining tooth structure, approximately a Class II cavity, two walls minimum being more than 2 mm thick.
- Type III: minimum remaining tooth structure, less than two walls being more than 2 mm thick.

The restoration success rates for Type I, II and III decreased from more than 94 % at 1 year to about 78 % (Type I), 45 % (Type II), and 18 % (Type III) at 5 years. This led to the conclusion that endodontically treated molars with little coronal tissue loss (Type I) can be successfully restored for a prolonged period with dental composite, and without cusp coverage. On the contrary, for teeth with larger tissue loss (Type II and III) the short-term success is quite high but it drops significantly with time. Importantly, in that study, success was defined as tooth needing a new restoration, a repair procedure, or an extraction (failures due to endodontic and periodontal reasons were excluded). Hence, restorable and non-restorable failures were not discriminated in the calculations. Finally, it is mentioned that over the observation period of up to 10 years, only 6 % of the teeth had to be extracted out of the 46 % total failures, which indicates that most failures were restorable.

Hence, the question whether or not all cusps should systematically be covered by the material remains unclear from the literature (see Box 7.5). Nevertheless, it seems reasonable to cover selectively any wall that appears too weak to withstand

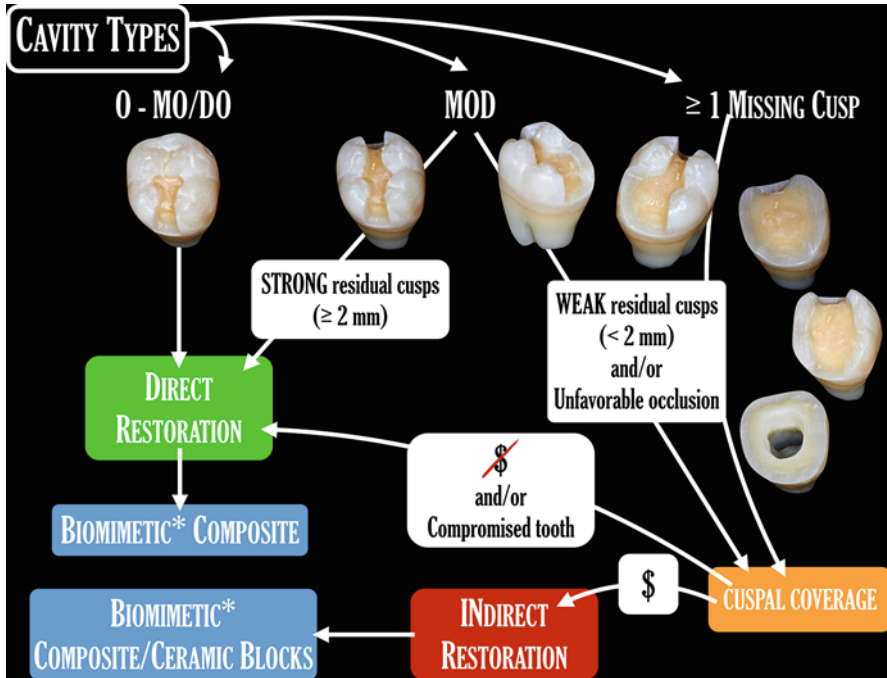


Fig. 7.8 Summary of the decision-making process for the restoration of endodontically treated molars

the high occlusal forces of the posterior area, especially in case of parafunctional forces (Fig. 7.8). It is also probably excessive to cover strong cusps (2 mm thickness or more being a reasonable estimate), given the paramount importance of coronal tissue preservation for fracture resistance. As to define what is a “strong” cusp, it is quite difficult to provide an absolute thickness threshold, but it is reasonable to state that 2 mm represent a strict minimum.

Box 7.5. Cuspal Coverage

- Full crown is not systematically required after root canal treatment of ET molars. Even if this is supported by most of the available literature, this is probably an overtreatment, given the numerous biases in the clinical studies. Many factors such as tooth type, extent and distribution of tissue loss, or else type and material of final restoration need to be considered to decide for the appropriate restorative strategy.
- Cuspal coverage of ET molars seems reasonable for any cavity wall that appears too weak to withstand the high occlusal forces of the posterior area, especially in case of parafunctional forces.

7.12 Direct or Indirect Restoration: Selection of Material and Clinical Procedures

Two major aspects to consider when considering a direct or an indirect restoration strategy are the restitution of tooth anatomy and the biomimetic properties of the material.

Regarding the first aspect, it is clear that the larger the restoration, the more difficult it is to recreate good proximal contact points, occlusal anatomy, and optimal contact with opposing teeth. Hence, it is common clinical sense that large restorations, that is, when one cusp or more are to be restored, will be more easily and more predictably prepared indirectly. This is also supported by clinical studies, reporting that the longevity of direct restorations decreases when the number of restored surfaces increases [87, 88].

Biomimetic properties of a restorative material (Fig. 7.8) relate to how well the material mimics the properties of the replaced dental tissue, mainly esthetically and mechanically; two material classes are applicable here: resin-based composites and ceramics. Between and within these two material classes, a wide range of biomechanical characteristics can be described. It is not the purpose of the present chapter to review every material available, but to provide the reader with general important principles.

According to the objectives presented above for the restoration of root canal-treated molars, the material chosen should both restore function and prevent any further damage to the tooth. In this regard, one important aspect is then to avoid the generation of stresses within the remaining tooth structure. Finite element analyses have shown that increasing the elastic modulus of the restoration material from 5 to 20 GPa leads to a significant reduction in stresses in the neighboring dental tissues [27], whereas a further increase above 20 GPa results in a stress increase [84].

Only highly filled composites reach the lower bounds of this range, and these materials also happen to possess the highest flexural strength and microhardness [23]. Accordingly, such high-performance composites should be favored for direct restorations, while materials with low mechanical properties such as the recent bulk-fill composites should be avoided [89]. Finally, given the major importance of irradiation protocols on the final composite properties [90], it is recommended that composites are placed in 2 mm increments, each one being light-cured during 20 s at a light irradiance of about 1000 mW/cm² [91].

For adhesive indirect restorations, recommended in case of large tissue loss, CAD/CAM blocks appear to be the best current available option. Among materials available in that category, there is currently no clinical evidence that ceramics perform better than composites for onlay restorations [92]. Hence, the choice must currently be made based on the available *in vitro* data.

Purely at the material level, lithium disilicate blocks were so far considered as the best combination of high flexural strength and resistance to fatigue degradation, while resin composite blocks outperformed glass-rich ceramics [93]. However, none

of the available materials perfectly mimics the properties of the replaced tissues. For example, the elastic modulus of lithium disilicate (around 70 GPa) [94] is indeed much higher than dentin, and in fact in the range of the values of enamel. As described for direct composites, the elastic modulus of composite blocks with dispersed fillers approaches the lower values reported for dentin [94, 95]. Another recently introduced composite block technology is based on a polymer-infiltrated ceramic network [94, 95]. The latter represents an interesting new avenue for indirect restorations, since it presents intermediate properties between dentin and enamel [95].

To sum up, in absence of a clear advantage of one material over the other, it appears that both lithium disilicate and high-performance composite represent appropriate options for the restoration of molars. Glass-rich ceramics and low-performance artisanal indirect composites should now clearly be avoided [93, 95].

Despite the clinical procedures and materials recommended above based on the amount of remaining dental tissues and material specificities (summarized in Fig. 7.8), the restorative dentist may have to opt for a direct composite restoration even in a case that an indirect restoration was indicated. The main reason is when the tooth is compromised, either due to the guarded prognosis of the endodontic treatment (Figs. 7.1i and 7.4a, b), or to other issues such as periodontal problems. In such cases, a direct restoration with high-performance composite materials is a valid temporary alternative, while endodontic success is evaluated. As mentioned before, large direct composite restoration in root canal-treated molars have good short-term prognosis (<2 years), even with little remaining coronal tissue [86]. Hence, such a restorative approach can be performed to temporize, and leave some time to evaluate healing. Then a more durable strategy can be performed, such as full crown, or overlay, except if the patient cannot afford the cost of an indirect restoration, in which case the direct composite may become a permanent option (Fig. 7.8).

Regarding the bonding strategy for the adhesive restorative strategies recommended above, one-step adhesives or cements should be considered with caution, since they seem to be related to significantly lower in vitro and clinical performances [96] (Box 7.6). Accordingly, it is recommended to use the most efficient adhesive technologies, that is, either the three-step Etch & Rinse (e.g., Optibond FL, Kerr, Orange, CA, USA) or the mild self-etch products (e.g., Clearfil SE Bond, Kuraray US, New York, NY, USA), the latter possessing the additional advantage of creating a chemical bond to hard tissues when containing molecules such as 10-MDP (10-methacryloxydecyl dihydrogen phosphate), and being potentially less technique-sensitive [97]. In case of indirect restorative procedure, the application of a separate bonding system prior to the resin composite cement is also required, since it leads to increased bond strength [98].

Specifically, for bonding to a dental substrate after an endodontic procedure, all adhesive substrates (enamel, coronal, and pulpal floor dentin) should be thoroughly cleaned, since any residue of endodontic sealer, sodium hypochlorite, or temporary filling agent is likely to interfere with bonding. For example, a negative effect of sodium hypochlorite on bonding was described for some bonding systems, an effect that could be reversed by use of antioxidants such as sodium ascorbate [50]. However, the negative effects of sealers and irrigants appear to be system-specific,

Box 7.6. Bonding Procedure Recommendations

- Prior to bonding, thoroughly clean the tooth substrate, for example, by air abrasion
- Use the best available adhesive technologies, that is, a three-step Etch & Rinse (e.g., Optibond FL, Kerr) or a mild self-etch product (e.g., Clearfil SE Bond, Kuraray)
- In case of indirect restoration, appropriately condition the overlay intrados: sandblasting for resin composites, sandblasting + etching with 5 % hydrofluoric acid for ceramics, followed by the application of a silane agent for both types of substrates
- In case of restoration repair (which leads to increased restoration longevity), clean the surfaces with air abrasion, and optimize surface conditioning to the nature of the existing restoration; silanization is a must in any case

and the restorative dentist is frequently not aware of all particular materials used by the endodontist. Hence, a nonspecific cleaning method prior to bonding, such as air abrasion, may be a more rational approach.

Following the cleaning of the dental surfaces and the application of the bonding system, the tooth will receive either a highly filled resin-based composite in case of a direct restoration, or a dual-cure resin composite cement followed by an onlay in case of an indirect restoration. The surface of the latter will need to be preliminary conditioned, that is, either sandblasted for resin composites, or sandblasted and/or etched with 5 % hydrofluoric acid for ceramics, followed by the application of a silane agent for both types of substrates.

7.13 Restoration Repair: A Rational Strategy

The points discussed above regarding an ideal restoration procedure concern all cases where the placement of a new restoration is considered. However, in many cases, the root canal system must be (re-) accessed, in presence of a satisfactory permanent restoration, for endodontic reasons (see Fig. 7.1i). In such cases, the practitioner must decide whether the existing restoration will be *repaired*, or *replaced* by a new restoration. Failing restorations or restorations presenting small defects are replaced by most clinicians [66], though this leads to an additional removal of sound tooth structure, and in general to a higher cost for the patient. Moreover, there is now cumulative evidence demonstrating that repair of restorations is not only a viable alternative to replacement, but one that leads to increased restoration longevity [66].

In fact, the mean survival period of existing crowns that had access cavity filled with a resin composite after root canal treatment was not different from new crowns, placed after root canal treatment [99] (Fig. 7.9). Such repair procedures must be conducted appropriately in order to restore the mechanical properties of the restoration as well as to provide optimal seal. Apart from the need to smoothen and clean

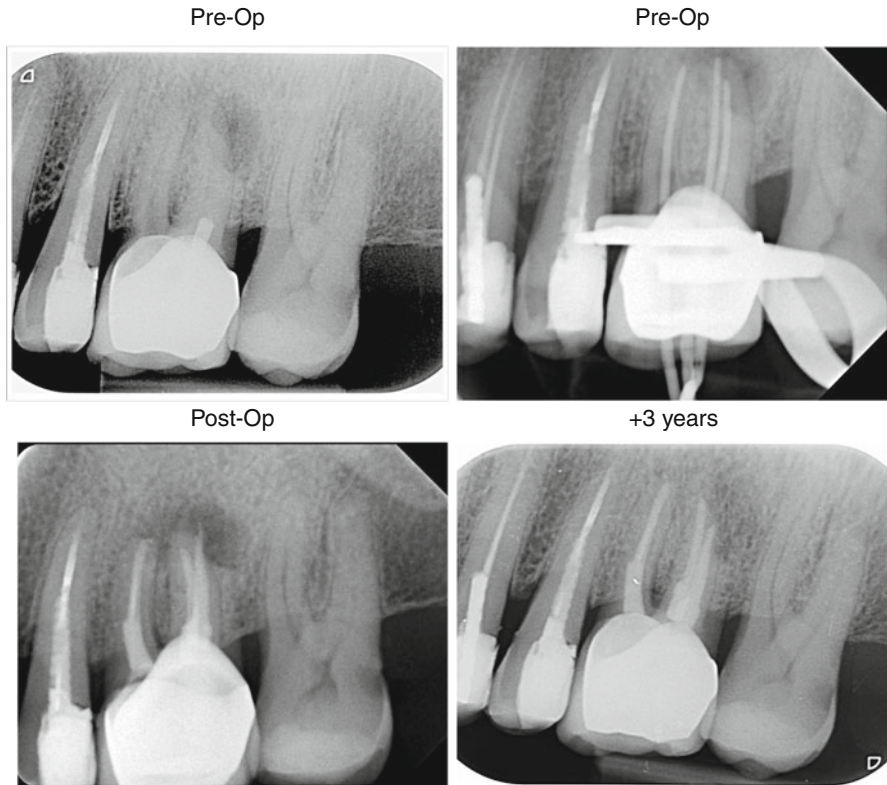


Fig. 7.9 Example of a tooth with clinically satisfactory coronal restoration (full crown), but unsatisfactory root canal treatment. The retreatment was performed through the crown after access opening, and removal of the metal post. The access opening was then repaired by placement of a resin composite restoration

the surfaces to repair (e.g., with a combination of bur and air abrasion), the nature and chemical specificities of the materials to be repaired must be carefully considered, and the products and strategies must be adapted to the substrate [35]. Composites need to be silanated prior to the application of a bonding system; ceramics need to be etched with 5% hydrofluoric acid (with caution), then silanated prior to the application of a bonding system; metal surfaces require the application of a silica coating, then be silanated before the application of a bonding and a resin composite [53].

7.14 Restoration of endodontically treated molars as part of multi-unit restorations

The majority of this chapter was devoted to the restoration of isolated teeth, which represents the majority of the cases. Now the question that needs to be asked is how to restore after an endodontic treatment a tooth which will be part of a plural

restoration (bridge, abutment, etc.). In fact, based on the available literature, the question that shall rather be asked is whether or not an endodontically treated molar be part of a plural restoration at all. The available data shows that the use of endodontically treated molar in plural restorations is subject to caution, reduced tooth survival being reported [4, 80]. This may be due to various causes, including higher occlusal stresses on the abutment teeth, different distribution of these stresses, with potentially an increased shear force component, or else the removal of a large amount of sound tissue to accommodate for the insertion axis. In light of these aspects, and given the good quality of modern implant strategies, it seems more reasonable to avoid the use of an ET molar as part of a plural restoration whenever possible. In spite of those considerations, if the use of a root-treated molar needs to be used as an abutment, the recommendations made above may need to be reconsidered. For example, a post insertion may in that case be more justified [3], as well as the creation of a ferrule.

In conclusion, for single-tooth restoration after molar root canal treatment, overall best practices suggest that clinicians consider the following during the restoration of root canal-treated molars:

- Overall adequate amount of structure retained
- Systematic need for ferrule and full crown contested
- Partial indirect restoration considered
- Cuspal coverage generally recommended
- Bacteria-tight coronal seal maintained
- Post placement avoided or critically evaluated
- Appropriate restoration material selected and correctly placed
- Biting pattern and functional forces considered
- Repair considered whenever possible

References

1. Ng YL, Mann V, Gulabivala K. A prospective study of the factors affecting outcomes of non-surgical root canal treatment: part 2: tooth survival. *Int Endod J.* 2011;44:610–25.
2. Al-Omiri MK, Mahmoud AA, Rayyan MR, Abu-Hammad O. Fracture resistance of teeth restored with post-retained restorations: an overview. *J Endod.* 2010;36:1439–49.
3. Peroz I, Blankenstein F, Lange KP, Naumann M. Restoring endodontically treated teeth with posts and cores – a review. *Quintessence Int.* 2005;36:737–46.
4. Skupien JA, Opdam N, Winnen R, Bronkhorst E, Kreulen C, Pereira-Cenci T, et al. A practice-based study on the survival of restored endodontically treated teeth. *J Endod.* 2013;39:1335–40.
5. Aquilino SA, Caplan DJ. Relationship between crown placement and the survival of endodontically treated teeth. *J Prosthet Dent.* 2002;87:256–63.
6. Naumann M, Koelpin M, Beuer F, Meyer-Lueckel H. 10-year survival evaluation for glass-fiber-supported postendodontic restoration: a prospective observational clinical study. *J Endod.* 2012;38:432–5.
7. Ng YL, Mann V, Gulabivala K. Tooth survival following non-surgical root canal treatment: a systematic review of the literature. *Int Endod J.* 2010;43:171–89.

8. Chugal NM, Clive JM, Spangberg LS. Endodontic treatment outcome: effect of the permanent restoration. *Oral Surg Oral Med Oral Pathol Oral Radiol Endod.* 2007;104:576–82.
9. Azarpazhooh A, Dao T, Ungar WJ, Da Costa J, Figueiredo R, Krahn M, et al. Patients' values related to treatment options for teeth with apical periodontitis. *J Endod.* 2016;42:365–70.
10. Dietschi D, Bouillaguet S, Sadan A. Restoration of the endodontically treated tooth. In: Hargreaves KM, Berman LH, editors. *Cohen's pathways of the pulp.* 10th ed. St. Louis: Mosby Elsevier; 2011. p. 777–807.
11. Hidaka O, Iwasaki M, Saito M, Morimoto T. Influence of clenching intensity on bite force balance, occlusal contact area, and average bite pressure. *J Dent Res.* 1999;78:1336–44.
12. Varga S, Spalj S, Lapter Varga M, Anic Milosevic S, Mestrovic S, Slaj M. Maximum voluntary molar bite force in subjects with normal occlusion. *Eur J Orthod.* 2011;33:427–33.
13. Kawata T, Yoda N, Kawaguchi T, Kuriyagawa T, Sasaki K. Behaviours of three-dimensional compressive and tensile forces exerted on a tooth during function. *J Oral Rehabil.* 2007;34:259–66.
14. Fontijn-Tekamp FA, Slagter AP, Van Der Bilt A, Van THMA, Witter DJ, Kalk W, et al. Biting and chewing in overdentures, full dentures, and natural dentitions. *J Dent Res.* 2000;79:1519–24.
15. Kishen A. Mechanisms and risk factors for fracture predilection in endodontically treated teeth. *Endod Topics.* 2006;13:57–83.
16. Cheron RA, Marshall SJ, Goodis HE, Peters OA. Nanomechanical properties of endodontically treated teeth. *J Endod.* 2011;37:1562–5.
17. Giannobile WV, Lang NP. Are dental implants a panacea or should we better thrive to save teeth? *J Dent Res.* 2016;95:5–6.
18. Van Meerbeek B, Peumans M, Poitevin A, Mine A, Van Ende A, Neves A, et al. Relationship between bond-strength tests and clinical outcomes. *Dent Mater.* 2010;26:e100–21.
19. van Noort R. The future of dental devices is digital. *Dent Mater.* 2012;28:3–12.
20. Dietschi D, Duc O, Krejci I, Sadan A. Biomechanical considerations for the restoration of endodontically treated teeth: a systematic review of the literature – part 1. Composition and micro- and macrostructure alterations. *Quintessence Int.* 2007;38:733–43.
21. Xu HH, Smith DT, Jahanmir S, Romberg E, Kelly JR, Thompson VP, et al. Indentation damage and mechanical properties of human enamel and dentin. *J Dent Res.* 1998;77:472–80.
22. Zicari F, Coutinho E, Scotti R, Van Meerbeek B, Naert I. Mechanical properties and micro-morphology of fiber posts. *Dent Mater.* 2013;29:e45–52.
23. Leprince J, Palin WM, Mullier T, Devaux J, Vreven J, Leloup G. Investigating filler morphology and mechanical properties of new low-shrinkage resin composite types. *J Oral Rehabil.* 2010;37:364–76.
24. Magni E, Ferrari M, Hickel R, Ilie N. Evaluation of the mechanical properties of dental adhesives and glass-ionomer cements. *Clin Oral Investig.* 2010;14:79–87.
25. Bryant RW, Mahler DB. Modulus of elasticity in bending of composites and amalgams. *J Prosthet Dent.* 1986;56:243–8.
26. White SN, Miklus VG, McLaren EA, Lang LA, Caputo AA. Flexural strength of a layered zirconia and porcelain dental all-ceramic system. *J Prosthet Dent.* 2005;94:125–31.
27. Asmussen E, Peutzfeldt A. Class I and class II restorations of resin composite: an FE analysis of the influence of modulus of elasticity on stresses generated by occlusal loading. *Dent Mater.* 2008;24:600–5.
28. Zadik Y, Sandler V, Bechor R, Salehrabi R. Analysis of factors related to extraction of endodontically treated teeth. *Oral Surg Oral Med Oral Pathol Oral Radiol Endod.* 2008;106:e31–5.
29. Ray HA, Trope M. Periapical status of endodontically treated teeth in relation to the technical quality of the root filling and the coronal restoration. *Int Endod J.* 1995;28:12–8.
30. Gillen BM, Looney SW, Gu LS, Loushine BA, Weller RN, Loushine RJ, et al. Impact of the quality of coronal restoration versus the quality of root canal fillings on success of root canal treatment: a systematic review and meta-analysis. *J Endod.* 2011;37:895–902.
31. Rechenberg DK, Schriber M, Attin T. Bacterial leakage through temporary fillings in core buildup composite material – an in vitro study. *J Adhes Dent.* 2012;14:371–6.
32. Magne P, Kim TH, Cascione D, Donovan TE. Immediate dentin sealing improves bond strength of indirect restorations. *J Prosthet Dent.* 2005;94:511–9.

33. Dall'Oca S, Papacchini F, Goracci C, Cury AH, Suh BI, Tay FR, et al. Effect of oxygen inhibition on composite repair strength over time. *J Biomed Mater Res B Appl Biomater.* 2007;81:493–8.
34. Leprince J, Lamblin G, Truffier-Boutry D, Demoustier-Champagne S, Devaux J, Mestdagh M, et al. Kinetic study of free radicals trapped in dental resins stored in different environments. *Acta Biomater.* 2009;5:2518–24.
35. Hickel R, Brushaver K, Ilie N. Repair of restorations – criteria for decision making and clinical recommendations. *Dent Mater.* 2013;29:28–50.
36. Reeh ES, Messer HH, Douglas WH. Reduction in tooth stiffness as a result of endodontic and restorative procedures. *J Endod.* 1989;15:512–6.
37. Linn J, Messer HH. Effect of restorative procedures on the strength of endodontically treated molars. *J Endod.* 1994;20:479–85.
38. Stankiewicz NR, Wilson PR. The ferrule effect: a literature review. *Int Endod J.* 2002;35:575–81.
39. Juloski J, Radovic I, Goracci C, Vulicevic ZR, Ferrari M. Ferrule effect: a literature review. *J Endod.* 2012;38:11–9.
40. Setzer FC, Boyer KR, Jeppson JR, Karabucak B, Kim S. Long-term prognosis of endodontically treated teeth: a retrospective analysis of preoperative factors in molars. *J Endod.* 2011;37:21–5.
41. Mancebo JC, Jimenez-Castellanos E, Canadas D. Effect of tooth type and ferrule on the survival of pulpless teeth restored with fiber posts: a 3-year clinical study. *Am J Dent.* 2010;23:351–6.
42. Creugers NH, Mentink AG, Fokkinga WA, Kreulen CM. 5-year follow-up of a prospective clinical study on various types of core restorations. *Int J Prosthodont.* 2005;18:34–9.
43. Santana FR, Castro CG, Simamoto-Junior PC, Soares PV, Quagliatto PS, Estrela C, et al. Influence of post system and remaining coronal tooth tissue on biomechanical behaviour of root filled molar teeth. *Int Endod J.* 2011;44:386–94.
44. Murphy F, McDonald A, Petrie A, Palmer G, Setchell D. Coronal tooth structure in root-treated teeth prepared for complete and partial coverage restorations. *J Oral Rehabil.* 2009;36:451–61.
45. Castro CG, Santana FR, Roscoe MG, Simamoto Jr PC, Santos-Filho PC, Soares CJ. Fracture resistance and mode of failure of various types of root filled teeth. *Int Endod J.* 2012;45:840–7.
46. Plotino G, Grande NM, Bedini R, Pameijer CH, Somma F. Flexural properties of endodontic posts and human root dentin. *Dent Mater.* 2007;23:1129–35.
47. Tang W, Wu Y, Smales RJ. Identifying and reducing risks for potential fractures in endodontically treated teeth. *J Endod.* 2010;36:609–17.
48. Serafino C, Gallina G, Cumbo E, Ferrari M. Surface debris of canal walls after post space preparation in endodontically treated teeth: a scanning electron microscopic study. *Oral Surg Oral Med Oral Pathol Oral Radiol Endod.* 2004;97:381–7.
49. Ari H, Yasar E, Belli S. Effects of NaOCl on bond strengths of resin cements to root canal dentin. *J Endod.* 2003;29:248–51.
50. Lai SC, Mak YF, Cheung GS, Osorio R, Toledano M, Carvalho RM, et al. Reversal of compromised bonding to oxidized etched dentin. *J Dent Res.* 2001;80:1919–24.
51. Vongphan N, Senawongse P, Somsiri W, Harnirattisai C. Effects of sodium ascorbate on microtensile bond strength of total-etching adhesive system to NaOCl treated dentine. *J Dent.* 2005;33:689–95.
52. Schwartz RS. Adhesive dentistry and endodontics. Part 2: bonding in the root canal system-the promise and the problems: a review. *J Endod.* 2006;32:1125–34.
53. Schwartz RS, Fransman R. Adhesive dentistry and endodontics: materials, clinical strategies and procedures for restoration of access cavities: a review. *J Endod.* 2005;31:151–65.
54. Carvalho RM, Pereira JC, Yoshiyama M, Pashley DH. A review of polymerization contraction: the influence of stress development versus stress relief. *Oper Dent.* 1996;21:17–24.
55. Yoshikawa T, Sano H, Burrow MF, Tagami J, Pashley DH. Effects of dentin depth and cavity configuration on bond strength. *J Dent Res.* 1999;78:898–905.

56. Aksornmuang J, Nakajima M, Senawongse P, Tagami J. Effects of C-factor and resin volume on the bonding to root canal with and without fibre post insertion. *J Dent.* 2011;39:422–9.
57. Bouillaguet S, Troesch S, Wataha JC, Krejci I, Meyer JM, Pashley DH. Microtensile bond strength between adhesive cements and root canal dentin. *Dent Mater.* 2003;19:199–205.
58. Schwartz RS, Robbins JW. Post placement and restoration of endodontically treated teeth: a literature review. *J Endod.* 2004;30:289–301.
59. Scotti N, Coero Borga FA, Alovisi M, Rota R, Pasqualini D, Berutti E. Is fracture resistance of endodontically treated mandibular molars restored with indirect onlay composite restorations influenced by fibre post insertion? *J Dent.* 2012;40:814–20.
60. Salameh Z, Ounsi HF, Aboushelib MN, Al-Hamdan R, Sadig W, Ferrari M. Effect of different onlay systems on fracture resistance and failure pattern of endodontically treated mandibular molars restored with and without glass fiber posts. *Am J Dent.* 2010;23:81–6.
61. Salameh Z, Sorrentino R, Papacchini F, Ounsi HF, Tashkandi E, Goracci C, et al. Fracture resistance and failure patterns of endodontically treated mandibular molars restored using resin composite with or without translucent glass fiber posts. *J Endod.* 2006;32:752–5.
62. Salameh Z, Ounsi HF, Aboushelib MN, Sadig W, Ferrari M. Fracture resistance and failure patterns of endodontically treated mandibular molars with and without glass fiber post in combination with a zirconia-ceramic crown. *J Dent.* 2008;36:513–9.
63. Fokkinga WA, Kreulen CM, Bronkhorst EM, Creugers NH. Composite resin core-crown reconstructions: an up to 17-year follow-up of a controlled clinical trial. *Int J Prosthodont.* 2008;21:109–15.
64. Ferrari M, Cagidiaco MC, Goracci C, Vichi A, Mason PN, Radovic I, et al. Long-term retrospective study of the clinical performance of fiber posts. *Am J Dent.* 2007;20:287–91.
65. Bitter K, Noetzel J, Stamm O, Vautd J, Meyer-Lueckel H, Neumann K, et al. Randomized clinical trial comparing the effects of post placement on failure rate of postendodontic restorations: preliminary results of a mean period of 32 months. *J Endod.* 2009;35:1477–82.
66. Demarco FF, Correa MB, Cenci MS, Moraes RR, Opdam NJ. Longevity of posterior composite restorations: not only a matter of materials. *Dent Mater.* 2012;28:87–101.
67. Rüttermann S, Alberts I, Raab WH, Janda RR. Physical properties of self-, dual-, and light-cured direct core materials. *Clin Oral Investig.* 2011;15:597–603.
68. Bitter K, Kielbassa AM. Post-endodontic restorations with adhesively luted fiber-reinforced composite post systems: a review. *Am J Dent.* 2007;20:353–60.
69. Dejak B, Mlotkowski A. 3D-finite element analysis of molars restored with endocrowns and posts during masticatory simulation. *Dent Mater.* 2013;29:e309–17.
70. Peumans M, Hikita K, De Munck J, Van Landuyt K, Poitevin A, Lambrechts P, et al. Bond durability of composite luting agents to ceramic when exposed to long-term thermocycling. *Oper Dent.* 2007;32:372–9.
71. Biacchi GR, Basting RT. Comparison of fracture strength of endocrowns and glass fiber post-retained conventional crowns. *Oper Dent.* 2012;37:130–6.
72. Bindl A, Richter B, Mörmann WH. Survival of ceramic computer-aided design/manufacturing crowns bonded to preparations with reduced macroretention geometry. *Int J Prosthodont.* 2005;18:219–24.
73. Zhang Y, Lee JJ, Srikanth R, Lawn BR. Edge chipping and flexural resistance of monolithic ceramics. *Dent Mater.* 2013;29:1201–8.
74. van Dijken JW, Hasselrot L, Ormin A, Olofsson AL. Restorations with extensive dentin/enamel-bonded ceramic coverage. A 5-year follow-up. *Eur J Oral Sci.* 2001;109:222–9.
75. van Dijken JW, Hasselrot L. A prospective 15-year evaluation of extensive dentin-enamel-bonded pressed ceramic coverages. *Dent Mater.* 2010;26:929–39.
76. Ozyoney G, Yan Koglu F, Tagtekin D, Hayran O. The efficacy of glass-ceramic onlays in the restoration of morphologically compromised and endodontically treated molars. *Int J Prosthodont.* 2013;26:230–4.
77. Chrepa V, Konstantinidis I, Kotsakis GA, Mitsias ME. The survival of indirect composite resin onlays for the restoration of root filled teeth: a retrospective medium-term study. *Int Endod J.* 2014;47:967–73.

78. Pjetursson BE, Sailer I, Zwahlen M, Hämmerle CHF. A systematic review of the survival and complication rates of all-ceramic and metal–ceramic reconstructions after an observation period of at least 3 years. Part I: single crowns. *Clin Oral Implants Res.* 2007;18:73–85.
79. Ikram OH, Patel S, Sauro S, Mannocci F. Micro-computed tomography of tooth tissue volume changes following endodontic procedures and post space preparation. *Int Endod J.* 2009;42:1071–6.
80. Ng YL, Mann V, Gulabivala K. A prospective study of the factors affecting outcomes of non-surgical root canal treatment: part I: periapical health. *Int Endod J.* 2011;44:583–609.
81. Stavropoulou AF, Koidis PT. A systematic review of single crowns on endodontically treated teeth. *J Dent.* 2007;35:761–7.
82. Salehrabi R, Rotstein I. Endodontic treatment outcomes in a large patient population in the USA: an epidemiological study. *J Endod.* 2004;30:846–50.
83. Fedorowicz Z, Carter B, de Souza RF, Chaves CA, Nasser M, Sequeira-Byron P. Single crowns versus conventional fillings for the restoration of root filled teeth. *Cochrane Database Syst Rev.* 2012;5:CD009109.
84. Jiang W, Bo H, YongChun G, LongXing N. Stress distribution in molars restored with inlays or onlays with or without endodontic treatment: a three-dimensional finite element analysis. *J Prosthet Dent.* 2010;103:6–12.
85. Plotino G, Buono L, Grande NM, Lamorgese V, Somma F. Fracture resistance of endodontically treated molars restored with extensive composite resin restorations. *J Prosthet Dent.* 2008;99:225–32.
86. Nagasiri R, Chitmongkolsuk S. Long-term survival of endodontically treated molars without crown coverage: a retrospective cohort study. *J Prosthet Dent.* 2005;93:164–70.
87. Opdam NJ, Bronkhorst EM, Roeters JM, Loomans BA. A retrospective clinical study on longevity of posterior composite and amalgam restorations. *Dent Mater.* 2007;23:2–8.
88. Pallesen U, van Dijken JW, Halken J, Hallonsten AL, Hoigaard R. Longevity of posterior resin composite restorations in permanent teeth in Public Dental Health Service: a prospective 8 years follow up. *J Dent.* 2013;41:297–306.
89. Leprince JG, Palin WM, Vanacker J, Sabbagh J, Devaux J, Leloup G. Physico-mechanical characteristics of commercially available bulk-fill composites. *J Dent.* 2014;42:993–1000.
90. Leprince JG, Palin WM, Hadis MA, Devaux J, Leloup G. Progress in dimethacrylate-based dental composite technology and curing efficiency. *Dent Mater.* 2013;29:139–56.
91. Leprince J, Devaux J, Mullier T, Vreven J, Leloup G. Pulpal-temperature rise and polymerization efficiency of LED curing lights. *Oper Dent.* 2010;35:220–30.
92. Fron Chabouis H, Smail Faugeron V, Attal JP. Clinical efficacy of composite versus ceramic inlays and onlays: a systematic review. *Dent Mater.* 2013;29:1209–18.
93. Belli R, Geinzer E, Muschweck A, Petschelt A, Lohbauer U. Mechanical fatigue degradation of ceramics versus resin composites for dental restorations. *Dent Mater.* 2014;30:424–32.
94. Ruse ND, Sadoun MJ. Resin-composite blocks for dental CAD/CAM applications. *J Dent Res.* 2014;93:1232–4.
95. Mainjot AK, Dupont NM, Oudkerk JC, Dewael TY, Sadoun MJ. From artisanal to CAD-CAM blocks: state of the art of indirect composites. *J Dent Res.* 2016;95(5):487–95.
96. Poitevin A, De Munck J, Van Ende A, Suyama Y, Mine A, Peumans M, et al. Bonding effectiveness of self-adhesive composites to dentin and enamel. *Dent Mater.* 2013;29:221–30.
97. Van Meerbeek B, De Munck J, Yoshida Y, Inoue S, Vargas M, Vijay P, et al. Buonocore memorial lecture. Adhesion to enamel and dentin: current status and future challenges. *Oper Dent.* 2003;28:215–35.
98. Ariyoshi M, Nikaido T, Foxton RM, Tagami J. Microtensile bond strengths of composite cores to pulpal floor dentin with resin coating. *Dent Mater J.* 2008;27:400–7.
99. Dammachke T, Nykiel K, Sagheri D, Schafer E. Influence of coronal restorations on the fracture resistance of root canal-treated premolar and molar teeth: a retrospective study. *Aust Endod J.* 2013;39:48–56.

The Outcome of Endodontic Treatment

8

Thomas Kvist

Abstract

In any medical treatment modality, outcome assessment is a major step. For root canal treatment, this primarily means looking at clinical symptoms and assessing radiographs. Moreover, retention is also an important outcome parameter and in this regard questions remain in regard to the association of endodontically treated teeth and overall health of the patient. Therefore, this chapter is dedicated to outcome assessments and decision-making for endodontically treated teeth.

Guiding Reference

Swedish Council on Health Technology Assessment. Methods of Diagnosis and Treatment in Endodontics—A Systematic Review. 2010: Report nr 203;1–491. <http://www.sbu.se>

This comprehensive summary evaluated methods used by dentists to diagnose, prevent and treat inflammation and infection of the dental pulp. Root canal therapy (endodontics) is conducted to ensure healthy conditions in and around teeth, which have been damaged by caries, external trauma or other causes. Despite the overall high standard of dental health in Sweden, root fillings are still common and are expensive items of treatment for both the individual and the society.

T. Kvist, PhD, DDS

Department of Endodontology, Institute of Odontology, The Sahlgrenska Academy, University of Gothenburg, Box 450, Gothenburg SE 405 30, Sweden
e-mail: kvist@odontologi.gu.se

8.1 Introduction

Pathosis of endodontic origin develops as a response to microbiological challenges and is mainly a sequel to dental caries. Trauma may be a frequent reason for endodontic treatment in incisors and premolars. But since this book is about molar endodontics, particular aspects on trauma will not be covered in this chapter. In many situations, both pulpitis and apical periodontitis evolve despite the lack of any clinical symptoms and are detected during routine dental visits. However, root canal treatment is mainly initiated because of pain from affected teeth. When people become sick and are suggested a treatment, they have many questions about how their illness and the treatment will affect them. This also holds true for diseases emanating from the dental pulp and periradicular tissues. Some frequently asked questions are likely to be as follows:

- What will happen to my tooth and my body if pulpitis or apical periodontitis is left untreated?
- What different treatment options do I have if I decide to keep my tooth?
- After treatment, will my symptoms disappear?
- How do disease and treatment affect my risk of losing the tooth?
- Will treatment cure pulpitis or apical periodontitis?
- Is there a risk of persistence or relapse of disease?
- What are my options, if persistence or relapse does occur?
- Would it be a better idea to take the tooth out?
- If so, can it be replaced?

8.2 Prognosis

8.2.1 The Scientific Basis for Statements Concerning Prognosis

Prognosis is a prediction of the future course of disease following its onset with or without treatment. Studies on prognosis tackle the clinical questions noted above. A group of patients with a condition such as pulpitis or that have a particular treatment in common, such as root canal treatment, is identified and followed forward in time. Clinical outcomes are measured. Often, conditions that are associated with a given outcome of the disease, that is, prognostic factors, are sought. This is a difficult but indispensable task and may be affected by biases that have to be controlled in these studies. The objective is to predict the future of individual patients and their affected teeth as closely as possible. The intention in the clinical setting is to avoid stating needlessly vague prognoses and answer with confidence when it is deceptive. Therefore, relevant studies aiming to answer the clinical questions must be scrutinized for quality.

The examination comprises evaluation of relevance with regard to subject matter and methodological qualities – study design, internal validity (reasonable protection from systematic errors), statistical power, and generalizability.

Experimental studies in laboratory animals and in vitro studies are generally considered to give only uncertain and preliminary answers to clinical questions. In order to give trustworthy answers to specific clinical questions, only randomized controlled studies, controlled clinical studies, and prospective cohort studies are considered to give the basis for scientific evidence on clinical questions.

8.2.2 Statements About Prognosis in Endodontics

Unfortunately, in recent years, several careful analyses of the scientific basis for the methods that we apply in endodontics have demonstrated extensive shortcomings [1–15]. The situation is worrying for diagnostic and treatment procedures as well as for evaluation of the results of our methods.

It is generally acknowledged by the profession, their patients, and society that practitioners have gathered lengthy clinical experience and that results from in vitro, animal, and clinical studies provide a basis for understanding how the pulp and the periapical tissues respond to therapeutic interventions.

Certainly, many clinical investigations have confirmed that an inflamed pulp may be successfully treated with a conservative procedure, that is, one that is retaining the vital pulp. Yet, to date, there is no analysis available on which clinical conditions define cases that are likely to respond well, and which treatment measures will render teeth functional and asymptomatic.

Many follow-up studies have also demonstrated that teeth with necrotic and infected pulps can be treated endodontically to achieve a healthy outcome that can last many years. This bulk of knowledge has repeatedly been presented in scientific journal reviews and textbooks of endodontics. There are, however, few clinical studies of high scientific quality. Consequently, there is a lack of scientific evidence to show which treatment protocols are the most effective and result in root-filled teeth with minimal risk of recurrent symptoms, periapical inflammation, or loss of the tooth.

Randomized, controlled, and blinded trials are the standard of excellence for comparison of treatment effects and are useful to observe a given treatment method or procedure when all other variables are maintained. At the same time, it is important to bear in mind that there are important parameters, which can influence treatment results, but which cannot be easily controlled in clinical studies. Results of clinical studies must be judged in relation to two broad questions:

- Can the diagnostic method or treatment work under ideal circumstances?
- Does it work in ordinary settings?

The label's efficacy and effectiveness have been applied to these concepts. To a certain degree, this may be a question of the clinician's experience, ability, attention to detail, meticulousness, and skill. It is seldom possible to assess to what extent such factors influence the results of treatment studies or clinical evaluations. It is however reasonable to assume that in a discipline such as endodontics, these factors are most important because of the technically complicated nature of many endodontic

procedures. In particular, in molar endodontics, the diagnosis and treatment are often complex, and the influence on the results of the operator cannot be overvalued. So far, most clinical studies in endodontics have been conducted in academic or specialist settings (*efficacy*) where devices that substantially facilitate the technical procedures and affect treatment outcomes are widely spread. For the future, it is important that clinical research in endodontics is also conducted in general practice settings, where the majority of endodontic procedures are performed (*effectiveness*). In this chapter, we try to give an overview of the prognosis for endodontic treatments based on the current and best available evidence and clinical experience, as it has been presented in textbooks, at conferences, and other professional venues. Furthermore, we point out some of the obvious knowledge gaps and controversies in the science of clinical endodontics.

8.3 Natural History of Disease

The prognosis of a disease without interference is termed the natural history of disease. A great many teeth with pulpitis and apical periodontitis, even in countries with well-developed dental care, often do not come under dental treatment. They remain unrecognized, because they are asymptomatic or are considered among the ordinary discomforts of daily living. Or, the patient may be suffering both pain and other symptoms for a prolonged period of time, but because of economic limitations has not been able to seek dental care.

Numerous teeth with only small caries lesions in the dentin, sometimes even when lesions are confined to the enamel only, develop inflammatory changes in the pulp.

As long as the caries is still in the periphery, the pulp is regularly able to endure the challenge caused by bacteria in the dentine. The quicker the progression and the deeper the lesion gets, the more severe the inflammatory response in the pulp. When the caries lesion continues to progress, pulp vitality is jeopardized. Once the bacterial front extends into reparative dentin or the pulp tissue proper, it may finally reach a point of no return. Pulp necrosis will sooner or later follow. It is known that the disease can be severe without causing patients symptoms, even if the pulpitis eventually leads to pulp necrosis. Also, dental procedures and different forms of accidental trauma may cause injury, leading to pulp necrosis. In molars with two or more roots, it is a common feature that in one root total pulp necrosis has already occurred, while in another root, the pulp is still vital but severely inflamed.

Collapse of the dental pulp by any cause results in loss of the defense mechanisms that can counteract microorganisms in the oral cavity from entering into the root canal system. In cases of direct exposure such as caries or fracture, microorganisms rapidly invade the available pulpal space. In apparently intact teeth, microorganisms will ultimately find ways to access the root canal through fractures, cracks, or from accessory lateral and furcal canals in teeth with periodontal breakdown. In restored teeth, the pathway may be via dentinal tubules under restorations with marginal gaps. The invasion of microorganisms is a prerequisite for the development of apical periodontitis.

As the microbiota of the mouth invades the necrotic pulpal tissue, an inflammatory reaction, that is, apical periodontitis, will develop outside the root canal system

adjacent to the foramina. One of the main features of apical periodontitis is the appearance of an osteolytic area due to the increased activity of osteoclasts. In early stages, the loss of mineral is not enough to be detected in traditional intraoral radiographs. However, eventually, a visible periapical radiolucency will develop. Inflammatory periapical lesions associated with an infected necrosis of the root canal system may prevail without clinical or subjective signs (pain, tenderness, sinus tracts, or swelling). However, symptomatic apical periodontitis may develop spontaneously. Severe pain might develop with or without soft-tissue swelling. Spread of an infection may occasionally lead to life-threatening conditions. Abscesses can spread to the sublingual space and lead to elevation of the tongue followed by occlusion of the airways or toward the eye and ophthalmic vein, which in turn is in contact with the brain through the cavernous sinus.

The natural history of teeth with a necrotic pulp and apical periodontitis on a population basis are to a great extent unknown. Some sparse information may be extradited from the few longitudinal observational studies on teeth and endodontic status. For example, Kirkevang et al. 2012 [16] presented data from a Danish cohort of 327 individuals who participated in three consecutive full-mouth radiographic examinations with 5-year intervals. It was possible to follow-up 33 teeth with apical periodontitis over a period of 10 years. At the last follow-up examination, five untreated teeth were diagnosed without signs of apical periodontitis (15%) and five untreated teeth remained with signs of apical periodontitis (15%). Nine teeth had root fillings (27%) and fourteen teeth were lost (42%). As a contrast, only 98 of 8225 teeth (1%) without apical periodontitis at baseline were lost during the same period. Ideally, prospective longitudinal studies on natural history of necrotic teeth should include both clinical and radiographic observations. However, there are ethical and practical considerations making such studies, if not impossible, at least very difficult to implement.

8.4 Clinical Course

The term clinical course has been used to describe the evolution (prognosis) of disease that has come under medical or dental care and treated in a variety of ways that might affect the subsequent course of events. Treatment of pulpal and periradicular pathology is inserted at different stages of disease development. As long as the pulp remains vital, there is a possibility of reversing the progression of disease and preserve the pulp. The advantage of preserving the pulp tissue is most obvious in the case of a young permanent tooth with a large pulp chamber and undeveloped root, because removing the pulp arrests root development. The dentinal walls in the root will then be thin, increasing the risk of root fracture. A root-filled tooth in an adult also carries with it the risk for fracture. The prognosis in terms of the survival rate of root-filled teeth is not as good as vital teeth, especially in molars. Possible reasons include the loss of proprioceptive function, damping property, and tooth sensitivity, once a vital pulp succumbs to necrosis or is removed by pulpectomy. From a cost aspect as well, the alternative of retaining all or some of the pulp is preferable. The clinicians' challenge is to distinguish conditions where pulp can be preserved and cured (reversible pulpitis) from those in which the pulp is so extensively damaged that the road to

complete necrosis is inevitable (irreversible pulpitis). Unfortunately, there is no scientific basis on which to assess the value of pain or other markers of inflammation intended to differentiate between reversible and irreversible pulpitis [13].

8.5 Vital Pulp Therapies

8.5.1 Caries in Primary Dentin

The most basic and simple treatment of reversible pulpitis consists of stopping the progression of caries. Beyond a certain point, excavation of a caries lesion is considered necessary, and a filling is placed to restore the dentin. The prognosis of the pulp after caries removal and placement of a filling is probably very good. However, large cohort studies focusing on pulpal pathology after restorative procedures are surprisingly rare. In a randomized trial investigating the dentine and pulp protection by conditioning-and-sealing versus a conventional calcium hydroxide lining, Whitworth et al. 2005 [17] studied a cohort of 602 teeth, which were restored with composite fillings. Over a period of 3 years, 16 teeth (2,6%) developed clinical signs of pulpal breakdown. The residual dentine thickness is generally believed to be a key prognostic factor in these situations. Deep lesions are considered being more at risk for pulpal collapse than shallow ones.

8.5.2 Deep Caries

If the carious lesion with its bacterial front enters the primary dentin and progresses into the reparative dentin zone or even into the pulp tissue proper, the inflammatory response in the pulp becomes massive. In the above-mentioned study by Whitworth et al. [17], pulp exposures appeared strongly associated with an unfavorable pulp outcome. These observations have led authors to propose that treatment methods where pulp exposure is avoided should be preferred over those in which the pulp is at risk of being exposed [14].

There are basically two methods available to avoid exposure of the pulp: Indirect pulp capping and stepwise excavation. With both methods, a layer of carious dentine is left undisturbed. The difference between the two methods is that in the former the tooth is left without further intervention, whereas the latter includes a re-entry for checkup and possible further excavation at a later (3–6 months) session. In a review published in 2013, eight clinical trials with 934 participants and 1372 teeth were scrutinized [14]. Four studies investigated only primary teeth, three permanent teeth, and one included both. Both stepwise and partial excavation without re-entry reduced the incidence of pulp exposure in symptomless, vital, and carious primary as well as permanent teeth. Therefore, these techniques seem to have clinical advantage over complete caries removal in the treatment of deep dentinal caries. Unfortunately, these studies have debilitating characteristics and do not provide the scientific basis to evaluate differences in pulpal survival rates following immediate complete caries excavation or stepwise excavation in the long term.

8.5.3 Pulp Exposure

If the pulp is exposed, four more or less different treatment options are available.

The pulpal wound can be covered with a dressing (direct pulp capping). Another approach is to remove the outermost layer of pulpal tissue and apply a dressing to the wound (partial pulpotomy). Yet another option is to remove the contents of the pulp chamber and locate the surface of the wound at the opening of the root canal (pulpotomy). The most radical method is to remove all of the pulp tissue from the pulp chamber and the root canals (pulpectomy) and replace it with a root filling.

Caries is the most common cause of pulp exposure. The outcome of the three above-mentioned treatment options available in order to retain the vitality of all or part of the pulp (direct pulp capping, partial pulpotomy, and full pulpotomy) in permanent teeth with cariously exposed pulps has been reviewed by Aguilar and Linsuwanont [10]. Over a period of 3 years, a clinically favorable outcome (tooth in an asymptomatic state without signs of pulpal necrosis and subsequent infection) was in the range of 73–99% with no conclusive advantage neither for any of the three types of treatment, nor for clear answers as to what factors might influence treatment outcome. It is a common opinion among clinicians that various symptoms and clinical findings may indicate that the pulp is irreversibly inflamed. The significance of persistent toothache, radiographic changes in the periapical region, abnormal pain reactions to thermal stimuli, and/or abnormal bleeding from an exposed pulp as signs for the prognosis of a treatment aimed to preserve the pulp has not been studied sufficiently well. In another review of the matter, it was concluded that there is limited scientific support that preoperative toothache increases the risk of failure of direct pulp capping [9]. This Swedish comprehensive review applied stricter inclusion criteria for studies. Their main conclusion on the topic was also that there is no scientific basis for assessment of which method, direct pulp capping, partial pulpotomy, or pulpotomy gives the most favorable conditions for maintaining the pulp in a vital and asymptomatic condition (Box 8.1).

Box 8.1. Follow-Up After Treatments Aiming at Preserving a Molar's Pulp Vitality

Evaluation	Signs of favorable outcome	Checklist
Subjective symptoms	Asymptomatic, comfortable, and functional	✓
Restoration	Good-quality restoration with no signs of caries	✓
Pulp sensitivity	Normal positive response to thermal or electric pulp testing	✓
Periradicular tissues Clinical	No signs of swelling, redness, or sinus tract	✓
Periradicular tissues Radiographic	No signs of periradicular bone destruction	✓

Pulpectomy

Complete removal of the pulp and placement of a root filling is the most extreme treatment approach when a pulp has been exposed. The scientific literature on pulpectomy is limited, and in particular there are no studies of direct comparison between the results of pulp preservation therapies with pulpectomies. Furthermore, many follow-up studies have not been able to make a clear distinction between teeth with vital but inflamed pulps and necrotic ones. In a randomized controlled study [18], the outcome of pulpectomy in one or two treatment sessions was assessed by a single dentist specialized in endodontics who carried out the treatments. A majority of the teeth in the study were affected by caries and had symptoms because of pulpitis. In both treatment groups, teeth were asymptomatic and without clinical and radiological signs of periapical infection or inflammation in 93 % of the cases, with a follow-up time up to 3 years.

In another clinical study [19], where supervised dental students carried out the pulpectomies and root fillings, it was found that after an observation period of 3.5–4 years, teeth with positive bacterial samples at the time of root filling had a poorer outcome than that of teeth with negative samples. Also, significantly more unfavorable outcomes were noted after 3.5–4 years than after 1 year of observation. The findings are in concordance with the results of a review on the outcome of primary root canal treatments (including pulpectomies) in which four conditions were found to improve the outcome of primary root canal treatment significantly [4]. One of these factors, the absence of periapical radiolucency, indicates that a noninfected root canal is a prognostic factor favoring an outcome where no signs of apical periodontitis will develop. Consequently, holding on to a strict protocol for asepsis seems to be of importance when carrying out a pulpectomy.

8.5.4 Symptomatic Pulpitis

Many endodontic procedures begin in an emergency situation. Symptoms from an inflamed dental pulp vary from only enhanced sensitivity to thermal, osmotic, and tactile stimuli to conditions of severe lingering and tearing pain. Patients with pain may require pulpectomy in the long term, but in an emergency situation pulpotomy has a good effect. If pulpotomy can be applied with good results on longer term is not well known [13]. A recent published study seems to indicate that pulpotomy in molars performed with biocompatible materials may be as successful as pulpectomy in achieving favorable clinical results when performed by general dental practitioners [20].

8.6 Treatment of Pulp Necrosis and Apical Periodontitis

8.6.1 Pulp Necrosis and Asymptomatic Apical Periodontitis

Injury to the pulp may eventually lead to a complete breakdown of the tissue. The nonvital or necrotic pulp is defenseless against microbial invasion and will sooner or later be infected by indigenous microorganisms. No established methods exist to

allow for debridement and antimicrobial combat and a subsequent reestablishment of a vital adult pulp. However, ongoing research within this area may change the treatment options in the future [21]. For the time being, the only established treatment modality in teeth with completed root formation is root canal treatment. The root canal is cleaned in order to remove microbes and their substrates. In addition to irrigants, antimicrobial substances are used as dressings to enhance the antibacterial effect. A root canal treatment is finished as the tooth receives a permanent root filling. Postoperative discomfort sometimes follows, but after a short period most teeth become asymptomatic. Normally, the tooth is restored with a filling or crown immediately or a short while after completion.

8.6.2 Symptomatic Apical Periodontitis

Most teeth with pulp necrosis and apical periodontitis prevail without acute signs of inflammation. Nevertheless, symptoms may develop spontaneously or be initiated in conjunction with root canal treatment. The symptoms may vary from relatively mild pain to life-threatening situations with abscesses or cellulites. In an acute situation, the clinician needs to deliberate on the seriousness and deploy adequate measures. These can range from simple root canal instrumentation to incision of an abscess with or without prescription of analgesics and antibiotics. The appropriateness of different measures depends on the risk of the spread of infection and the patient's general health. When the acute phase has subsided, the affected tooth needs root canal treatment, which is performed in the same manner as for asymptomatic cases. There is no evidence that shows that teeth that have gone through a phase of symptomatic apical periodontitis have a worse prognosis than those that have not.

8.6.3 Successful Outcome of Root Canal Treatment

The desirable and best possible long-term outcome of root canal treatment is a retained and functional asymptomatic tooth with no clinical or radiographic signs of apical periodontitis. Ng et al. [4] identified 63 studies published from 1922 to 2002, which fulfilled their inclusion criteria for a review. The reported mean rates of a "successful" outcome ranged from 31 to 100%. This large variation could partly be the result of different radiographic criteria when evaluating the periradicular tissues on radiographs.

Despite the lack of high-quality scientific evidence, a meticulous analysis of the literature pointed out four circumstances that improve the possibility to maintain or reestablish healthy periradicular tissues in root-filled teeth: (i) preoperative absence of periapical radiolucency, (ii) root filling with no voids, (iii) root filling extending to 2 mm within the radiographic apex, and (iv) satisfactory coronal restoration [4], (Box 8.2). If these conditions are attainable, root canal therapy has been reported to be able to fulfill the requirements of "complete success" in 85–95% of cases.

Clinical experience and data from studies [4, 16, 18, 22, 23] have shown that root-filled teeth can be retained and stay healthy for many years.

Box 8.2. Prognostic Factors for Pulpectomy and Root Canal Treatment

Prognostic factors for pulpectomy and root canal treatment	Checklist
Enough remaining tooth structure for a restoration that can avoid or counteract with adverse masticatory forces	✓
Aseptic control and disinfection measures applied during treatment	✓
A root-filling without voids in all main root canals	✓
A root-filling extending to 2 mm within the radiographic apex	✓
A good-quality coronal restoration	✓

8.6.4 Unsuccessful Outcome of Root Canal Treatment

When root-filled teeth cause pain, it is usually a sign of infection. Especially so, if corresponding clinical findings in the form of swelling, tenderness, and fistulas at the same time are present. In situations like these, it is usually frank to diagnose a persistent, recurrent, or arising apical periodontitis. The treatment result is classified as a “failure.” There is an obvious indication for a new treatment intervention, retreatment, or extraction of the tooth (or sometimes only a root).

8.6.5 Asymptomatic and Functional but Persisting Radiological Signs of Apical Periodontitis

Nevertheless, a common situation is that the root-filled tooth is both subjective and clinically asymptomatic but an X-ray reveals that bone destruction has developed, or that the original bone destruction remains. In cases where no bony destruction was present when root canal treatment was completed, and in particular in cases of vital pulp therapy, it can be rationally assumed that microorganisms have entered in the root canal system. For teeth that showed clear bone destruction at the point of treatment, sufficient time must be allowed for healing and bone formation to occur.

8.6.6 Uncertainties in Classifying the Outcome into “Success” and “Failure”

The Time Factor

It is difficult to determine the amount of time that may be required for a periapical bone lesion to heal. A majority of root canal treated teeth with initial bone destruction show signs of healing within 1 year [24]. However, in individual cases, the

healing process can take a long time [22]. In a study by Molven et al. [23], it was reported that some cases had required more than 25 years to completely heal. The finding that there is no absolute time limit for when healing may eventually be diagnosed can also be deduced from epidemiological studies [16].

The Reliability and Validity of Radiographic Evaluation

The diagnosis of periapical tissues based on intraoral radiographs is subject to considerable interobserver and intraobserver variations [12].

There are also uncertainties regarding the validity of the radiographic examination. Only a limited number of studies have compared the histological diagnosis in root-filled teeth to radiographic signs of pathology [12, 25]. In these studies, false-positive findings (i.e., radiographic findings that indicate apical periodontitis while histological examination does not) are rare. The number of false-negative findings (i.e., radiographic evaluation indicates no apical periodontitis while histological examination gives evidence for inflammatory lesions) varies between the studies. However, from experimental studies, it is well known that bone destruction and consequently apical periodontitis may be present without radiographic signs visible in intraoral radiographs.

The advent of cone beam computed tomography (CBCT) has attracted much attention in endodontics in recent years [12]. In vitro studies on skeletal material point to that the method has higher sensitivity and specificity than intraoral periapical radiography. The higher sensitivity of CBCT is confirmed in clinical studies. CBCT provides a three-dimensional image of the area of interest, an advantage when assessing the condition of multirouted teeth. As a result, the reliability of results of endodontic treatment in follow-up using conventional intraoral radiographic technique has been questioned [26]. It has been suggested that CBCT should be used in future clinical studies, because conventional radiography systematically underestimates the number of teeth with osteolytic lesions. In this respect, long-term studies are required to investigate if healing of periapical bone destruction may take longer than previously assumed. Also, there is not enough scientific evidence to tell whether lesions on CBCT images provide accurate clues as to the histological diagnosis present. So far, there are also disadvantages of CBCT, such as greater cost and a potentially higher radiation dose. Up to date, there is no evidence that suggests that individuals with subjectively and clinically asymptomatic root canal treated teeth with normal appearance of surrounding bony structures in an intraoral radiographic examination would benefit from further evaluation by a CBCT scan.

Controversies of “Success” and “Failures” of Root Canal Treatment

Besides the time aspect of periapical bone lesions, there is also a problem with determination of what should be considered healing sufficient to constitute a “successful” endodontic treatment. As a consequence, the question of what establishes a “failure” and hence an indication for retreatment is far from unmistakable. According to the system launched by Strindberg [22], the only satisfactory post-treatment situation, after a predetermined healing period, combines a symptom-free patient with a

normal periradicular situation. Only cases fulfilling these criteria were classified as “success,” and all others as “failures.” In academic environments and in clinical research, this strict criteria set by Strindberg in 1956 [22] has had a strong position.

The periapical index (PAI) scoring system was presented by Ørstavik et al. [27]. The PAI provides an ordinal scale of five scores ranging from “healthy” to “severe periodontitis with exacerbating features” and is based on reference radiographs with verified histological diagnoses originally published by Brynolf [25]. The results from Brynolf’s work indicated that by using radiographs, it was possible to differentiate between normal states and inflammation of varying severity. However, the studies were based on a restricted biopsy material to upper anterior teeth. Among researchers, the PAI is well established, and it has been used in both clinical trials and epidemiological surveys. Researchers often transpose the PAI scoring system to the terms of Strindberg system by dichotomizing scores 1 and 2 to “success” and scores 3, 4, and 5 into “failure.” However, the “cutoff” line is arbitrary.

The Strindberg system, with its originally dichotomizing structure into “success” and “failure” has achieved status as a normative guide to action in clinical contexts. Consequently, when a new or persistent periapical lesion is diagnosed in a root-filled tooth, failure is at hand and retreatment (or extraction) is indicated.

However, as early as 1966, Bender and colleagues [28] suggested that arrested bone destruction in combination with an asymptomatic patient should be a sufficient condition for classifying a root canal treatment as an endodontic success. More recently, Friedman and Mor [29] as well as Wu et al. [30] have suggested similar less strict classifications of the outcome of root canal treatment.

Prevalence of “Failures”

The presence of subjective or clinical signs of failed root canal treatment is only occasionally reported in published follow-ups and epidemiological studies. The results are measured thus exclusively through an analysis of X-rays. In epidemiological cross-sectional studies, the frequency of periapical radiolucencies in root-filled teeth varies. In a systematic review of the matter, Pak et al. [31] included 33 studies from around the world with frequencies of failed cases varying from 12 to 72%. The weighted average of periapical radiolucencies in the 28,881 endodontically treated teeth included was 36%. The high frequency of root-filled teeth with periapical bone destructions seems to persist regardless of the fact that technical quality has improved over time [31]. Yet, cross-sectional studies cannot distinguish between cases that will finally heal and osteolytic lesions that will persist. On the other hand, longitudinal studies have shown that root-filled teeth without periapical radiolucent areas may develop visible lesions over time [16].

Consequences of “Endodontic Failures”

Persistent Pain

Surprisingly little is known about the frequency of pain from root-filled teeth. From the available data in follow-up studies from universities or specialist clinics, in a

systematic review, the frequency of persistent pain >6 months after endodontic procedures was estimated to be 5% [7].

Local Spread of Disease

A large majority of root-filled teeth with apical periodontitis remain asymptomatic. It is known that the inflammatory process occasionally turns acute with the development of local abscesses that have the potential for life-threatening spread to other parts of the body. Case reports in the literature describe the occurrence of more or less serious complications in the nearby organs (respiratory tract, brain), due to spread of bacterial infection from the root canals of teeth. However, the incidence and severity of exacerbation of apical periodontitis from root-filled teeth has met only scarce attention from researchers. A low risk of painful exacerbations (1–2%) was reported from a cohort of 1032 root-filled teeth followed over time by Van Nieuwenhuysen et al. [32]. In a report from a university hospital clinic in Singapore where 127 patients with 185 nonhealed root-filled teeth were recruited [33]. Flare-ups occurred only in 5.8% over a period of 20 years. Less severe pain was experienced by another 40% over the same time period. The incidence of discomforting clinical events was significantly associated with female patients, treatments involving a mandibular molar or maxillary premolar, and preoperative pain.

Systemic Effects

Oral infections have been associated increasingly with severe systemic diseases, such as atherosclerosis, stroke, and even cancer. The potential of an association between chronic marginal periodontitis and cardiovascular disease is recognized in numerous reports. Indeed, the increasing numbers of reports of a relationship between atherosclerotic vascular diseases prompted a systematic review and American Heart Association Scientific Statement that examined possible correlations [34]. However, no clear answers to the questions about the possible causative relationship between atherosclerotic vascular disease and periodontal disease could be established.

Less attention has been given to a corresponding association with disease processes originating in the dental pulp. The scientific basis is insufficient to assess the association between infections of endodontic origin and disease conditions of other organs [9].

Disease Concepts

To retreat or not to retreat “an endodontic failure” is the issue. It has been argued that both modern medicine and dentistry face fundamental ethical problems if too rigorous and consistent concepts of disease prevail. The discussion about different concepts of disease goes back to ancient philosophy and has bewildered and occupied philosophers ever since. In this book about molar endodontics, we can only hint at the fundamental issues. For further reading, the interested reader should seek in books on philosophy of medicine [35].

Two fundamentally different concepts of disease can traditionally be recognized.

The *naturalist theory* defines disease in terms of biological processes. Disease is a value-free concept, existing independently of its social and cultural contexts. Disease is discovered, studied, and described by means of science.

The *normativist theory*, on the other hand, declares that there is no value-free concept of disease. Rather than discovered, the concept of disease is invented. It is contextual and given by convention.

These theories address different aspects and pose different challenges to medicine and dentistry as a whole and therefore also to endodontics. But the two predominant concepts have been challenged for several reasons. For example, they neither separately nor together fully acknowledge all important perspectives on human disorders. An alternative approach is to apply the “triad of disease, illness, and sickness” [36] (Box 8.3). Despite criticism, the triad is widely used and discussed. The definition of the triad’s different components is by no way clear-cut. The triad and its implications on dentistry were elaborated by Hofmann and Eriksen [37]. Kvist et al. [38] made cautious and initial attempts to apply the theory to the problem of asymptomatic root-filled teeth with radiographic signs of apical periodontitis.

Box 8.3. An Attempt to Apply the Triad of Disease, Illness, and Sickness to Root-Filled Teeth with Signs of Apical Periodontitis

	Disease	Illness	Sickness
Phenomena studied	Pathophysiological, histological, microbiological, and radiographic events	Pain, swelling, or other symptoms presented now or in the future	Criteria for classification and grading of disease
Validity	Objective	Subjective	Intersubjective
Purpose from the professions’ point of view	To study the medical facts of apical periodontitis in order to improve knowledge of how to prevent and cure	To identify and describe the incidence, frequency, and intensity for patient-related outcomes (pain, swelling, spread)	To decide upon common criteria for classification, define different severities of disease, and construct decision aids to guide clinical action
Purpose from patients’ point of view	To get an explanation of the situation	To value and accept or not accept the situation	To understand what is regarded “sick,” respectively “healthy,” and to be helped to make a clinical decision in his or her situation

Disease means the disorder in its physical form, the biological nature, the clinical, and paraclinical findings (histology, microbiology, radiography, etc.).

Illness is used to describe a person’s own experience of the disease, how it feels, and what sufferings it gives now or in the future. Illness also includes anxiety and anguish.

Sickness is the third label; it tries to capture the social role of a person who has illness or disease (or both) in a particular cultural context. What is eligible for being “sick” can consequently vary over time and between societies.

The three approaches to disease do not replace but complement each other. It is also the case that they are strongly intertwined. However, using the above matrix of “disease,” “illness,” and “sickness” makes it easier to understand the variation in clinical decision-making regarding root-filled teeth with persistent apical lesions, both when it is tested in different setups by researchers as well as in the clinical situation with an individual patient.

Patient Values

In front of a situation with a root-filled tooth with persistent apical periodontitis, dentists and their patients choose different clinical management despite identical information. Both doctors’ and patients’ values will influence the decision-making process. The concept of value has many aspects, but it is reasonable to suppose that there is a close connection between an individual’s values and his or her preferences and value judgments. The concept of personal values in clinical decision-making about apical periodontitis has been explored among both dental students and specialists by Kvist and Reit [39]. Substantial interindividual variation was registered in the evaluation of asymptomatic apical periodontitis in root-filled teeth. From a subjective point of view, some patients will benefit much more from endodontic retreatment than others (Box 8.4).

Box 8.4. Checklist for the Outcome of Endodontic Treatment of the Root Canal System

Evaluation	Signs of favorable outcome	Checklist
Subjective symptoms	Asymptomatic, comfortable and functional	✓
Restoration	Good-quality restoration with no signs of caries	✓
Periradicular tissues Clinical	No signs of swelling, redness, or fistula No deep probing depths	✓
Periradicular tissues Radiographic	No, or only small signs of periradicular bone destruction Or, a periradicular bone destruction of decreasing size over time	✓

Today, patient autonomy is widely regarded as a primary ethical principle, emphasizing the importance of paying attention to the values and preferences of each individual patient.

Variation in Clinical Decisions About “Endodontic Failures”

The diagnostic difficulties, timing, the question of what should be regarded as healthy and diseased, patient values, as well as several other factors partly explain

the large variation among dentists regarding retreatment decision-making. This situation has been highlighted in numerous publications. The issue was comprehensively reviewed by Kvist [40]. From the many investigations conducted, it stands clear that the mere diagnosis of persisting periapical bone destruction in a root-filled tooth does not consistently result in decisions for retreatment among clinicians. Theoretically, four options are available:

1. To accept the situation and leave it without further follow-ups or treatment
2. To accept the situation for time being and expose the tooth for continued follow-up
3. To extract the tooth (or root)
4. To endodontically retreat the tooth

If retreatment is selected, the decision-maker also has to make a choice between a surgical and nonsurgical approach.

Our discussion will be adequate if it has as much clearness as the subject-matter admits of, for precision is not to be sought for alike in all discussions,...for it is the mark of an educated man to look for precision in each class of things just so far as the nature of the subject admits. Aristotle (350 BC) *Nicomachean Ethics*. Translated by: W D Ross.

8.6.7 Tooth Retention Over Time

Two longitudinal studies in Scandinavian populations found that 12–13%, respectively, of the teeth that were root filled at the baseline examination were extracted at follow-up approximately 10 years later [16, 41]. In the Danish population, it was found that teeth with apical periodontitis (nonroot-filled and root-filled) had six times higher risk of being lost than periapically healthy teeth [42]. However, findings suggest that other causes than apical periodontitis such as periodontal disease, caries, or root fracture are frequently present when root-filled teeth are extracted [43, 44].

In a systematic review on tooth survival following nonsurgical root canal treatment, 14 studies published between 1993 and 2007 were included. The authors concluded that the pooled proportion of teeth surviving over 2–10 years ranged between 86 and 93% [6]. Four prognostic factors were found to significantly improve tooth survival: (i) A crown restoration after completion of root canal treatment, (ii) tooth having both approximal contacts, (iii) tooth not functioning as an abutment in a prosthodontic construction, and (iv) not being a molar tooth. However, the authors pointed to the fact that the results of the review should be interpreted with care because of the methodological limitations of available studies.

For example, it is difficult to tell whether the observed correlations are causative or a consequence of biased selection of cases. It seems likely that dentists and their patients, would be more prone to invest in placing a crown on a tooth with perceived good prognosis rather than on the one with questionable forecast. Consequently, the finding about the positive effect of the crown placement may be a self-fulfilling prophecy. The reason why molars, teeth without approximal contacts and abutments in prosthesis more often have been extracted in a follow-up may be a result of the

fact that these teeth are more dispensable and acceptable to extract from a patient's point of view if any additional signs of disease appears. In the above-mentioned review, the authors concluded that the available data support the common opinion among clinicians that tooth survival is likely to be influenced by the strength and integrity of the remaining tooth tissue and the manner in which forces are distributed within the remaining tooth tissue when in masticatory function.

8.7 Retreatment

8.7.1 Surgical or Nonsurgical Retreatment

Chronic periapical asymptomatic lesions as well as exacerbation or aggravation of persistent apical periodontitis of root-filled teeth may be cured by endodontic nonsurgical or surgical retreatment. There is insufficient scientific support on which to determine whether surgical and nonsurgical retreatments of root-filled teeth give systematically different outcomes, both in the short and long terms, with respect to healing of apical periodontitis or tooth survival [3, 8, 9]. In clinical practice, a number of factors influence the choice of treatment, for example, the size of the bone destruction, the technical quality of previous treatment, accessibility to the root canal, future restorative requirements of the tooth, the cost of treatment, the preferences of the clinician and the patient, medical considerations, the availability of various types of special equipment.

The clinical decisions will have to be made on the basis of unique conditions applying to every case.

8.7.2 The Size of the Bone Destruction

Apical periodontitis may develop into cysts. Periapical cysts are classified as "pocket-cysts" or "true-cysts." In case of a pocket cyst, the cyst cavity is expected to heal after proper conventional root canal treatment. A true cyst, on the other hand, is supposed not to respond to any intracanal treatment efforts. Thus, it is supposed that true radicular cysts have to be surgically resected in order to heal [45]. Unfortunately, there is no scientific evidence to clinically determine the histological diagnosis of the periapical tissue in general, and in particular, there is no method to distinguish between pocket-cysts and true-cysts other than histology [12]. However, cysts are expected to be more predominant among large bony lesions [46]. Thus, in case of large bone destruction, much speaks for a surgical retreatment.

8.7.3 The Technical Quality of the Previous Treatment

In cases of nonhealed apical periodontitis, the technical quality of the root filling is often poor [31]. In molars, the reason for treatment failure may be associated with

untreated canals. In many cases, therefore, a nonsurgical retreatment should be considered. In particular, this is the case when access is not hindered by a crown and post. Since there is convincing findings that the quality of the restoration also plays a significant part for the periapical status in root filled teeth [11] the clinician is recommended to have a critical look at the restoration. If restoration is of poor quality, it may jeopardize the results of an endodontic surgery [15].

The obvious objective for a nonsurgical retreatment is to treat the previously untreated parts of the root canal system and thus improve the quality of root canal filling. With the help of modern endodontic armament, this is often possible to achieve. Studies have shown that nonsurgical retreatment performed by skillful clinicians results in good chances of achieving periapical healing [47, 48].

Several authors have argued that the result of endodontic surgery is dependent on the good quality of the root filling, and consequently argued that any endodontic surgery should be preceded by a nonsurgical retreatment. No clear evidence exists of the benefit of this approach, and it would moreover, if used orderly, lead to the execution of a significant amount of unnecessary surgeries. In many cases, the nonsurgical retreatment *per se* would be enough to achieve healing of the periapical tissues.

8.7.4 Accessibility to the Root Canal

Root-filled teeth are often restored with posts and crowns, and are frequently used as abutments for bridges and other prosthodontic constructions which have to be removed or passed through for a nonsurgical approach. In cases where the quality of restorations is adequate, a surgical approach is more appealing. Even without hindering restorations, a preoperative analysis of the case may reveal intracanal ledges or fractured instruments that already preoperatively make the accessibility to the site of the residual infection questionable [47].

On the other hand, access to the site of infection by endodontic surgery can be judged to imply major difficulties. In particular, surgery involving mandibular molar roots as well as palatal roots of the maxillary molars sometimes offers significant operator challenges. Preoperative CBCT scans help the surgeon to plan the intervention or sometimes to refrain and choose a nonsurgical approach, or even considering extraction and a different treatment plan (Fig. 8.1).

8.7.5 Future Restorative Requirements of the Tooth

Before considering retreatment of a previously root-filled tooth, there is a need for careful deliberation of the overall treatment plan. In many cases, the issue is rather straightforward. It might concern a single tooth, restored with a post and a crown of fully acceptable quality, but with an ensured diagnosis of persistent apical periodontitis. The objective is to cure the disease and to “save” the tooth and its restoration in the long term. In other situations, when complete mouth restorations are planned

to “build something new,” the strategic use of teeth, nonroot filled as well as root filled, and dental implants to minimize the risk of failure of the entire restoration must be the first priority [49].

8.7.6 The Cost of Treatment

Since surgical endodontics does not require the dismantling of functional prosthodontics constructions, it is often a less expensive alternative for the patient. But, the costs of both surgical and nonsurgical treatments, of course, vary both in different countries between operators and between countries with different systems of reimbursement by insurance.

8.7.7 The Preferences of the Clinician and the Patient

Whether a retreatment, nonsurgical or surgical, should be performed is a complex decision, with many factors to be considered. When a diagnosing dentist is asked to suggest a treatment plan with alternatives, both biological considerations and the potential and limitations of different options weigh in. However, as important as the professional skill and knowledge might be, the preferences of each individual patient will also influence the final decision. The subjective meaning (“the illness”) of the situation (“the disease”) will vary among patients. Only the patient is the expert on how he or she feels about keeping a tooth, with or without retreatment, or perhaps extracting it, as well as which symptoms are tolerable, which risks are worth taking, and what costs are acceptable.

8.7.8 Modern Times: Improved Outcomes

During the last 20-year period, clinical endodontics has undergone a technological development of rare unprecedented proportions. Rotary instrumentation alloys have facilitated the painstaking work of removing old root fillings. Super-flexible properties of nickel-titanium instruments allow root canals to be successfully instrumented in a predictable way.

An equally significant addition to the endodontic armamentarium is the operating microscope. With its help, previously untreated parts of the root canal system can be visualized during both surgical and nonsurgical retreatments. Parallel with the increasing use of the operating microscope, a wide range of specialized instruments have been developed, primarily in connection with surgical endodontics. In addition, the introduction of ultrasonic instruments has further improved treatment options.

Much effort has also been expended on trying to develop new materials for safer retrograde sealing of the root canal. Alternatively, technological achievements have significantly changed the clinical routine of endodontic retreatment procedures.

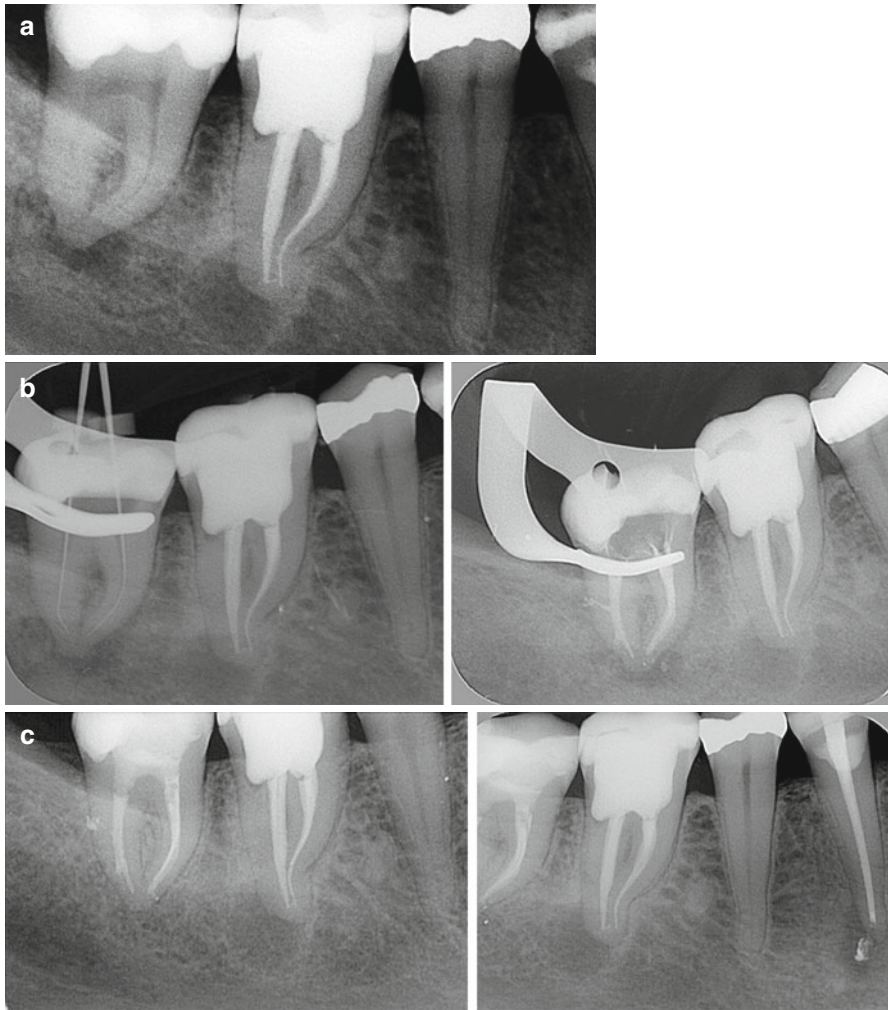

Fig. 8.1 Radiographs showing details for the evaluation and treatment of the left mandibular second molar (tooth 46 FDI or #30 Universal). The patient is female, born 1945. There is pain from lower right jaw region; the tooth in question was root canal-treated 3 years earlier. Both right mandibular molars are tender to percussion, and the second molar is not sensitive to electric and thermal pulp testing. Radiographically, there are radiolucent areas associated with both molars. (a) Preoperative periapical radiograph. (b) *Left and right*, Root canal treatment of 47 (#31). Note the fill of lateral canal. (c) *Left and right*, Follow-up after 6 months. Asymptomatic patient. Note that 44 (#28) also has a root filling and a periapical radiolucent area. (d) *Left and right*, Additional follow-up 1 year later. Note bone fill apically to 47 (#31) and 44 (#28). However, periapical radiolucent area 46 (#30) persists. The tooth is slightly tender to percussion. The decision is made to perform surgical retreatment 46 (#30). (e) Immediate postoperative surgery 46 (#30). (f) *Left and right*, 1-year follow-up after surgery. Patient asymptomatic. Good healing of periapical lesions 47, 46, 44 (#31, 30, 28)

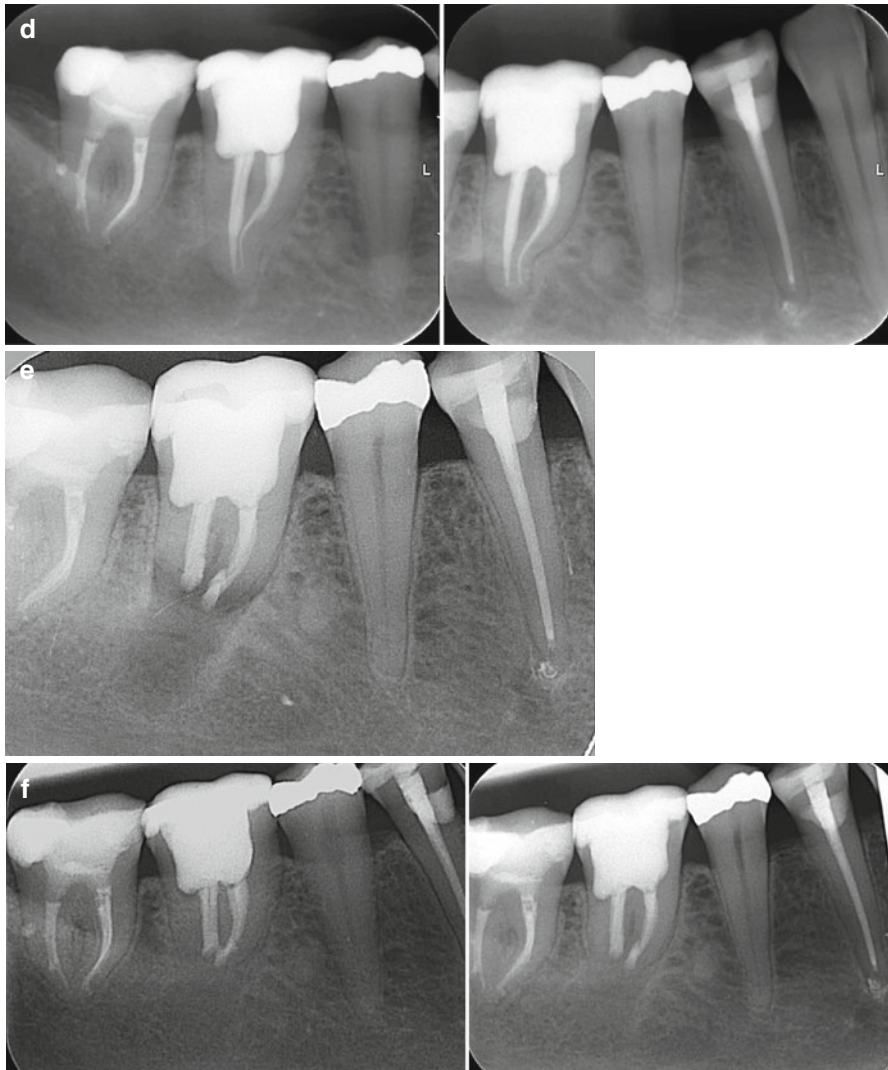


Fig. 8.1 (continued)

In environments of clinical excellence, nonsurgical as well as surgical retreatments have shown favorable outcomes on the periapical tissues of “endodontic failures” [15, 48, 49]. It is likely that more root-filled teeth with apical periodontitis can be successfully treated surgically compared with reports from that before microsurgical techniques were used [15, 50]. Frequency of periapical healing after retreatment has been reported to reach approximately 80–90% for both methods [15, 48]. High-quality clinical studies of long-term follow-up of teeth that have undergone surgical or retreatment are still missing.

8.7.9 Endodontic Retreatment: Need for Research

In the future, there is need for more research on endodontic retreatment methods as to whether they are effective and result in long-term tooth survival. In this context, it is also important to evaluate the alternatives to retreatment, extraction, and replacement by a tooth-supporting bridge or an implant from the perspective of quality of life and cost effectiveness [2, 9].

8.8 Conclusion

8.8.1 Short Answers to Clinical Questions

This chapter on molar endodontics shows that there is a considerable documentation gathered through the years about the methods that are used for preventing and treating diseases originating from the pulp and periradicular tissues. From the bulk of information, it can be concluded that various forms of endodontic treatments have saved and continue to save billions of molar teeth afflicted by caries or other insults.

Based on current best empirical and scientific knowledge, the following general short answers to “the clinical questions” may be appropriate:

- What will happen to my tooth and me if pulpitis or apical periodontitis is left untreated?
 - The tooth may stay asymptomatic for a long time, but there is also a risk of periods of pain and, in a worst-case scenario, local spread of infection.
- What different treatment options do I have if I decide to keep my tooth?
 - If the pulp is still vital, there are often reliable methods that can be used to try to save the integrity of the pulp and avoid root canal treatment. However, if pulp is seriously injured, which is very difficult to predict, pain or pulp necrosis may occur. In such a case, root canal treatment may be necessary.
- After treatment, will my symptoms disappear?
 - After treatment, there may be a short period of postoperative pain, but if endodontic procedures are performed according to a high standard protocol your symptoms will almost invariably disappear. Approximately 95 % of root-filled teeth are asymptomatic after a postoperative period of 6 months.
- How does the disease and treatment affect my risk of losing the tooth?
 - The risk of losing a tooth with severe injury to the pulp is higher than for a healthy tooth, in particular, if the pulp vitality is lost and there is a need for root canal treatment. But if properly treated and restored, approximately 90 % of root-filled teeth survive 10 years or more.
- Will treatment cure pulpitis or apical periodontitis?

- Yes, using current methods used in endodontics, in 80–90 % of the cases, no signs of disease will be present at a standard clinical and radiographic checkup carried out a few years after treatment.
- Is there a risk of persistence or relapse of disease?
 - In about 10 % of root canal treated cases, signs of disease may persist over time. If your restoration of the tooth is lost or if endodontic procedures are inadequately performed, disease may also relapse.
- What will be my options, if persistence or relapse does occur?
 - In cases with persistent disease, surgical or nonsurgical retreatment performed by skilled specialists using modern armamentarium is able to cure the disease in about 80–90 % of the cases.
- Would it be a better idea to take the tooth out?
 - In most cases not. But if the tooth is afflicted by periodontal disease or the remaining tooth substance does not provide conditions for a high-quality restoration, it might be a better idea.
- If so, can it be replaced?
 - In the majority of cases, a lost tooth can be replaced by an implant or a fixed prosthesis.

8.8.2 Knowledge Gaps

There are few clinical studies of high scientific quality within the field of endodontics. Consequently, there are many knowledge gaps [9]. Further clinical studies with high quality are necessary to give our patients less vague answers to the following questions:

- In a situation with a tooth with a vital pulp that is afflicted by deep caries, is it better to preserve the pulp vitality rather than to perform pulpectomy and root filling?
- Is it more cost-effective in long term to have a root canal treatment and restoration rather than to extract the tooth and replace it with a fixed prosthesis or an implant?
- Which specific treatment factors explain why endodontic treatments do not achieve an optimal outcome, that is, get extracted, remain painful, develop or have persistent apical periodontitis?
- Will root-filled teeth survive long term, and what factors influence the loss of endodontically treated teeth?
- How often will a root-filled tooth with persistent but asymptomatic periapical inflammation result in the occurrence of pain and swelling?
- Which are the prognostic factors to predict an exacerbation of asymptomatic periapical inflammation, particularly in a root-filled tooth?
- Are there any risks to general health when teeth with a periodical inflammatory process remain untreated?

References

1. Ng YL, Mann V, Rahbaran S, Lewsey J, Gulabivala K. Outcome of primary root canal treatment: systematic review of the literature – part 1. Effects of study characteristics on probability of success. *Int Endod J.* 2007;40:921–39.
2. Torabinejad M, Anderson P, Bader J, Brown LJ, Chen LH, Goodacre CJ, Kattadiyil MT, Kutsenko D, Lozada J, Patel R, Petersen F, Puterman I, White SN. Outcomes of root canal treatment and restoration, implant-supported single crowns, fixed partial dentures, and extraction without replacement: a systematic review. *J Prosthet Dent.* 2007;98(4):285–311.
3. Del Fabbro M, Taschieri S, Testori T, Francetti L, Weinstein RL. Surgical versus non-surgical endodontic re-treatment for periradicular lesions (Review). *The Cochrane Collaboration and published in the Cochrane Library.* 2008;(4).
4. Ng YL, Mann V, Rahbaran S, Lewsey J, Gulabivala K. Outcome of primary root canal treatment: systematic review of the literature – part 2. Influence of clinical factors. *Int Endod J.* 2008;41:6–31.
5. Ng YL, Mann V, Gulabivala K. Outcome of secondary root canal treatment: a systematic review of the literature. *Int Endod J.* 2008;41(12):1026–46.
6. Ng YL, Mann V, Gulabivala K. Tooth survival following non-surgical root canal treatment: a systematic review of the literature. *Int Endod J.* 2010;43(3):171–89.
7. Nixdorf DR, Moana-Filho EJ, Law AS, McGuire LA, Hodges JS, John MT. Frequency of persistent tooth pain after root canal therapy: a systematic review and meta-analysis. *J Endod.* 2010;36:224–30.
8. Torabinejad M, Corr R, Handysides R, Shabahang S. Outcomes of nonsurgical retreatment and endodontic surgery: a systematic review. *J Endod.* 2009;35:930–7.
9. Swedish Council on Health Technology Assessment. Methods of diagnosis and treatment in endodontics—a systematic review. 2010; Report nr 203:1–491. <http://www.sbu.se>.
10. Aguilar P, Linsuwanont P. Vital pulp therapy in vital permanent teeth with cariously exposed pulp: a systematic review. *J Endod.* 2011;37(5):581–7.
11. Gillen BM, Looney SW, Gu LS, Loushine BA, Weller RN, Loushine RJ, Pashley DH, Tay FR. Impact of the quality of coronal restoration versus the quality of root canal fillings on success of root canal treatment: a systematic review and meta-analysis. *J Endod.* 2011;37:895–902.
12. Petersson A, Axelsson S, Davidson T, Frisk F, Hakeberg M, Kvist T, Norlund A, Mejåre I, Portenier I, Sandberg H, Tranaeus S, Bergenholtz G. Radiological diagnosis of periapical bone tissue lesions in endodontics: a systematic review. *Int Endod J.* 2012;45(9):783–801.
13. Bergenholtz G, Axelsson S, Davidson T, Frisk F, Hakeberg M, Kvist T, Norlund A, Petersson A, Portenier I, Sandberg H, Tranaeus S, Majare I. Treatment of pulps in teeth affected by deep caries- a systematic review of the literature. *Singapore Dent J.* 2013;34:1–12.
14. Ricketts D, Lamont T, Innes NP, Kidd E, Clarkson JE. Operative caries management in adults and children. *Cochrane Database Syst Rev.* 2013;(3):CD003808.
15. Tsesis I, Rosen E, Taschieri S, Telishevsky Strauss Y, Ceresoli V, Del Fabbro M. Outcomes of surgical endodontic treatment performed by a modern technique: an updated meta-analysis of the literature. *J Endod.* 2013;39(3):332–9.
16. Kirkevang LL, Vaeth M, Wenzel A. Ten-year follow-up observations of periapical and endodontic status in a Danish population. *Int Endod J.* 2012;45(9):829–39.
17. Whitworth JM, Myers PM, Smith J, Walls AW, McCabe JF. Endodontic complications after plastic restorations in general practice. *Int Endod J.* 2005;38:409–16.
18. Gesi A, Hakeberg M, Warfvinge J, Bergenholtz G. Incidence of periapical lesions and clinical symptoms after pulpectomy – a clinical and radiographic evaluation of 1- versus 2-session treatment. *Oral Surg Oral Med Oral Pathol Oral Radiol Endod.* 2006;101(3):379–88.
19. Engström B, Lundberg M. The correlation between positive culture and the prognosis of root canal therapy after pulpectomy. *Odontol Revy.* 1965;16:193–203.

20. Asgary S, Eghbal MJ, Ghoddsi J, Yazdani S. One-year results of vital pulp therapy in permanent molars with irreversible pulpitis: an ongoing multicenter, randomized, non-inferiority clinical trial. *Clin Oral Investig*. 2013;17:431–9.
21. Andreasen JO, Bakland LK. Pulp regeneration after non-infected and infected necrosis, what type of tissue do we want? A review. *Dent Traumatol*. 2012;28(1):13–8.
22. Strindberg LZ. The dependence of the results of pulp therapy on certain factors. *Acta Odontologica Scandinavica*. 1956;14 (Suppl 21).
23. Molven O, Halse A, Fristad I, MacDonald-Jankowski D. Periapical changes following root-canal treatment observed 20–27 years postoperatively. *Int Endod J*. 2002;35:784–90.
24. Ørstavik D. Time-course and risk analyses of the development and healing of chronic apical periodontitis in man. *Int Endod J*. 1996;29:150–5.
25. Brynolf I. Histological and roentgenological study of periapical region of human upper incisors. *Odontologisk Revy*. 1967;18 (Suppl 11).
26. Wu MK, Shemesh H, Wesselink PR. Limitations of previously published systematic reviews evaluating the outcome of endodontic treatment. *Int Endod J*. 2009;42:656–66.
27. Ørstavik D, Kerekes K, Eriksen HM. The periapical index: a scoring system for radiographic assessment of apical periodontitis. *Endod Dent Traumatol*. 1986;2:20–34.
28. Bender IB, Seltzer S, Soltanoff W. Endodontic success- a reappraisal of criteria. *Oral Surg Oral Med Oral Pathol*. 1966;22:780–802.
29. Friedman S, Mor C. The success of endodontic therapy – healing and functionality. *J Calif Dent Assoc*. 2004;32(6):493–503.
30. Wu MK, Wesselink P, Shemesh H. New terms for categorizing the outcome of root canal treatment. *Int Endod J*. 2011;44:1079–80.
31. Pak JG, Fayazi S, White SN. Prevalence of periapical radiolucency and root canal treatment: a systematic review of cross-sectional studies. *J Endod*. 2012;38(9):1170–6.
32. Van Nieuwenhuysen JP, Aouar M, D’Hoore W. Retreatment or radiographic monitoring in endodontics. *Int Endod J*. 1994;27(2):75–81.
33. Yu VS, Messer HH, Yee R, Shen L. Incidence and impact of painful exacerbations in a cohort with post-treatment persistent endodontic lesions. *J Endod*. 2012;38:41–6.
34. Lockhart PB, Bolger AF, Papapanou PN, et al.; on behalf of the American Heart Association Rheumatic Fever, Endocarditis, and Kawasaki Disease Committee of the Council on Cardiovascular Disease in the Young, Council on Epidemiology and Prevention, Council on Peripheral Vascular Disease, and Council on. Periodontal disease and atherosclerotic vascular disease: does the evidence support an independent association? A scientific statement from the American Heart Association. *Circulation*. 2012;125:2520–44.
35. Wulff HR, Pedersen SA, Rosenberg R. *Philosophy of medicine: an introduction*. 2nd ed. Oxford: Blackwell Scientific; 1990.
36. Hofmann B. On the triad disease, illness and sickness. *J Med Philos*. 2002;27:651–73.
37. Hofmann BM, Eriksen HM. The concept of disease: ethical challenges and relevance to dentistry and dental education. *Eur J Dent Educ*. 2001;5:2–8; discussion 9–11.
38. Kvist T, Heden G, Reit C. Endodontic retreatment strategies used by general dental practitioners. *Oral Surg Oral Med Oral Pathol Oral Radiol Endod*. 2004;97:502–7.
39. Kvist T, Reit C. The perceived benefit of endodontic retreatment. *Int Endod J*. 2002;35:359–65.
40. Kvist T. Endodontic retreatment. Aspects of decision making and clinical outcome. *Swed Dent J Suppl*. 2001;144:1–57.
41. Petersson K, Håkansson R, Håkansson J, Olsson B, Wennberg A. Follow-up study of endodontic status in an adult Swedish population. *Endod Dent Traumatol*. 1991;7:221–5.
42. Bahrami G, Væth M, Kirkevang LL, Wenzel A, Isidor F. Risk factors for tooth loss in an adult population: a radiographic study. *J Clin Periodontol*. 2008;35:1059–65.
43. Vire DE. Failure of endodontically treated teeth: classification and evaluation. *J Endod*. 1991;17(7):338–42.
44. Landys Borén D, Jonasson P, Kvist T. Long-term survival of endodontically treated teeth at a public dental specialist clinic. *J Endod*. 2015;41:176–81.

45. Nair PN. New perspectives on radicular cysts: do they heal? *Int Endod J.* 1998;31:155–60.
46. Natkin E, Oswald RJ, Carnes LI. The relationship of lesion size to diagnosis, incidence, and treatment of periapical cysts and granulomas. *Oral Surg Oral Med Oral Pathol.* 1984;57:82–94.
47. Gorni FG, Gagliani MM. The outcome of endodontic retreatment: a 2-yr follow-up. *J Endod.* 2004;30:1–4.
48. Ng YL, Mann V, Gulabivala K. A prospective study of the factors affecting outcomes of non-surgical root canal treatment: part 1: periapical health. *Int Endod J.* 2011;44:583–609.
49. Zitzmann NU, Krastl G, Hecker H, Walter C, Waltimo T, Weiger R. Strategic considerations in treatment planning: deciding when to treat, extract, or replace a questionable tooth. *J Prosthet Dent.* 2010;104(2):80–91.
50. Setzer FC, Shah SB, Kohli MR, Karabucak B, Kim S. Outcome of endodontic surgery: a meta-analysis of the literature – part 1: comparison of traditional root-end surgery and endodontic microsurgery. *J Endod.* 2010;36(11):1757–65.

Nonsurgical Root Canal Retreatment

9

Elio Berutti and Arnaldo Castellucci

Abstract

Conventional endodontic therapy enjoys a high success rate; however, root canal treatment in cases of pulpal necrosis and cases with procedural errors will occasionally fail. Retreating such cases is often a challenge for clinicians. This chapter discusses both the diagnosis of retreatment needs and the steps to regain access to the previously treated root canal system. In cases where satisfactory retreatment is impossible and healing cannot be expected, strategies for further decision-making are presented.

Guiding Reference

Gorni FG, Gagliani MM. The outcome of endodontic retreatment: a 2-yr follow-up. *J Endod.* 2004; 30(1):1–4.

This retrospective study of nonsurgical retreatment compares clinical and radiographic outcome criteria in cases that had procedural errors that could be corrected and those that were not overcome. The overall success, defined as absence of symptoms and evidence of intact periapical tissue, was 69%, but this number was significantly reduced in the cases when not correctable alterations in the natural course of the root canals were found, caused by previous root canal treatment.

E. Berutti, MD, DDS
Department of Endodontics, University of Turin, Turin, Italy

A. Castellucci, MD, DDS (✉)
University of Naples Federico II, Naples, Italy
University of Cagliari, Cagliari, Italy

Private Practice, Via degli Artisti 6/R, Florence 50132, Italy
e-mail: catellucciarnaldo@gmail.com

9.1 Introduction

Conventional endodontic therapy enjoys a high success rate, oftentimes enabling clinicians to restore teeth to a lifetime of function. Depending on the pretreatment diagnosis, success rates remain significantly lower in infected teeth than in teeth with no radiographic signs of microbial contamination, and most retreatment cases fall into that category.

Retreating failed root canal therapy, be it due to leaking restorations or insufficient primary treatment, is one of the greatest challenges in root canal therapy. Once the need for a revision has been determined, a clinician may be faced with a broad spectrum of materials that occlude the original root canal space, including portions of root canal instruments. These materials can be easy or exceedingly difficult to remove and may be accompanied by preparation errors that preclude accessibility. Even the most diligent attempts to clean all aspects of a given pulp space of previously introduced materials may be futile at times.

This chapter will discuss both the diagnosis of retreatment needs and the steps to regain access to the previously treated root canal system. In cases where satisfactory retreatment is impossible and healing cannot be expected, strategies for further decision-making will be presented (see also preceding Chap. 8).

9.2 Definition of Root Canal Retreatment

According to the American Association of Endodontists Glossary of Contemporary Terminology for Endodontics [1], retreatment is defined as follows:

A procedure to remove root canal filling materials from the tooth followed by cleaning, shaping and obturating of the canals

This definition is somewhat limited in scope because it does not consider situations where there is no previous filling material to be removed, nevertheless the case is failing and needs to be “retreated.” A typical situation is shown in Fig. 9.1 where a general dentist, even in a single-rooted tooth, could not locate the original canal and referred the patient for completion. In an attempt to locate the original canal, a perforation occurred on the distal aspect of the middle third of the root. This case should be considered a retreatment, even though there was no filling material to be removed. Using the operating microscope, the original canal was located, the perforation was repaired with MTA, and the root canal system was then conventionally root-filled.

Figure 9.2 shows a case that had previously been surgically treated; the retreatment of this maxillary molar includes nonsurgical cleaning, shaping, and obturating the root canal system. This case, too, must be considered a retreatment, even though there was no previous filling material to remove from the canals. Figure 9.3 shows a maxillary first molar treated with a missed second mesiobuccal (MB2) canal. The

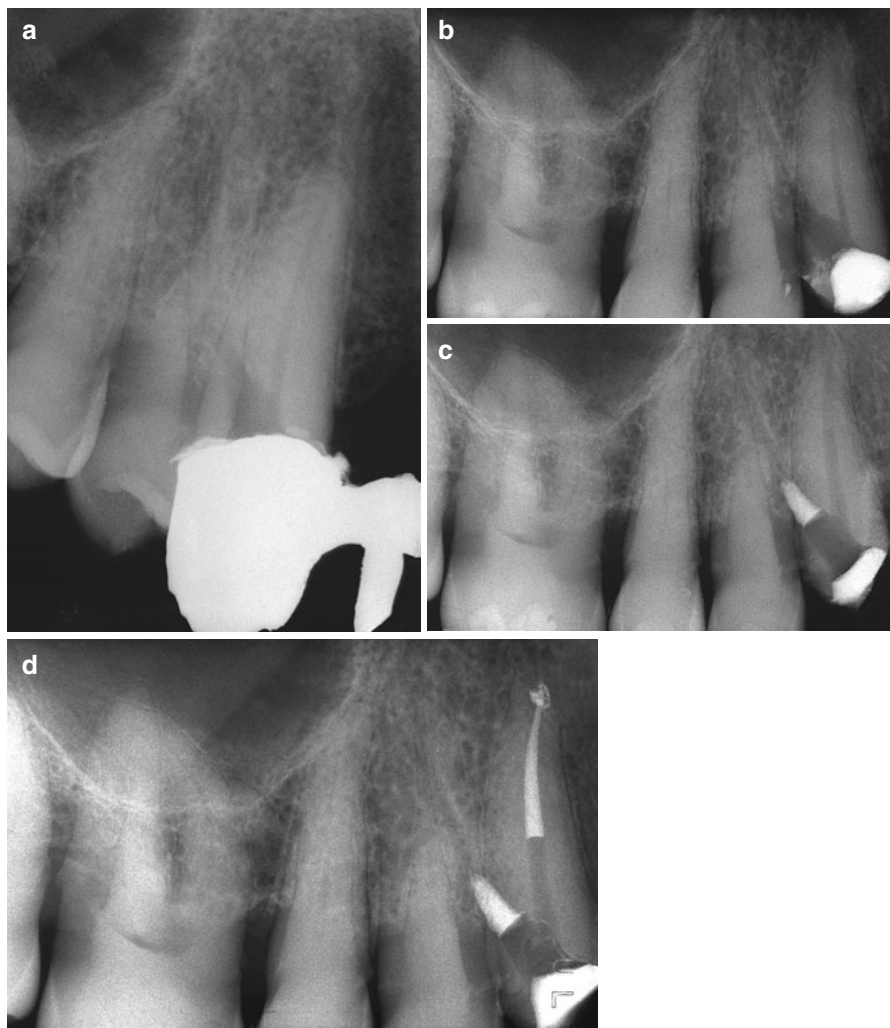


Fig.9.1 (a) A preoperative film of a maxillary cuspid with a perforation on the distal aspect of the coronal one-third. (b) The off-angle radiograph shows better the perforation. (c) The perforation has been repaired with MTA. (d) Postoperative radiograph

tooth was nonsurgically retreated, but no filling materials were removed from the missed canal.

The following definition is offered according to Carr [2] as an alternative that more closely reflects the actual clinical practice of retreatment: Endodontic retreatment is a procedure performed on teeth that received failed prior attempts at definitive root canal treatment, requiring further endodontic therapy to achieve a successful result.

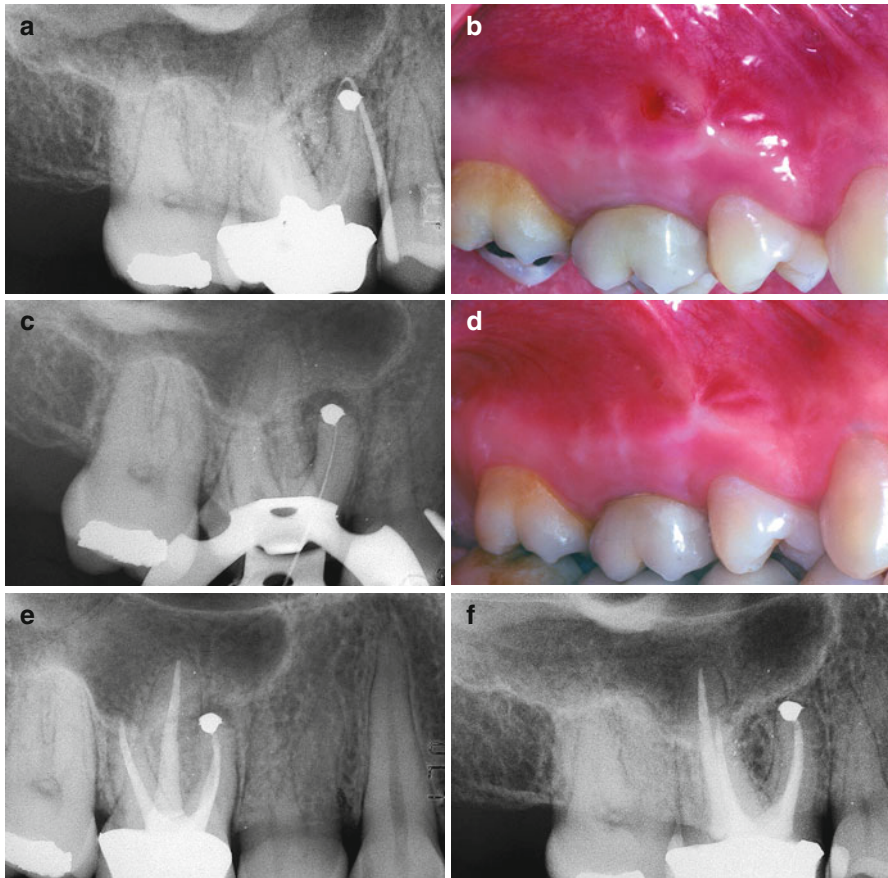


Fig. 9.2 (a) Preoperative film of the maxillary right first molar. The apical surgery has been performed on contaminated and empty root canals. The surgical failure must be retreated nonsurgically. The gutta-percha cone traces the sinus tract. (b) A sinus tract is evident clinically. (c) Working length radiograph of MB1. (d) After cleaning and shaping four canals, the sinus tract disappeared. (e) Postoperative film. (f) Two-year recall

9.2.1 The Rationale for Retreatment

The clinical practice of root canal treatment has changed markedly over the last 20 years. The introduction of rotary instrumentation, of various new obturation systems, of ultrasonically powered devices, and of magnification systems (in particular operating microscopes) has significantly increased the success rate of primary endodontic treatment and endodontic surgery [3, 4].

Perhaps, the most important difference today is that an endodontist's manual dexterity is no longer the prime determinant for success. Obviously, individual skill always makes a difference, but with the use of modern endodontic techniques,

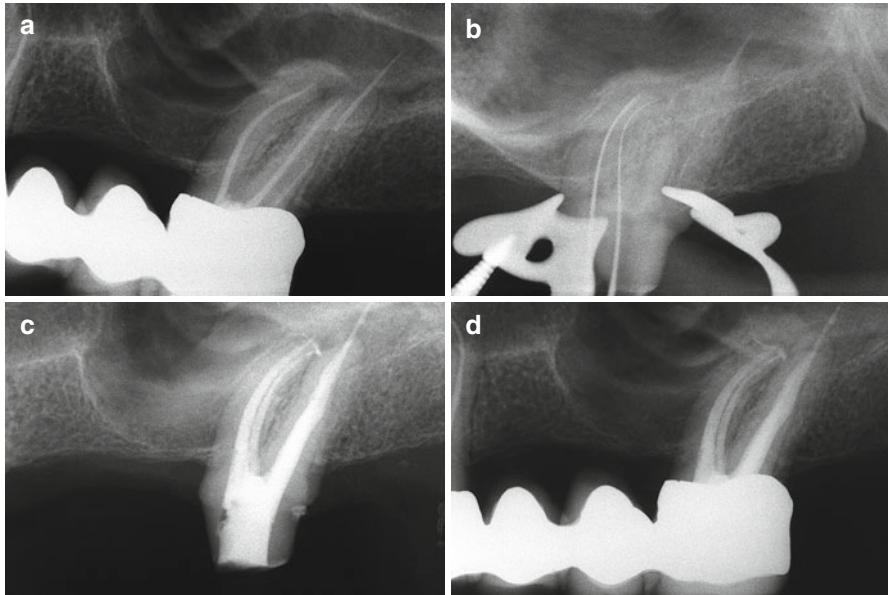


Fig. 9.3 (a) The patient was referred for the retreatment of the palatal canal, thinking that the cause of pain was the overfilling. (b) During the retreatment, a missed MB2 was negotiated and then cleaned and shaped. Immediately after that, the pain disappeared, even though it was not possible to remove the gutta-percha protruding through the foramen of the palatal root. (c) Postoperative film. Note the independent foramen of MB2. (d) Follow-up at 2 years

levels of excellence are seen that were unheard of in the past [5, 6]. Nevertheless, a significant portion of the workload of endodontic specialists continues to be dedicated to redoing failed endodontic treatments.

Implantology can deliver high success rates [7] that might make extraction and replacement by implants seem a valid alternative to endodontic retreatment. However, it should be stressed that the two types of treatment have different goals: endodontic treatment aims to prevent or treat apical periodontitis, whereas implants are used to replace missing teeth [8]. This means that retreatment is the approach of choice for cases with endodontic failure, in which the tooth can be salvaged, both from restorative and periodontal standpoints.

In a recent US epidemiological study by Salehrabi and coworkers on a population of 4744 teeth that had undergone orthograde retreatment by endodontists, the success rate after 5 years was 89% [9]. Earlier, Fristad and coworkers analyzed the success rate in 112 roots retreated by undergraduate students after 10–17 years, and after 20–27 years. The success rate at 10–17 years was 85.7%, but 10 years later this had risen to 95.5%, equaling the success rate found in cases of first treatment [10]. The study authors conclude that the persistence of asymptomatic periapical radiolucencies, especially those with overfill, should generally not be classified as failures, as many of them will heal after an extended observation period. This statement is of

particular interest in increasingly easy access to cone beam computed tomography (CBCT). It has been shown that considerably more (asymptomatic) lesions are detected on CBCT scans rather than on periapical radiographs of endodontically treated teeth [11]. Likewise, in a systematic review, Torabinejad reports that endodontic surgery appears to offer more favorable initial success, whereas nonsurgical retreatment leads to a more favorable long-term outcome [12].

Planning endodontic retreatment requires a correct diagnosis using clinical and radiographic findings (see Chap. 2 in this book). It is necessary to understand the cause or causes that have led to the failure of the prior treatment and determine the feasibility of salvaging the tooth restoratively and periodontally. Prognostic factors of individual cases must be combined with a diagnosis to formulate a correct treatment plan.

The secret of achieving high success rates in retreatment undoubtedly lies in understanding typical causes of failure of the original endodontic treatment and will be discussed in the following section.

9.2.2 Incomplete Treatment of the Root Canal System

A root canal system may be highly complex, especially that of molar teeth (see Chap. 1). In many cases, complete mechanical treatment of such root canal systems is virtually impossible. Two different types of incomplete treatment of the root canal system exist:

1. The working length stops short of the canal end, due to anatomical problems (curvature, bifurcations, etc.), preparation errors, or pathological problems (mineralizations; see Fig. 9.4)
2. Overlooked anatomy (MB2 in maxillary molars, for middle mesial root canal of a mandibular molar, and other variants of molar anatomy, see Fig. 9.5)

9.2.3 Inadequate Root Canal Filling

Historically, it has been held that inadequate apical seal may be a cause of failure in nonsurgical endodontic treatment [13]. It is indeed impossible to remove all the bacteria, toxins, and pulp tissue from the root canal system [14], and therefore tissue fluid (via the apical foramen and other foramina) may reach an incompletely filled canal space so that bacterial contamination persists and apical periodontitis is the consequence. Thus, to achieve long-term success, the root canal system should be filled as completely as possible.

Inadequate seal may occur in four cases:

1. Canal filling in the presence of exudate
2. Canal straightening with transportation of the apical foramen
3. Ineffective filling techniques
4. Filling procedure executed incorrectly

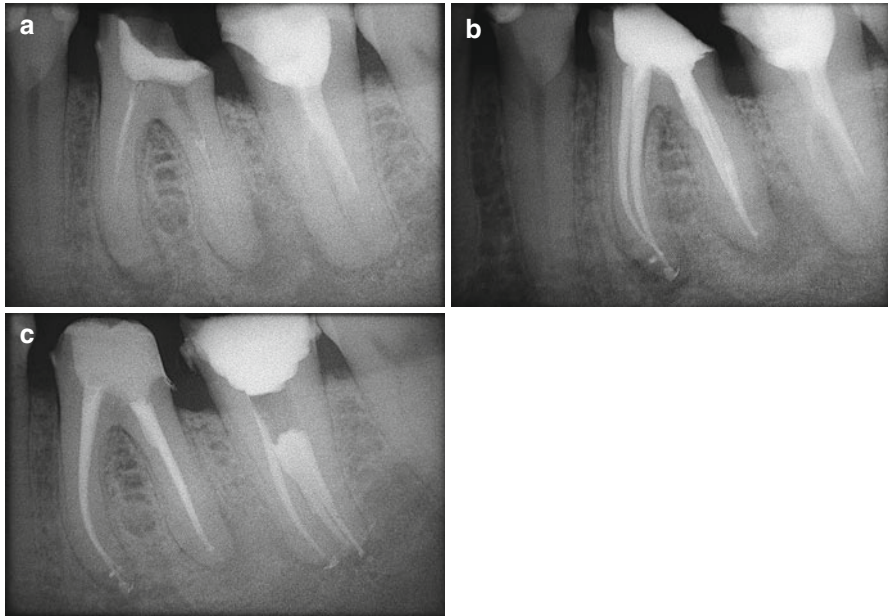


Fig. 9.4 (a) Preoperative radiograph. Left mandibular first molar with insufficient endodontic treatment and apical, mesial, and distal radiolucent areas, indicative of asymptomatic apical periodontitis. (b) Postoperative radiograph. Retreatment. (c) Follow-up at 6 months

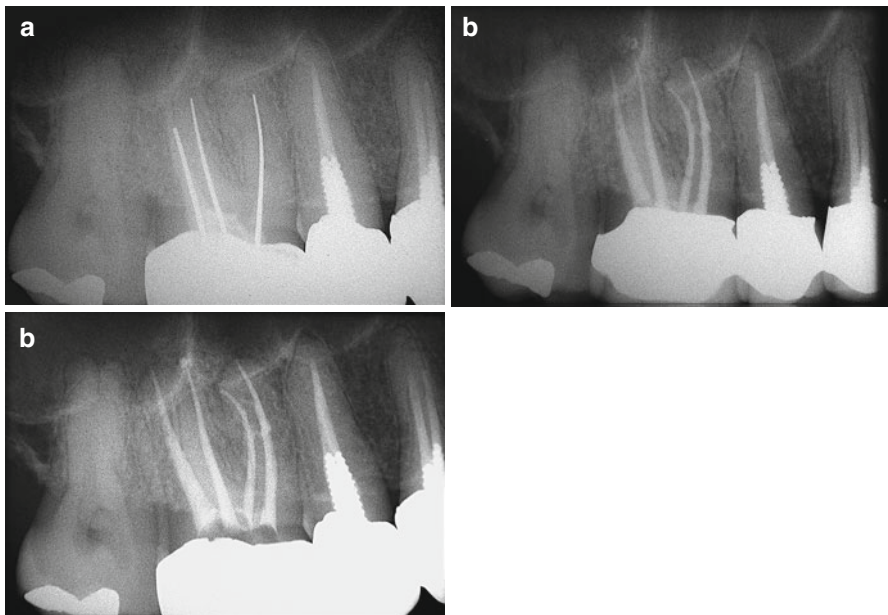


Fig. 9.5 (a) Preoperative radiograph. Right maxillary first molar with insufficient endodontic treatment. (b) Postoperative radiograph after retreatment. The mesiobuccal root has two independent canals: MB1 and MB2. (c) Radiographic follow-up after 6 months

9.2.4 Vertical Fractures

According to clinical studies, vertical root fractures account for approximately 3 % of failures in teeth treated endodontically [15] and for 11 % of failures in fixed prostheses after 18 years [16]; of teeth requiring extraction, up to 32 % displayed vertical root fractures [17]. The extracted, fractured teeth were mostly root canal treated and associated with posts and screws. Diagnosis may be straightforward if the fracture can be identified in the coronal portion of the tooth in question: typically probing reveals a very narrow periodontal pocket along the fracture line (Fig. 9.6).

Conversely, diagnosis is far from simple for a vertical root fracture that starts from the apical portion of the root. In these cases, there is initially no periodontal probing; however, a radiograph may show a radiolucent area along the lateral aspect of the root, or it is visible in a small field of view CBCT. In cases of a confirmed fracture connecting periodontal and pulpal spaces, nonsurgical retreatment is not recommended [18]. Endodontic surgery (see Chap. 10) may confirm or deny root fracture and provide means to improve the apical seal of the root canals (Fig. 9.7).

9.2.5 Loss of Coronal Seal

Loss of coronal seal is a frequent cause of failure some years after endodontic treatment. Magura and coworkers state that canals that have been obturated completely and exposed to the oral environment for 3 months or longer may need retreatment; if the root canal space had been prepared for a post, and if the root canal filling was incomplete, then the time lapse before clinically significant leakage occurs could be shorter [19].

In generating a treatment plan, the endodontist must next analyze the prognostic factors that may influence the treatment plan (Box 9.1).

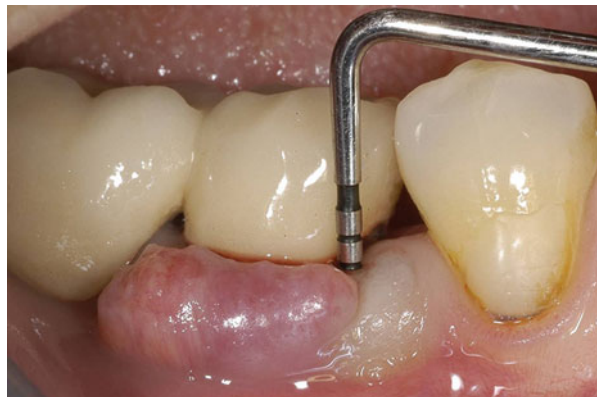

Fig. 9.6 Right mandibular first molar with vertical fracture of the mesial root. Very narrow periodontal probing is present at the fracture

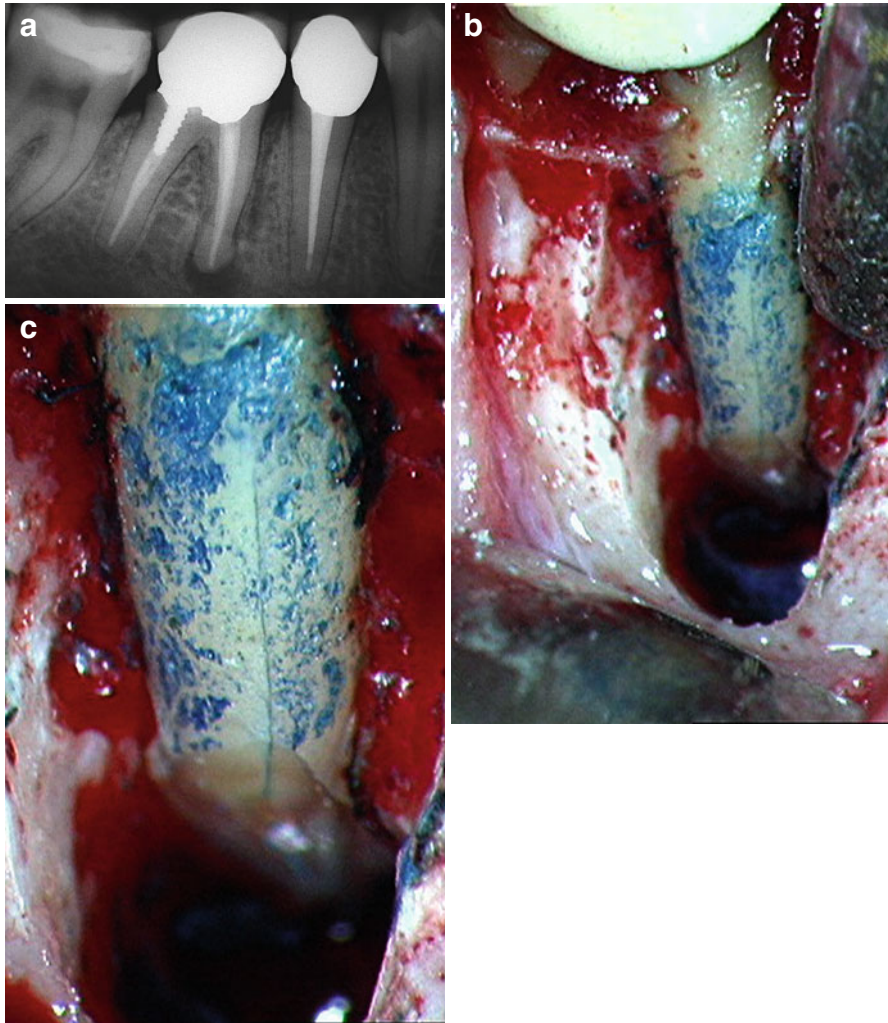


Fig. 9.7 (a) Preoperative radiograph. Right mandibular molar responsible for repeated abscesses. Note the good quality of the endodontic therapy and the radiolucent area surrounding the mesial root. Periodontal probing is noncontributory. Suspected vertical fracture starting from the apex suggests surgery is the best option. (b) View of surgical field. Note the loss of buccal bone in the mesial root area. The root was stained with methylene blue. Clearly visible fracture line originating apically and extending to the boundary between the medial and the coronal thirds of the root. (c) Enlarged view of surgical field

9.2.6 Unclear Cause of Failure

To undertake retreatment without having clearly understood the causes responsible for failure of the original treatment is a serious mistake. While persisting or newly introduced microorganisms are the main cause of apical periodontitis [20], it is

Box 9.1. Prognostic Factors in Retreatment Decision-Making

- Specific cause of failure
- Presence of periradicular radiolucency
- Satisfactory quality of prior treatment
- Altered root canal morphology
- Periodontal involvement
- Suspected vertical fracture
- Lack of coronal seal
- Endodontist's experience
- Availability of technologies (operative microscope, ultrasound, etc.)
- Patient's expectations

impossible to improve a situation without knowing where it went wrong in the technical aspects of treatment [21]. In difficult situations, it is not uncommon to think of the most complex and unusual causes (unsealed lateral canals, extra canals, etc.) and fail to see the obvious. The four causes of failure are listed above, and the specific cause or causes responsible for failure in individual cases must be determined. Naturally, an endodontist must have an in-depth knowledge of root canal anatomy for each molar, including possible anatomic variables, and he or she must perform a complete and in-depth clinical and radiographic assessment (see Chaps. 1 and 2 in this book).

9.2.7 Presence of a Periradicular Radiolucency

As with primary endodontic treatment, the presence of a preoperatively detected periradicular radiolucency in retreatment cases markedly reduces the success rate [21, 22]. In a critical review of literature published between 1970 and 2004 that sought to explore the level of evidence relating to the outcome of endodontic retreatment, Paik and coworkers [23] found that all included studies agreed in that the success rate was inferior in the presence of a periradicular lesion prior to retreatment; they also found that this difference varied greatly:

- Presence of preoperative periradicular lesion – success rate ranged from 97 to 40 %
- Absence of preoperative periradicular lesion – success rate ranged from 100 to 84.4 %

9.2.8 Satisfactory Quality of Previous Treatment

This prognostic factor is certainly one of the most problematic one. When dealing with the endodontic failure of a molar that has been treated satisfactorily from the

endodontic standpoint (correct working length, appropriate shape, density of filling material), the most common error is to embark upon retreatment in the hope of improving the quality without taking into account that a possible cause may be a vertical fracture as discussed before. Chevigny and coworkers report an 88 % success rate for retreatment in cases where prior treatment was unsatisfactory, but only 66 % where prior treatment was adequate [22].

9.2.9 Altered Root Canal Morphology

The presence of ledges, perforations, false pathways, stripping, internal or external transportation of the foramen, mineralizations, broken instruments, apical resorption, or internal resorption are all factors that complicate retreatment and may jeopardize its success (Fig. 9.8). In a study on 452 teeth retreated after 2 years, Gorni and coworkers [21] found a significant difference in terms of success rate in cases in which the root canal morphology was altered, and in the presence of a periradicular lesion: they report 84.4 % success in the absence of iatrogenic alterations versus only 40 % in the presence of alterations of the root canal system.

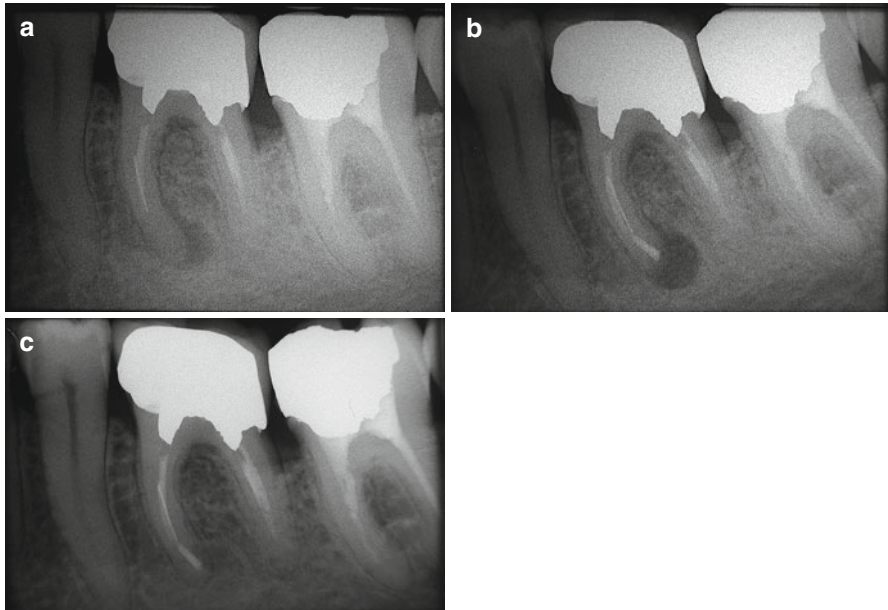


Fig. 9.8 (a) Preoperative radiograph. Left mandibular first molar with insufficient endodontic treatment and apical radiolucency at the level of the mesial root. Note the presence of a fragment of broken endodontic instrument in the middle third of one mesial root canal. Owing to the position of the broken instrument and the root anatomy, surgery is without doubt the least invasive treatment option. (b) Postoperative radiograph. (c) Radiographic follow-up at 6 months

9.2.10 Periodontal Involvement

It is important to distinguish between two different periodontal problems. One is primary: the patient is affected by periodontal disease of some degree of severity; he or she has numerous affected sites, and one of these is the molar scheduled for retreatment. As was already seen, in this case, a careful periodontal evaluation is necessary to evaluate whether the tooth can be salvaged, or whether it would be better to extract it and place an implant. The second eventuality is that in which there is a primary endodontic lesion with secondary periodontal issues, often as a consequence of iatrogenic damage (perforation, stripping, etc.; see Fig. 9.9). In these cases, the success rate is significantly reduced [24].

9.2.11 Suspected Vertical Fracture

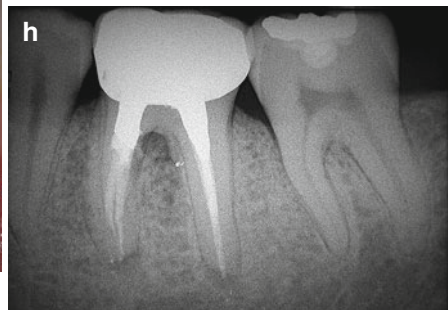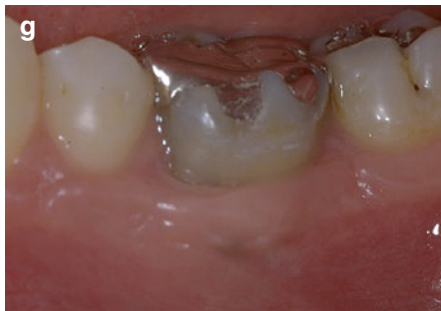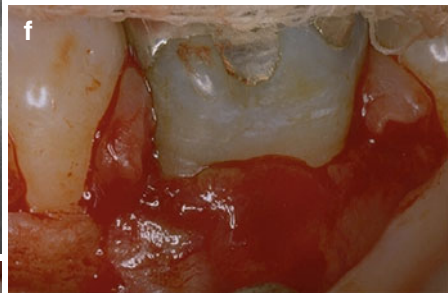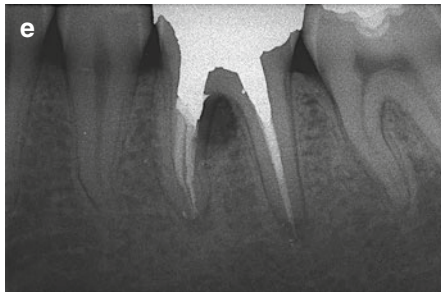
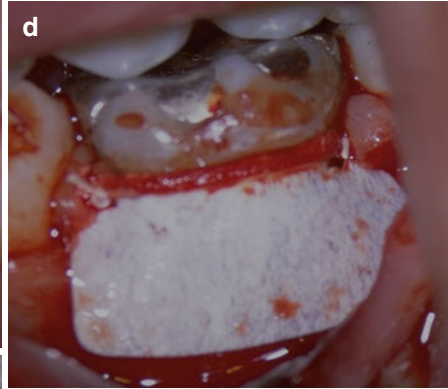
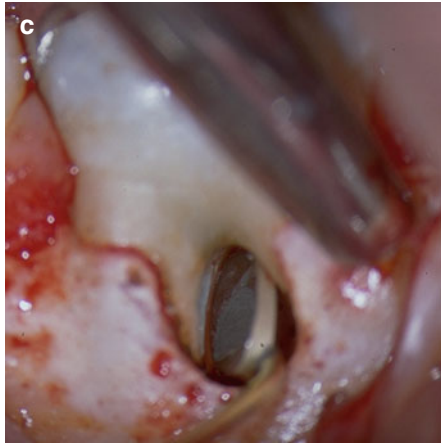
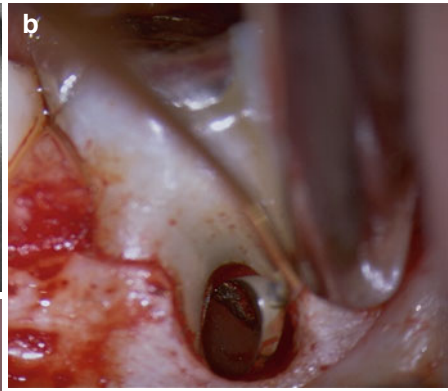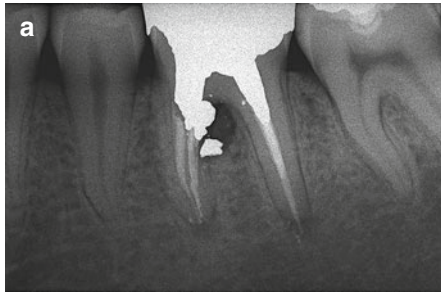
As stated above, an evaluation of epithelial attachment must be made, even before radiography. Narrow probing reaching the apical third is very probably the consequence of a vertical root fracture. The presence of a single periodontal pocket, possibly in the furcation of a molar retreatment tooth, casts serious doubt on the possibility of salvaging the tooth for a long term. Another sign that points toward a vertical fracture is the presence of sinus tracts in unusual locations, for example, closer to the marginal gingival or on both the buccal and lingual aspects [25].

9.2.12 Lack of Coronal Seal

Lack of coronal seal at the time of retreatment undoubtedly complicates the already complex RCS infection. Kwang and Abbott [26] state that “The restoration-tooth interface is a potential pathway for bacteria to enter teeth and infect the root canal systems.” Complete removal of an existing restoration insertion of a leakage-proof temporary buildup is often the only way to ascertain that no new infection will occur during endodontic retreatment. Infection in retreatment cases may or may not be more difficult to eradicate, because it is sustained by streptococci, enterococci (e.g., *Enterococcus faecalis*) and yeasts [20, 27] existing in a biofilm, enabling them to



Fig. 9.9 (a) Preoperative radiograph. Left mandibular first molar with stripping at the level of the mesial root; repair has been attempted with amalgam. There is now an endo-perio lesion with wide buccal periodontal probing. (b) View of the surgical field. The amalgam obturation may be seen in the micro-mirror inserted into the furcation. (c) View of the surgical field. Repair of the perforation with Super EBA (Bosworth). (d) View of the surgical field. A Gore-Tex membrane is placed at the level of the periodontal lesion of the furcation. (e) Postoperative radiograph. (f) View of the surgical field, reopened after 4 weeks. Note the new-formed tissue. (g) Clinical checkup after 6 months. Note the healthy periodontal tissues. (h) Radiographic follow-up at 10 years



develop effective protection against disinfectants [27, 28]. More recently, however, evidence has emerged that the microbial flora at the apicalmost portion of the root canal is similar in retreatment cases and initial treatment; this suggests that the inability to disinfect all canal space rather than specific microorganisms plays a role in failing endodontic treatment [29].

9.2.13 The Importance of Professional Experience

Because retreatment procedures frequently involve thinned root walls and altered anatomy, the endodontist's level of experience is important, both in the initial phases of evaluating the case and formulating the treatment plan, and in the subsequent technical phases of executing the endodontic retreatment [30]. An experienced endodontist will be able to remember 15–20 other cases similar to the one being tackled, the difficulties encountered, how they were overcome, the end result, and the long-term outcome. A beginner in the specialty has the advantage of open-mindedness, but will require additional time to prepare to avoid irreparable damage of compromised teeth. Chapter 8 of this book provides a detailed discussion of decision-making in endodontics.

9.2.14 Available Technology

Whether in nonsurgical or surgical retreatment, both the operating microscope and ultrasonic tips are irreplaceable devices that can make a difference, significantly raising the treatment's success rate. Setzer reported a success rate at 1 year of 88% in surgical endodontic treatments performed with modern techniques, but without the help of enlargement, or only with magnifying loupes. The success rate rose to 94% if surgery was performed under the operating microscope [31].

9.2.15 Patient Expectations

It is very important to have a consultation appointment with the patient, during which the endodontist illustrates costs and benefits together with any mishaps that could occur during treatment. The various phases of the procedure should be briefly explained and an estimate of costs given. The endodontist is under the obligation to list any alternative treatments, pointing out their advantages and disadvantages. It is imperative to understand the value of the tooth for the patient. A patient must never be urged into a decision: he or she must be sure that retreatment is the right choice and a good economic investment. To undertake retreatment in a nonmotivated patient is very stressful for the endodontist, and in consequence, it will be difficult to achieve a satisfactory outcome.

9.2.16 Nonsurgical Versus Surgical Retreatment

Nonsurgical retreatment is in principle considered the treatment of first choice, in particular, if this better addresses the cause of the treatment failure. Only when attempted nonsurgical retreatment is not feasible or was performed with no satisfactory result, should one select surgical treatment (see Chap. 10 in this book).

The clinical strategy in root canal treatment is to shape, clean, and fill the root canal system. Thus, it seems reasonable to assume that when nonsurgical retreatment addresses the entire canal space, cleaning it and densely filling it, success rates comparable to those possible with the primary endodontic treatment may be achieved. Studies point out better outcomes of surgical retreatment if it is preceded by nonsurgical retreatment that disinfects and seals the canal system successfully [32].

With this premise in mind, there are some cases in which surgical retreatment is indicated as first choice:

- Presence of an obstacle that hinders complete treatment of the root canal space
- Failure of an apparently well done endodontic treatment
- Perforation in the apical third
- Diagnosis of a suspected vertical fracture
- Presence of recent, adequate prosthetic restoration
- Less invasive compared to removal of restorations or posts

We may conclude that retreatment is indicated when there is a periradicular lesion that developed after the first endodontic treatment, when the lesion is enlarged or appears unchanged for more than 4 years, when the tooth is symptomatic, when the coronal seal has been lost for longer than 3 months, and when prosthetic restoration is necessary in the presence of an inadequate endodontic treatment, even without periradicular lesions and/or symptoms.

9.3 Clinical Practice of Root Canal Retreatment

9.3.1 Removal of Filling Material

The methods applied during nonsurgical retreatment vary according to the type of filling material to be removed or the obstacle to be overcome.

The degree of difficulty also varies, depending on whether the preceding obturation was performed with paste, sealer, gutta-percha, carrier-based obturators, or silver points, whether ledges were created in the root canal, whether an instrument had fractured, and whether preparation errors exist.

A preoperative radiograph can provide much useful information in this respect, but for molar retreatment, a cone beam CT (CBCT) scan should be obtained [33]. On the other hand, certainty about the nature of the material, its consistency, its ease of removal, as well as the presence of ledges and the likelihood of bypassing a

broken instrument cannot be assessed by radiographic means alone, but can only be tested clinically, that is, by accessing the root canal space.

9.3.2 Pastes

The removal of root canal filling paste is in general easy, since, by definition, pastes do not set completely within the root canal; they can therefore be penetrated and removed by hand endodontic instruments and irrigating solutions. The most widely used paste is perhaps iodoform paste, which typically shows intense radiopacity and scattered areas of resorption.

9.3.3 Sealers

The removal of sealer is often also relatively simple; sometimes, however, it can be extremely complicated. Zinc oxide-eugenol sealers are dissolved by orange solvent [34] which is used as an irrigating solution, flooding the pulp chamber of the tooth in question. After creating the access cavity, an endodontic explorer is introduced into the orifice of the root canal to allow a deeper penetration of the solvent. After this, K-type endodontic instruments (e.g., .08 C+File, Dentsply Maillefer, Ballaigues, Switzerland) are introduced to probe apically with delicate movements. Special attention must be paid to not forcing the dissolved sealer beyond the apex and irritate periapical tissues. To prevent this, sealer should be removed as much as possible before taking instruments to the radiographic terminus of the canal and checking the working length.

If a sealer cannot be dissolved by orange or eucalyptic oil (whitish colored sealer, oftentimes used in Russia, and the reddish-brown resin paste, commonly utilized in Eastern Europe and the Pacific Rim), the coronal portion can be removed using ultrasonic instruments in conjunction with a microscope [35–37].

Once the preexisting sealer is eliminated and the canal has been negotiated to full length, the case can be completed using traditional methods (Fig. 9.10).

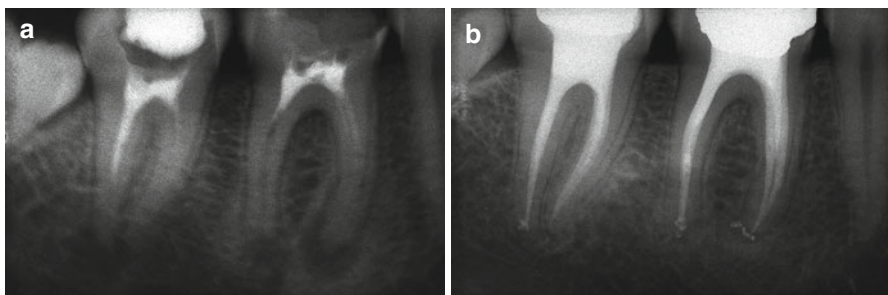


Fig. 9.10 (a) Preoperative radiograph. The first and second lower molars were treated using just sealer as a root-filling material. (b) Two years follow-up

9.3.4 Silver Point Removal

A silver point that conforms closely to the canal walls can be difficult to take out; in contrast, a point that fits loosely in a canal does not present great problems, especially if it extends into the pulp chamber. If zinc oxide-eugenol sealer, zinc phosphate cement, or composite were used to cover the coronal portion of the silver point within the pulp chamber, they can be removed with ultrasonics.

Once the coronal end of the cone is freed of surrounding materials, it can be grasped with hemostatic forceps (Stieglitz Forceps, Hu-Friedy; Chicago, IL, USA) and extracted from the root canal. If the pulp chamber was filled with amalgam, the silver point cannot be distinguished from the surrounding metal, and the cone will inevitably be sectioned at the orifice of the root canal unless one is able to dislodge the amalgam and remove it in one single piece. If one succeeds in doing so, the silver points will also be removed from the root canals [38]. Obviously, cutting the silver point seriously complicates the removal of the point itself and makes subsequent retrieval efforts difficult, if not impossible.

Dislodging a silver cone can be facilitated by the use of solvents to soften surrounding sealer or by ultrasonics [39, 40]. The latter is particularly effective in dislodging and removing silver cones after hand instruments have created paths alongside the points [38–41]. Ultrasonics has also been shown to be effective in removing fragments of silver cones when they break off within the canal as a consequence of corrosion [42]. Ultrasonics may be used indirectly, transmitting ultrasonic energy on grasping pliers to synergistically enhance the retrieval efforts. This form of “*indirect*” ultrasonics advantageously transfers energy along the silver point, breaks up material deep within the canal, and enhances removal efforts [42].

Some authors suggest several microtube removal methods, for example, Lasso & Anchor [43], the Cancellier Extractor kit (Sybron Endo; Orange, CA, USA) [2, 43], the Instrument Removal System (iRS) (Dentsply Maillefer) [43], the use of an injection needle with a wire loop at the end [44], and the use of specific instruments such as Masserann kit (Micromega; Besançon, France) [45] the Endo Extractor System kit (Roydent; Rochester Hills, MI, USA) [46] the Post Removal System kit (SybronEndo) [46]. However, the rigidity and size of the listed devices limit the use of these instruments to relatively wide and straight roots; any intracanal work with these tools requires the use of high magnifications, ideally an operating microscope. They cannot be safely used in the apical portions of curved roots.

9.3.5 Bypassing Ledges

One of the most frequent complications that can occur during root canal shaping is straightening the curvature of a canal, without communication with the periodontium; this is known as a ledge. The usual cause of ledges is using an incorrect, shorter working length. The canal is immediately blocked, due both to the accumulation of debris and the ledge that is formed. If the endodontist then applies force to

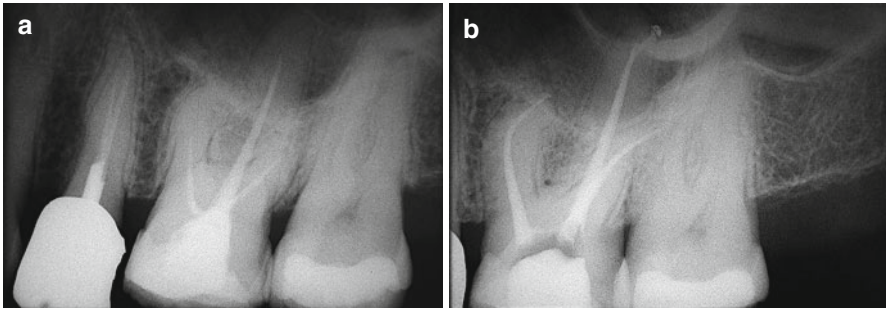


Fig. 9.11 (a) Left maxillary first molar. Endodontic treatment is insufficient and the patient complains of slight pain on mastication. (b) Postoperative radiograph showing retreatment. Note the palatal perforation in correspondence to the apical ledge

the instruments in an attempt to bypass the blockage, he or she may create a “false canal,” tangential to the original pathway (Fig. 9.11). The result of ledge formation is that it becomes impossible to shape, cleanse, and fill the entire root canal; this frequently leads to treatment failure [47, 48].

9.3.6 Etiology

The main causes leading to ledge formation are as follows:

- Wrong working length, shorter than the correct one
- Interferences in the access cavity that hinder straight access to the apical third and cause loss of instrument control
- Aggressive canal instrumentation, specifically with instruments with cutting tips
- Using stainless steel instruments that are not precurved or that are of larger diameter and thus too rigid
- Failing to use instruments in the correct sequence of increasing size
- Inadequate use of irrigants
- Using rotary NiTi instruments without an adequate glide path
- During retreatment, when removing previous canal obturation
- When removing broken instruments
- While shaping canals with complex anatomy (curvature, bifurcation, etc.), or when working in calcified canals [49]

9.3.7 Endodontic Management

Relocating and renegotiating the original canal may be very complex, even for an expert endodontist. When the canal is, or is suspected of being, blocked by a ledge, the treatment plan entails:

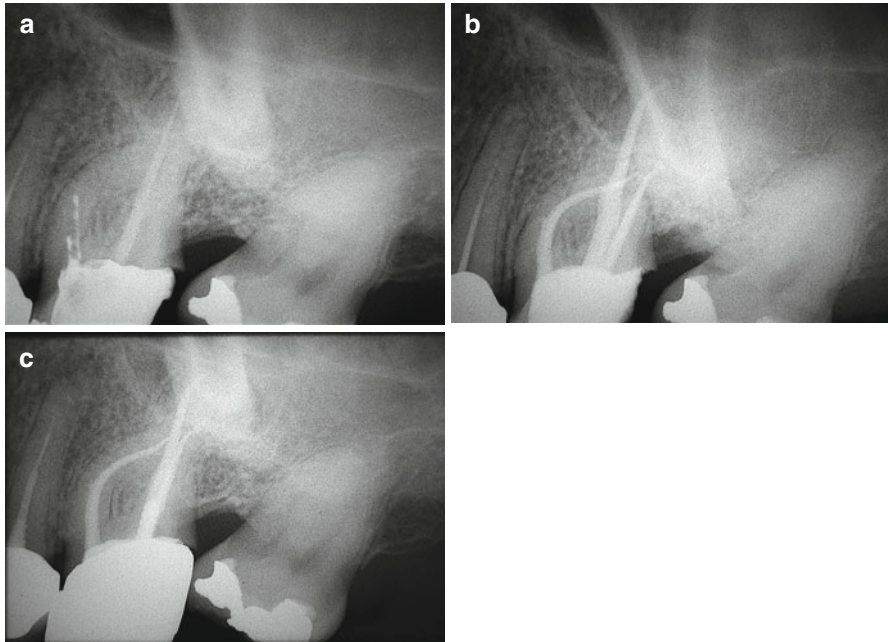


Fig. 9.12 (a) Left maxillary first molar. Endodontic treatment is insufficient. There is a wide ledge corresponding to the MB1 canal at the boundary between the coronal and the middle thirds. (b) Postoperative radiograph showing retreatment. (c) Follow-up after 6 months

- Locating the ledge
- Bypassing the ledge
- Eliminating the ledge

Locating the Ledge

When retreating a canal, if the preoperative radiograph shows that the old canal filling stops before a curve, that it does not follow the natural canal anatomy, or that it stops short compared to the radiographically visible outline of the root, then the existence of a ledge should be suspected (Fig. 9.12).

Bypassing the Ledge

An indispensable requisite for bypassing a ledge is to know where that ledge is. The ledge will always be located at a curve, on the outer surface of the canal. The instrument that creates the ledge is usually a rigid stainless steel instrument of large size (#25, 30) that, even if precurved, tends to straighten and thus to transport the canal externally to the curve. The endodontist must therefore have an in-depth knowledge of the endodontic anatomy of the tooth to be retreated. It is necessary to imagine the canal curvature in all three dimensions. Thinking in 3D means, for example, looking at the preoperative radiograph of the molar and imagining that the mesial canal,

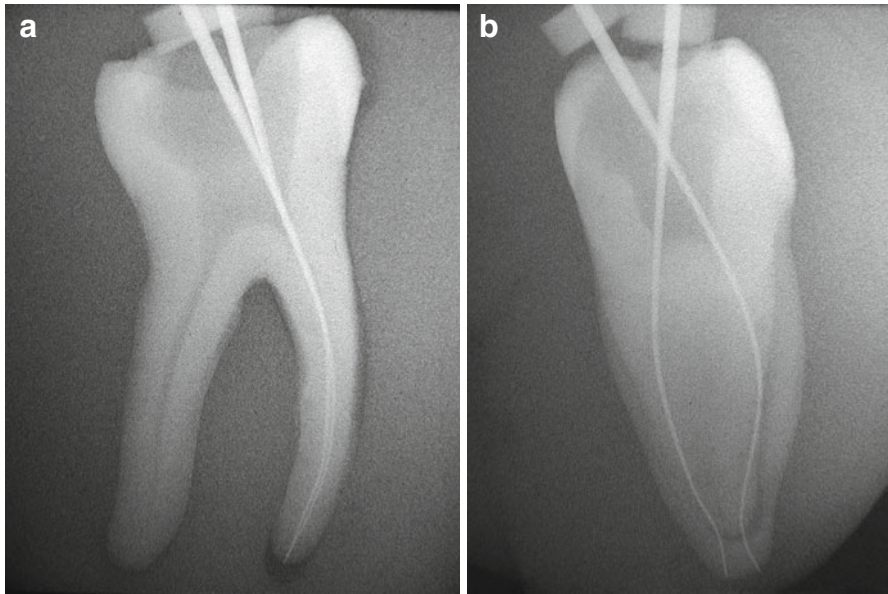


Fig. 9.13 (a) Radiograph in buccolingual projection. The file inserted into the MB and ML canals points up the buccal curvature of the canals, the only curvatures visible through radiography on the patient. (b) Radiograph in proximal projection. The file inserted into the MB and ML canals points toward the proximal curvatures of the canals, which are impossible to visualize through radiography on the patient

where a ledge is suspected, not only possesses the curvature we can see on the radiograph, in the buccolingual projection, but that it also has a curvature that would be visible in a hypothetical film taken with proximal projection. The canal does not actually have two curves: it has one curvature that runs three-dimensionally in space (Fig. 9.13).

Through the radiograph, we can break this curvature down into two images: the buccolingual projection, and a proximal projection that, naturally, we can only imagine. A ledge in the mesial canal of a mandibular molar will be the result of two actions: straightening the curvature in the buccolingual projection (the instrument transports the canal mesially) and straightening the curvature in the proximal projection (the instrument transports the MB canal buccally and the ML canal lingually). If we sum the two vectors given by the forces acting on the external surfaces of the curves, we obtain a vector, which will reveal the position of the ledge. In an MB canal, the ledge is always mesiobuccal; in an ML canal, the ledge is always mesiolingual. Naturally, the canal entrance will be precisely opposite the ledge (Fig. 9.14).

The most suitable instruments to bypass the ledge are small hand files (such as a #10 or 15 file). The last 3 or 4 mm of the file tip must be precurved, gently but sharply, at about 90°, and the tear of the rubber stop must be positioned toward the instrument tip; this will show where the instrument tip is pointing when it is inside

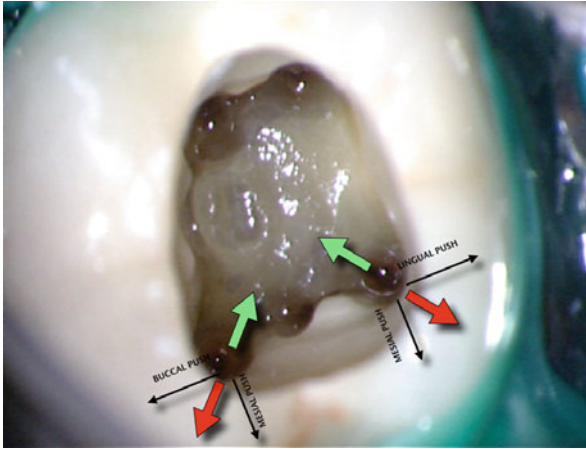



Fig. 9.14 Pulp chamber of mandibular first molar. The *black arrows* indicate the thrust of the endodontic instrument, in the buccal, and in the proximal directions, respectively, when straightening the buccal and proximal curves. The resultant of these two forces is the red vector, which indicates the direction of the ledge. Conversely, the opposing green vector shows the direction where the entrance to the original canal is situated

Fig. 9.15 The final 3–4 mm of the tip of the file used to bypass the ledge must be precurved to about 90° , and the indicator of the rubber stop must be positioned in the direction of the instrument tip. This will make it possible to know where the instrument tip is located when it is inside the canal, and to guide it toward the canal entrance



the canal (Fig. 9.15). The precurved tip of the file must be pointed from the side opposite the ledge, and the instrument introduced into the canal. Once the depth corresponding to the position of the ledge has been reached, the file is rotated gently to explore an area of some 60° on the side opposite the ledge. The file must be gently pushed against the canal walls in order to bypass any blockage (debris, filling material).

After one or two attempts, the file should be extracted and again precurved. It is very useful to pre-enlarge the canal up to about 1–1.5 mm from the ledge, to enable the file to maintain its prebending as it approaches the ledge. If after several attempts the ledge cannot be bypassed, then a false pathway may be present, and thus the

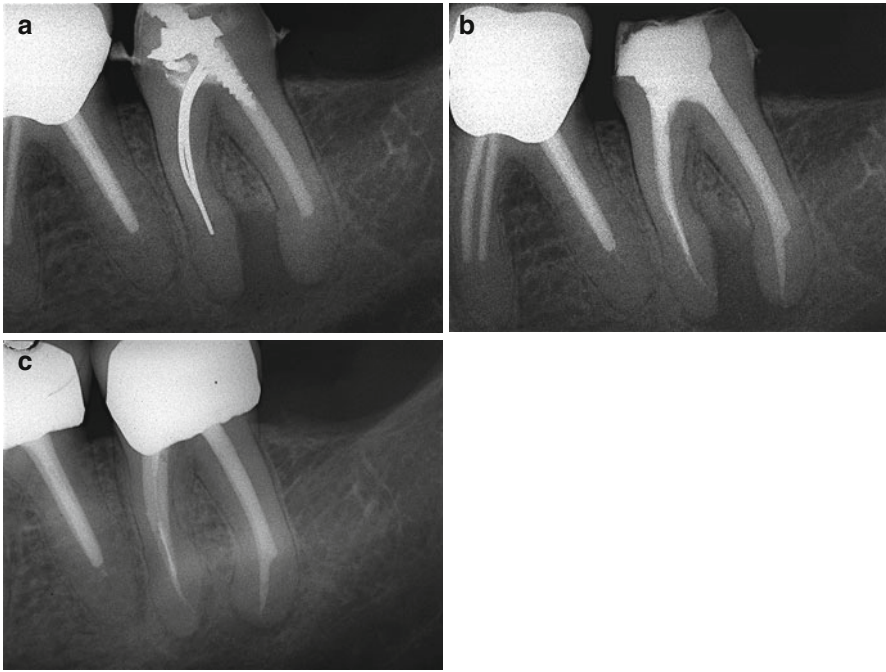


Fig. 9.16 (a) Left mandibular second molar with insufficient endodontic treatment. The distal canal has been substantially enlarged, and a wide ledge is present. (b) Postoperative radiograph showing retreatment. Note the wide ledge present in the distal root. (c) Follow-up after 1 year

canal entrance may have been transported onto the wall of the false pathway. The same probing technique should be used, but at 0.5, 1.0, and 1.5 mm shorter than the end of the old canal preparation.

From the operative standpoint, it is important to remember that the wider the ledge is, the more difficult it will be to bypass it (Fig. 9.16). A ledge in a mesial canal of a mandibular molar created with a file #20 or 25 may easily be bypassed, whereas if the ledge was created with a file #40 or 50, it will become a problem. In this case, the precurved tip of the file will have to explore an extensive area, and it is more likely that a false pathway or a canal blockage is present.

The C+Files (Dentsply Maillefer) have proven to be very useful; these were originally designed for canal location and initial exploration. They are more rigid than stainless steel K-files, and thus they maintain their precurved tip better, meaning that they can be used for longer before they must be extracted and again pre-curved. Their rigidity transmits to the endodontist a significantly better tactile feel. This is important, for example, when after locating the canal entrance the C+File must be gently pushed to bypass a debris plug.

Eliminating the Ledge

Once the ledge has been bypassed with the first file, generally a #10, it is necessary to reach the apical foramen, with the help of an apex locator, and confirm the

working length with a radiograph. Subsequently, files #15 and 20 may be taken to the working length (always precurved). In the more complex cases, it may be helpful to use K-FlexoFile Golden Medium (Dentsply Maillefer); these are available in ISO diameters 12, 17, 22, 27, 32, and 37. The 12 K-FlexoFile Golden Medium may be used to bridge the gap between files #10 and 15, and the 17 K-FlexoFile Golden Mediums to bridge the gap between files #15 and 20.

Once the working length has been reached, the instrument is retracted by a few millimeters, while leaving it beyond the ledge. It is moved with gentle both push-and-pull movements and reaming, so as to begin reducing the width of the ledge. It is important to apply constant irrigation, frequently recapitulating with small files (#10) to remove debris and confirm the glide path. The following instruments, files #25, 30, 35, and 40, are precurved, taken beyond the ledge, and then extracted rotating clockwise. This motion tends to straighten the apical third of stainless steel files and allows them to rasp, reduce, smooth, or eliminate the ledge [49]. If, using the technique described, the ledge cannot be eliminated, then increased-taper manual NiTi instruments such as the ProTaper series (Dentsply Maillefer), appropriately precurved, may be used. The technique entails prebending the last 3–4 mm of ProTaper S1, S2, and F1 files to bypass the ledge, and using the balanced forces technique to move the instrument forward in the canal. The increased taper of the ProTaper will rapidly eliminate the ledge. In order to employ this technique, the canal must be adequately enlarged, coronally to the ledge, so that the ProTaper files do not touch the canal walls except after bypassing the ledge. The endodontist must always be in control of the instrument, since only in this case can the ProTaper file be easily guided beyond the ledge. To prebend the ProTaper file, either Endo Bender Pliers (Analytic Endodontics, Orange, CA, USA) or Bird Beak orthodontic pliers (Hu-Friedy; Chicago, IL, USA) may be used [46].

The above techniques to eliminate the ledge can only be performed when the ledge is not too close to the apical foramen (3–4 mm). If these movements are used in proximity of the foramen, there is a high risk of errors, such as external transportation of the apex. In these cases, it may be better to stop 1 mm shorter than the ledge with rotary NiTi shaping, and to link in the apical 1–2 mm using precurved manual files. Particular care must be paid to irrigation, which can be enhanced using special devices that push the irrigant to the working length (see Chap. 6 in this book).

9.3.8 Instrument Fragment Removal

Fracture of an endodontic instrument is inconvenient and mortifying, as Louis Grossman noted more than 40 years ago [50]. However, we should not forget Grossman also said that such accidents happen in Endodontics, and if it has never occurred, the clinician in question has not treated many root canals. Thus, if an instrument breaks in a canal or if we must retreat a canal in which a broken instrument has been left, we must use professional skill to achieve a successful outcome of the therapy.

The problems raised by retreatment of a root canal where an instrument fragment has been retained are very similar to those arising from ledges. The goal of re-intervention is to clean, shape, and obturate the portion of root canal apical to the broken instrument. If, during these procedures, the fragment is removed, so much the better, but it must be clear to the dentist and to the patient that the prognosis depends not on the removal of the “foreign body,” but on the possibility to clean, shape, and obturate the portion of root canal apical to the broken instrument and to obtain a good apical seal. Therefore, the treatment can be successful either removing the fragment or just bypassing it (Fig. 9.17).

The first factor influencing the prognosis of the removal is the location of the fragment: the more apical its location, the more complicated the removal of the fragment. If the fragment is at the level of the foramen, protrudes beyond the apex, or is in a perforation, surgical intervention is generally indicated. If, instead, the instrument had fractured in the middle or coronal one-third, the chance of bypassing and possibly removing it increases significantly.

The instruments that most often fracture within the canal are rotary NiTi Files, but we may also find reamers, K-files, Hedström files, lentulo spirals, barbed broaches, and Gates Glidden drills.

In most cases, fracture is caused by excessive engagement of the instrument in the canal and simultaneous rotation. These fractures are commonly described as torsional. Another type of fracture occurs when the instrument has been used for an extended period of time and the metal shows signs of wear. This second type of fracture is referred to as fatigue fractures. However, most fractures show a combination of both scenarios.

Through the years, many different approaches have been suggested for managing broken instruments removal. Today, separated instruments can frequently be removed thanks to the use of the operating microscope, powerful ultrasonic units and tips, and microtube delivery methods [43].

The removal is influenced by additional factors, such as the diameter and length of the fragment. Safe retrieval also depends on the anatomy of the root canal, including its diameter, length, and curvature, and it is limited by root morphology, including dimension and thickness of dentin and depth of external concavity.

A broken instrument can be removed if 1/3 of its length can be exposed, if the fragment lays in the straightway portion of the root canal, if the position only partially involves a curvature, and if a safe access to the most coronal extent can be obtained.

The broken instrument cannot be removed if it is apical to the canal curvature or if a nondestructive access to the fragment cannot be accomplished. In such cases, in the presence of signs or symptoms, surgery or an extraction will be required.

The type of material and alloy will also influence successful removal. Usually, stainless steel files are easier to remove, since in general they do not fracture further during the removal attempt. On the other hand, nickel titanium files sometimes break repeatedly during the use of ultrasonic tips, maybe because of heat buildup [2].

The first step in the removal of a broken instrument is to obtain a good coronal access, to obtain straight-line access to all canal orifices. The second step is to obtain

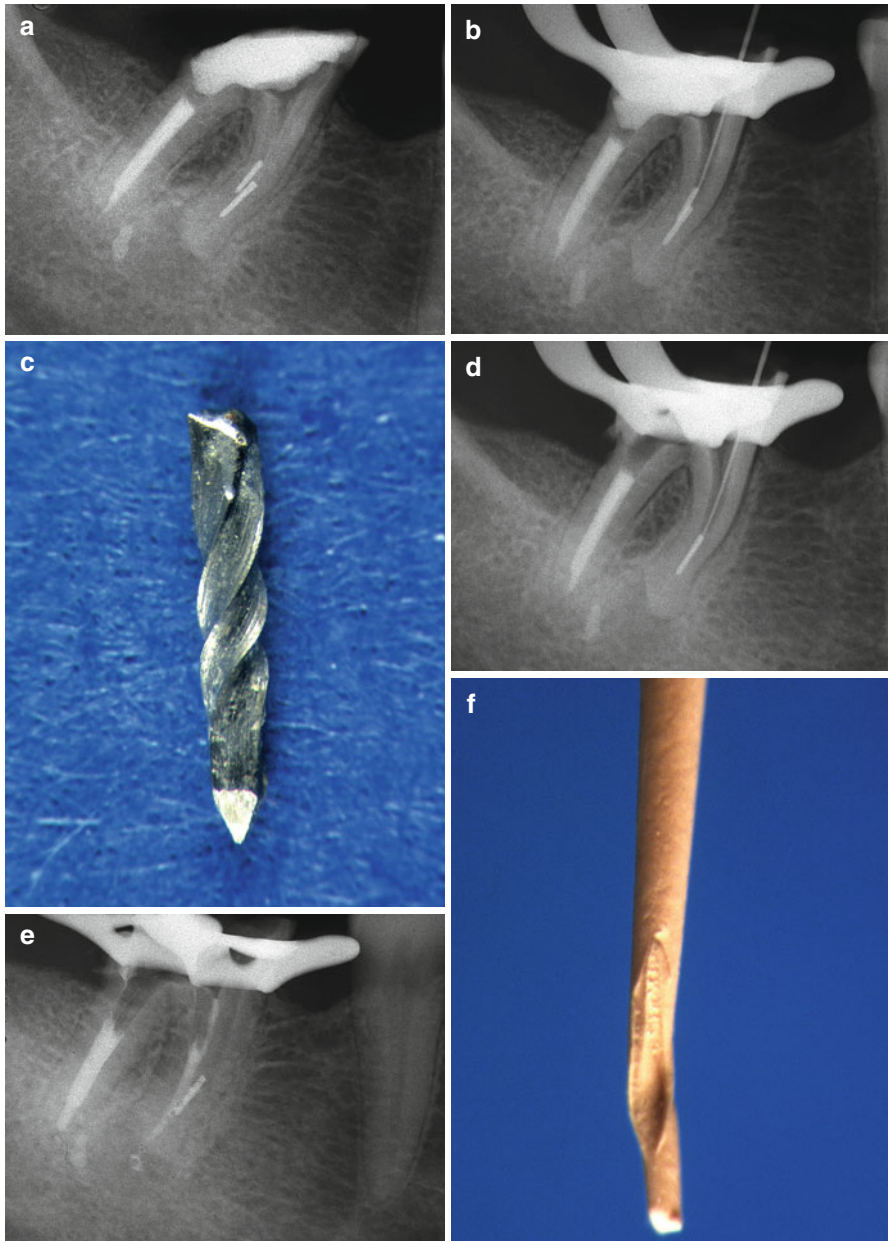


Fig. 9.17 (a) Two broken instruments are present in the mesial root of this lower second molar. (b) A #10 K file is bypassing the broken instrument in the mesiolingual canal. (c) Just enlarging the canal around, the fragment has been removed from the mesiolingual canal. (d) A #10 K file is now bypassing the broken instrument in the mesiobuccal canal. (e) A gutta-percha point has been inserted in the mesiolingual, and then the K-file has been introduced in the mesiobuccal, to detect if the canals are joining together: the impression left on the gutta-percha from the file is confirming that the two canals have a common foramen; therefore, it is useless trying to remove the second fragment from the mesiobuccal canal. (f) The gutta-percha is condensed in the mesiolingual canal and now is in contact with the broken instrument in the other canal. (g) Postoperative radiograph. (h) 2-year recall

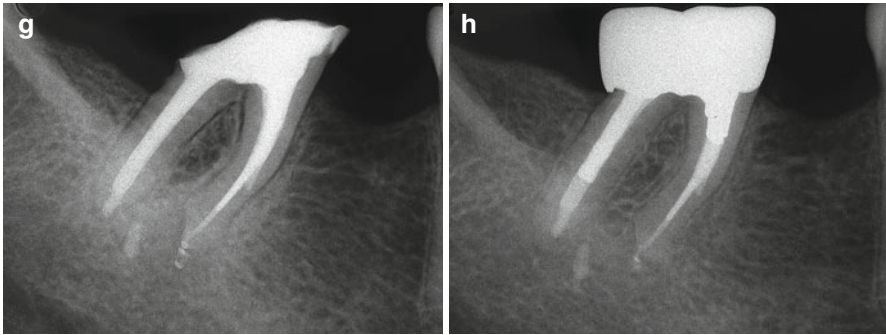


Fig. 9.17 (continued)

straight-line radicular access, to obtain an adequate visibility of the coronal aspect of the fragment. The next step is to gain space around the fragment by creating a circumferential staging platform [2, 43] with modified Gates Glidden drills: their tip has been cut perpendicular to its long axis at its maximum cross-sectional diameter. This so-called staging platform is nothing else than an intentional ledge at the level of the coronal aspect of the fragment, to increase visibility and to facilitate the use of ultrasonic tips.

Many methods, devices, and techniques have been described in the literature to remove broken instruments. Today, the most predictable method is represented by the combination of the operating microscope, ultrasonic tips, and microtubes [2, 41, 43, 51].

9.3.9 Ultrasonic Techniques

An ultrasonic tip of appropriate size must be selected, which will be long enough to reach the fragment and thin enough to allow good visibility while working under the microscope. The tip can stay in contact with the obstacle, at minimum power, and a dry canal, so that the clinician has constant visualization of the energized tip against the broken instrument. To maintain visibility, remove the dentinal dust, and cool the ultrasonic tip, the assistant is to constantly blow air using the Stropko three-way adapter with an appropriate Luer-lock tip. The ultrasonic tip is guided counterclockwise around the obstruction to remove the dentin and expose the coronal few millimeters of the fragment. During ultrasonic use, the broken instrument begins to loosen, unwind, then spin, and oftentimes it “jumps” out of the canal.

9.3.10 Microtube Removal Methods

Sometimes, in spite of creating good coronal and radicular access, exposing 2/3 mm of the broken instrument and ultrasonic trephining, a fragment cannot be removed. In these cases, microtube removal methods should be employed to remove the

fragment, a strategy [43, 46, 51] already mentioned for the removal of silver points. The most popular products are the IRS kit, which is a microtube designed to mechanically engage the broken instrument, and the Cancellier kit, which is designed to engage the fragment using cyanoacrylate glue or self-curing dental resin. Clinically, it is important to allow sufficient curing time to promote a secure grip of the fragment.

As an alternative, the fragment can be bypassed using small hand files, perhaps aided by an aqueous chelator, to partially or completely loosen and, hopefully, remove it. As already stated, bypassing the fragment into the root canal apical to it may allow adequate disinfection. If a clinician is unable to bypass the fractured instrument, one should treat it as though a ledge could not be overcome.

The canal may be filled with warm plastified gutta-percha up to that point; sometimes, the portion of canal that was not reached fills automatically during the obturation phase. Naturally, the patient must be advised of the situation and the importance of regular checkups. Depending on whether a lesion or clinical symptoms are present, apicoectomy and retrofill, with or without surgical removal of the instrument, can be considered (see Chap. 10 in this book).

Once again, the rule that prevention is the best therapy holds true. A clinician must adhere to the following guidelines to prevent fracture of instruments in the root canal:

- One must be familiar with the physical properties and limitations of each instrument.
- The instruments must work in root canals flooded with irrigating solutions, never in dry canals.
- Hand instruments should be precurved and used in the proper sequence.
- Instruments must be worked delicately and preferably on withdrawal from the canal, not on entry.
- Rotary or reciprocating instruments must never be forced into a tight canal; a sufficient glide path created by preceding hand instruments must be present.
- Files must be replaced as soon as they are bent or their cutting edges are deformed, and they should always be considered single use.
- Rarely instruments may have manufacturing defects, which increase the probability of fracture.

The diagnosis of instrument fracture is suggested by the observation of sudden inability to probe a canal from which the last instrument has emerged slightly shorter. A radiograph may confirm the presence of an instrument fragment.

If attempts to remove the fragment are successful, it is advisable to obtain another radiograph to document the removal. For legal reasons, if an instrument fractures, it is essential that the patient be informed [52].

In cases when the broken file segment is unable to be retrieved, and in the presence of signs and/or symptoms, surgery or extraction may be the best treatment option.

9.4 Perforation Repair

Perforations are pathological or iatrogenic communications between the root canal space and the attachment apparatus, and they create an “additional” portal of exit in the root canal system. An inflammatory reaction is established in the surrounding periodontium at the site of the perforation. This is due both to the mechanical trauma and to the introduction of debris or toxic substances that inevitably accompany it. Apart from iatrogenic mishaps, spontaneous perforations occur due to caries, or internal or external resorption.

The perforation, once identified, must be sealed as quickly as possible, since periodontal involvement arising from it can become irreversible with time.

Treating a perforation may require a multidisciplinary approach in order to establish a correct treatment plan, and the team must decide whether to extract or direct efforts toward nonsurgical retreatment, surgical correction, or both.

When evaluating a perforated tooth, four variables should be considered, both individually and collectively, level, location, size and shape, and time [53, 54]:

- *Level.* Perforations can occur in the coronal, middle, and apical one-third. The level of perforations will influence the prognosis: perforations of the apical and middle third have a much better prognosis than perforations of the coronal third or of the pulp chamber floor of multirouted teeth.
- *Location.* Perforations can occur circumferentially, on the buccal, lingual, mesial, or distal aspects of the roots. This is critical if surgical access is considered, while it is not so important in case of nonsurgical retreatment.
- *Size and shape.* The establishment of a good seal is mainly influenced by the dimension and shape of the perforation. The bigger the size, the bigger the area to seal. Furthermore, lateral or furcal perforations are rarely round, but rather elliptical in shape, since the burr meets the canal wall at an angle. Finally, the perforating cavity has no taper, and this makes even more difficult to establish a good apical seal without disturbing the surrounding periodontium.
- *Time.* The time interval between the perforation and obturation will influence the prognosis. As already stated, perforations create an inflammatory reaction in the adjacent tissues and a consequent loss of attachment with a connection to a periodontal pocket and subsequent microbial contamination. Therefore, to prevent periodontal breakdown, perforations should be sealed as soon as possible, if possible, in the same appointment they occur.

In conclusion, the more coronal the perforation is and the longer the time interval, the worse is the prognosis.

9.4.1 Perforations of the Apical One-Third

These may occur in the course of instrumentation of curved canals, transposing the apical foramen.

If the endodontist succeeds (with small, precurved instruments, a lot of irrigation, and a great deal of patience) in finding the original canal, damage due to the perforation may be minimal, especially if the perforation is small. It can be treated as an additional lateral canal and will be obturated. Larger perforations may require MTA (Mineral trioxide aggregate; Dentsply Tulsa Dental, Tulsa, OK, USA) plugs to prevent overfilling.

If the path of the original canal has become obstructed by dentinal debris and the instrument follows the wrong path into the perforation each time, the canal should be filled using common techniques with subsequent surgical removal of the apex containing the untreated portion of the canal. This is particularly necessary in a tooth with a necrotic pulp.

9.4.2 Perforations of the Middle One-Third

Perforations of the middle third of the root can occur during access cavity preparation, or, more often, it occurs during cleaning and shaping of the canal or during preparation of a post space with rotating instruments such as Peeso, Gates Glidden, Largo, or similar drills.

In the second instance, the perforations are more frequent in molars and are due to excessive dentin removal on the inner, concave side of curved root canals, toward the so-called danger zone of the furcation. The roots most often affected are the mesial roots of lower molars and the mesiobuccal roots of upper molars, in which the dentinal wall facing the bifurcation is thinned out, with consequent stripping.

During space preparation for a screw or post, perforations can occur in any root. These perforations are most frequent in mesial roots of lower molars and mesiobuccal roots of upper molars, where the injury caused by excessive enlargement can become evident long afterward. Such roots must never be enlarged to receive a post, since the risk of stripping or perforation is very high.

In molars, the safest roots in which a space can be prepared for a post are the distal root of lower molars and the palatal root of upper molars. This space, however, must always be performed by keeping in mind the inclination of the tooth, the curvature of the canal, the anatomy of the root, its thickness, as well as the size of the bur [55]. The preparation of the post space should merely remove the root canal filling. The operator should avoid any alteration of the dentinal walls, and may use the space prepared by the endodontist during the shaping procedure.

9.4.3 Perforations of the Coronal Third and of the Bifurcations

Perforations of the coronal third may occur when an access cavity or cavity for a post or screw is prepared without considering the inclination of the tooth in the arch or the anatomy of the roots.

At the level of bifurcations, false paths can be due to the search for the orifice of a canal in a calcified pulp chamber; for example, the removal of an excessive amount

of dentin in the wrong direction can lead to perforation of the pulp chamber floor or perforation of the most coronal portion of the root canal. In other cases, preparation of an inadequate access cavity may be the cause. This can be avoided by using ultrasonic tips and the microscope.

As a consequence of mechanical trauma and infection from the oral cavity, there is rapid destruction of the periodontal ligament. The alveolar bone immediately adjacent to the perforation is resorbed with consequent vertical loss of bone. The inflammatory process then extends coronally from the site of the perforation along the fibers of the periodontal ligament, with destruction of the ligament, alveolar bone, and supracrestal gingival fibers. As a consequence, an apical migration of the epithelial attachment occurs, and then an advanced periodontal defect forms [56, 57].

9.4.4 Materials and Techniques

In perforation repair, good visibility is important, and combines illumination and magnification. It is best accomplished under the operating microscope, which has dramatically improved nonsurgical retreatment predictability.

Historically, a variety of sealing materials have been suggested [53–57]: Cavit, amalgam, calcium hydroxide, gutta-percha, as well as resins, EBA, and MTA cements. Regardless of the material to be used, clinicians who desired to predictably repair perforations always have had two main challenges: first, one needs to establish hemostasis and avoid overfilling, by compacting a barrier through the opening toward the furcal or root surface [58, 59]. Barriers should be biocompatible, absorbable, and supportive of new bone growth. The matrix is placed nonsurgically through the access cavity, into a three-walled osseous defect. The internal matrix provides a wall to control the placement of a restorative material; time-tested barriers include Collacote (Calcitek, Carlsbad, CA, USA), tricalcium phosphate, and calcium phosphate [43, 58–62].

The second challenge to successfully repair a perforation is to select a restorative material that is easy to use, seals well, is not resorbable, esthetically pleasing, and biocompatible for new tissue formation. The materials used and commonly employed to repair perforations include traditional amalgam (declining use), Super EBA resin cement (Bosworth, Skokie, Illinois), composite-bonded restorations utilizing adhesion dentistry, and mineral trioxide aggregate (MTA, see also below) [63–66].

Currently, all the restorative materials used today, except MTA, require a dry field to ensure a proper seal. As such, a barrier material must be selected that produces a dry preparation and a backstop that controls the placement of the restorative material and prevents overfilling. The use of MTA does not always require barrier material.

9.4.5 Collacote as a Barrier

This technique is indicated when, due to a long-standing perforation and subsequent leakage, a lateral root lesion has formed. In such a case, the clinical challenge is to

properly place a solid external resorbable matrix that will allow packing of restorative material. It is important, therefore, to establish a length from the reference point to the consistent drying point that defines the cavosurface of the root.

Collacote is an absorbable collagen material (removed in only 10–14 days), has excellent working properties that provide complete hemostasis, and provides a controlled barrier. It is relatively inexpensive, biocompatible, and supports new tissue growth.

With a barrier-type technique, the restorative material selected to repair a perforation site should be based on personal judgment, experience, research, ease of handling, and the advantages or disadvantages of a particular material in a particular clinical setting. If Super EBA is the material of choice, the resin cement is spatulated, incorporating as much powder into the liquid as possible, so that a heavy, viscous, putty-type mix is created. A small conically shaped aliquot of Super EBA resin cement is attached to the working end of a Schilder plugger. The plugger carries and delivers the restorative into the preparation and packs the material purposefully into place. Progressive placement and packing of small increments of Super EBA resin cement fills the defect

9.4.6 Perforation Repair with Mineral Trioxide Aggregate (MTA)

The prognosis of perforation has been improved consistently with the use of the operating microscope [58, 59] and after MTA became available to seal the defects [65] developed by Mahmoud Torabinejad of Loma Linda University, California (Fig. 9.18). MTA is very biocompatible, hydrophilic, and capable to stimulate healing processes and osteogenesis [65, 66]; it is commercialized as a powder that consists of fine mineral trioxides and other hydrophilic particles, which sets in the presence of moisture. Hydration of the powder results in a colloidal gel that solidifies to a hard structure in about 4 h. This cement differs from all other materials in its biocompatibility, its antibacterial activity, its marginal adaptation, and sealing properties, and mostly because it is hydrophilic and therefore resistant to moisture.

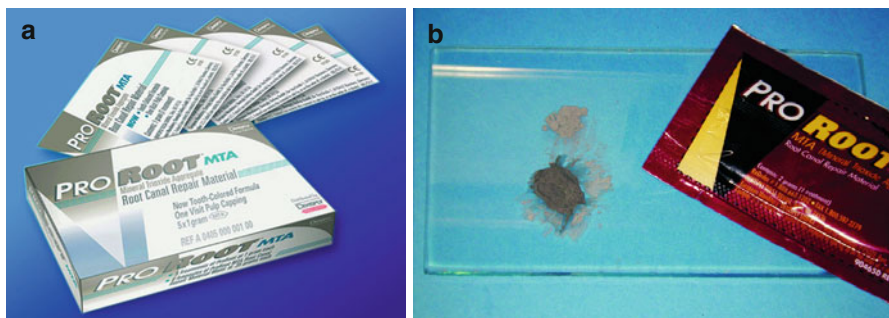


Fig. 9.18 White (a) and Gray (b) MTA (ProRoot MTA, Dentsply Maillefer, Ballaigues, Switzerland)

Every material used to repair perforations, to seal retropreparations in surgical endodontics, to close the open apices, or to protect the pulp in direct pulp cappings, is inevitably in contact with blood or other tissue fluids. Torabinejad et al. demonstrated that MTA is the only material that is not damaged by moisture or blood contamination [65]. In fact, MTA sets only in contact with moisture and may be considered the currently best suited material to repair perforations [66–69] (Figs. 9.19 and 9.20).

In our opinion, for a nonsurgical retreatment to be categorized as successful, the treated tooth must meet each of the following requirements:

- Absence of symptoms, such as spontaneous pain or pain on palpation or percussion
- Absence of excessive mobility
- Lack of oral communication with the opening of the perforation (pocket)
- Absence of a sinus tract
- Tooth in function
- Absence of radiographic signs of demineralization of bone adjacent to the perforation
- Thickness of the periodontal ligament adjacent to the obturating material no more than double the thickness of the surrounding ligament

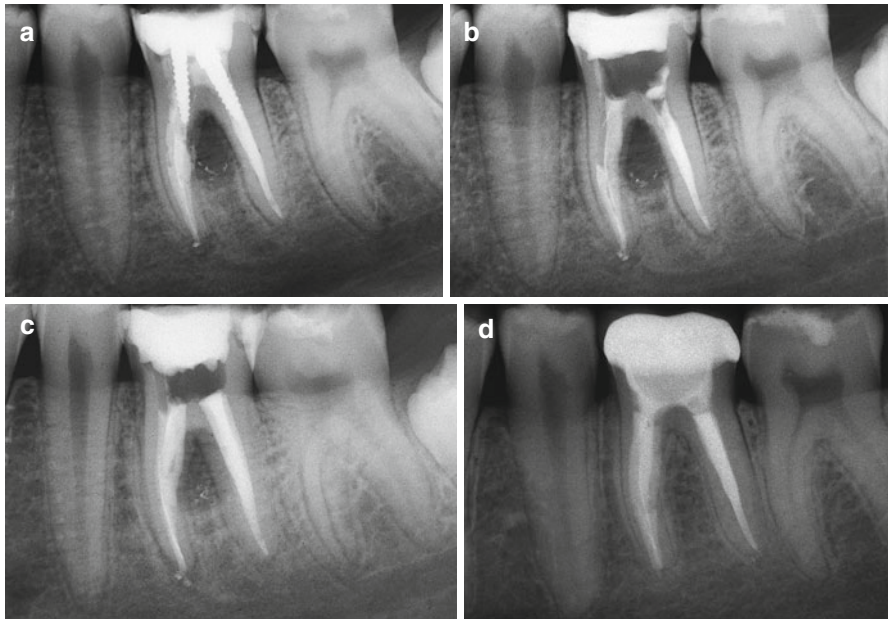


Fig. 9.19 Strip perforation of the mesial root of the lower left first molar, caused by the introduction of a screw post in the mesiobuccal canal. (a) Preoperative radiograph. (b) After nonsurgical retreatment, the obturation with Schilder technique has been made in the distal, in the mesiolingual, and in the mesiobuccal canal, apical to the perforation. (c) Postoperative radiograph: the coronal one-third of the mesiobuccal canal has been completely obturated with MTA, from the perforation up to the orifice. (d) The recall radiograph after 15 years shows the complete healing

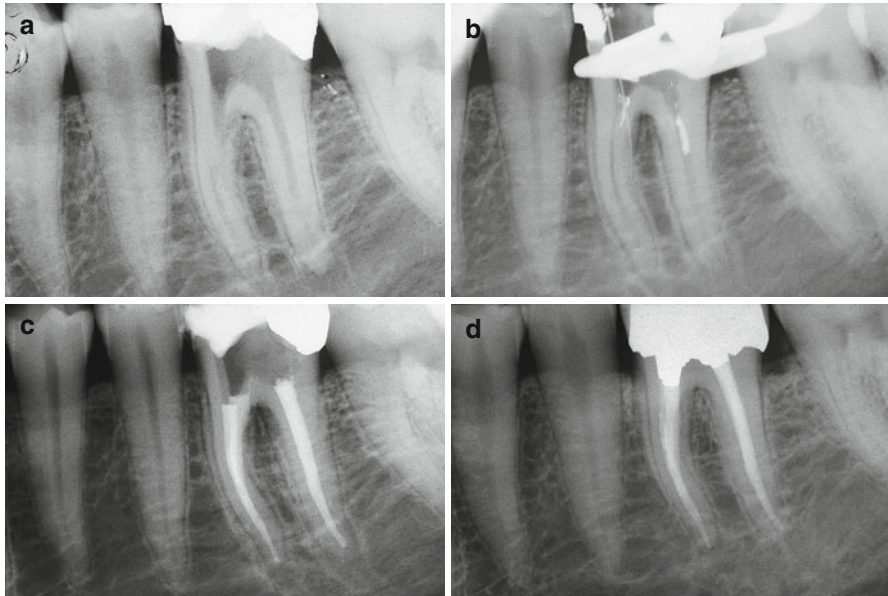


Fig. 9.20 In an attempt to find the mesiobuccal canal, a perforation was made in the floor of the pulp chamber. (a) Preoperative radiograph. (b) A small file has been introduced in the bleeding area and has been connected to an electronic apex locator to confirm the diagnosis of a perforation. (c) Postoperative radiograph. The coronal portion of the mesial canal has been filled with MTA before obturating the apical part with warm gutta-percha. (d) 2-year recall

References

1. American Association of Endodontists. Glossary of endodontic terms 2015. Available from: <http://www.nxtbook.com/nxtbooks/aae/endodonticglossary2015/>. Accessed 27 Feb 2016.
2. Carr GB. Retreatment. In: Cohen S, Burns RC, editors. Pathways of the pulp. 7th ed. St. Louis: The C.V. Mosby Company; 1998. p. 791–834.
3. Chen SC, Chueh LH, Hsiao CK, Tsai MY, Ho SC, Chiang CP. An epidemiological study of tooth retention after nonsurgical endodontic treatment in a large population in Taiwan. *J Endod.* 2007;33:226–9.
4. Paredes-Vieyra J, Jimenez Enriquez FJ. Success rate of single- versus two visit root canal treatment of teeth with apical periodontitis: a randomized controlled trial. *J Endod.* 2012;38(9):1164–9.
5. Sonntag D, Delschen S, Stachniss V. Root-canal shaping with manual and rotary Ni-Ti files performed by students. *Int Endod J.* 2003;36:715–23.
6. Pettiette MT, Delano EO, Trope M. Evaluation of success rate of endodontic treatment performed by students with stainless-steel K-files and nickel-titanium hand files. *J Endod.* 2001;27:124–7.
7. Pjetursson BE, Thoma D, Jung R, Zwahlen M, Zembic A. A systematic review of the survival and complication rates of implant-supported fixed dental prostheses (FDPs) after a mean observation period of at least 5 years. *Clin Oral Implants Res.* 2012;23:22–38.
8. Morris MF, Kirkpatrick TC, Rutledge RE, Schindler WG. Comparison of nonsurgical root canal treatment and single-tooth implants. *J Endod.* 2009;35:1325–30.
9. Salehrabi R, Rotstein I. Epidemiologic evaluation of the outcomes of orthograde endodontic retreatment. *J Endod.* 2010;36:790–2.

10. Fristad I, Molven O, Halse A. Nonsurgically retreated root-filled teeth: radiographic findings after 20–27 years. *Int Endod J.* 2004;37:12–8.
11. Davies A, Mannocci F, Mitchell P, Andiappan M, Patel S. The detection of periapical pathoses in root filled teeth using single and parallax periapical radiographs versus cone beam computed tomography – a clinical study. *Int Endod J.* 2015;48:582–92.
12. Torabinejad M, Corr R, Handysides R, Shabahang S. Outcomes of nonsurgical retreatment and endodontic surgery: a systematic review. *J Endod.* 2009;35:930–7.
13. Harty FJ, Parkins BJ, Wengraf AM. Success rate in root canal therapy: a retrospective study of conventional cases. *Br Dent J.* 1970;28:65–70.
14. Walton R. Histologic evaluation of different methods of enlarging the pulp canal space. *J Endod.* 1976;2:304–11.
15. Chen SC, Chueh LH, Hsiao CK, Wu H-P, Chiang CP. First untoward events and reasons for tooth extraction after nonsurgical endodontic treatment in Taiwan. *J Endod.* 2008;34:671–4.
16. Sundh B, Odman P. A study of fixed prosthodontics performed at a University clinic 18 years after insertion. *Int J Prosthodont.* 1997;10:513–9.
17. Yoshino K, Ito K, Kuroda M, Sugihara N. Prevalence of vertical root fracture as the reason for tooth extraction in dental clinics. *Clin Oral Investig.* 2015;19:1405–9.
18. Berman LH, Kuttler S. Fracture necrosis: diagnosis, prognosis assessment, and treatment considerations. *J Endod.* 2010;36:442–6.
19. Magura ME, Kafrawy AH, Brown CE, Newton CW. Human saliva coronal leakage in obturated root canals : an in vitro study. *J Endod.* 1991;17:324–31.
20. Sundqvist G, Figdor D, Persson S, Sjogren U. Microbiologic analysis of teeth with failed endodontic treatment and the outcome of conservative retreatment. *Oral Surg Oral Med Oral Pathol Oral Radiol Endod.* 1998;85:86–93.
21. Gorni FG, Gagliani MM. The outcome of endodontic retreatment: a 2-yr follow-up. *J Endod.* 2004;30:1–4.
22. de Chevigny C, Dao TT, Basrani BR, et al. Treatment outcome in endodontics: the Toronto study—phases 3 and 4: orthograde retreatment. *J Endod.* 2008;34:131–7.
23. Paik S, Sechrist C, Torabinejad M. Levels of evidence for the outcome of endodontic retreatment. *J Endod.* 2004;30:745–50.
24. Rotstein I, Simon JH. The endo-perio lesion: a critical appraisal of the disease condition. *Endod Topic.* 2006;13:34–56.
25. Tamse A, Fuss Z, Lustig J, Kaplavi J. An evaluation of endodontically treated vertically fractured teeth. *J Endod.* 1999;25:506–8.
26. Kwan S, Abbott PV. Bacterial contamination of the fitting surfaces of restorations in teeth with pulpal and periapical disease. *Aust J Dent.* 2012;57:421–8.
27. Chavez DePaz LE, Dahlén G, Molander A, Möller A, Bergenholtz G. Bacteria recovered from teeth with apical periodontitis after antimicrobial endodontic treatment. *Int Endod J.* 2003;36:500–8.
28. De Paz LC. Redefining the persistent infection in root canals: possible role of biofilm communities. *J Endod.* 2007;33:652–62.
29. Hong BY, Lee TK, Lim SM, Chang SW, Park J, Han SH, Zhu Q, Safavi KE, Fouad AF, Kum KY. Microbial analysis in primary and persistent endodontic infections by pyrosequencing. *J Endod.* 2013;39:1136–40.
30. Dechouniotis G, Petridis XM, Georgopoulou MK. Influence of specialty training and experience on endodontic decision making. *J Endod.* 2010;36:1130–4.
31. Setzer FC, Shah SB, Kohli MR, Karabucak B, Kim S. Outcome of endodontic surgery: a meta-analysis of the literature-part 1: comparison of traditional root-end surgery and endodontic microsurgery. *J Endod.* 2010;36:1757–65.
32. Danin J, Linder LE, Lundqvist G, Ohlsson L, Ramsköld LO, Strömberg T. Outcomes of periapical surgery in cases with apical pathosis and untreated root canals. *Oral Surg Oral Med Oral Pathol Oral Radiol Endod.* 1999;87:227–32.
33. Patel S, Durack C, Abella F, Shemesh H, Roig M, Lemberg K. Cone beam computed tomography in endodontics – a review. *Int Endod J.* 2015;48:3–15.

34. Cohen AG. The efficiency of solvents used in the retreatment of paste-filled root canals. Masters Thesis, Boston University; 1986.
35. Friedman S, Stabholz A, Tamse A. Endodontic retreatment: case selection and technique. Part 3: retreatment techniques. *J Endod.* 1990;16:543-9.
36. Jeng HW, ElDeeb ME. Removal of hard paste fillings from the root canal by ultrasonic instrumentation. *J Endod.* 1987;13:295-8.
37. Krell KV, Neo J. The use of ultrasonic endodontic instrumentation in the retreatment of paste-filled endodontic teeth. *Oral Surg Oral Med Oral Pathol.* 1985;60:100-2.
38. Hülsmann M. The retrieval of silver cones using different techniques. *Int Endod J.* 1990;23:298-303.
39. Fors UGH, Berg JO. Endodontic treatment of root canals obstructed by foreign objects. *Int Endod J.* 1986;19:2-10.
40. Krell KV, Fuller MW, Scott G. The conservative retrieval of silver cones in difficult cases. *J Endod.* 1984;10:269-73.
41. Nagail O, Tani N, Kayaba Y, Kodama S, Osada T. Ultrasonic removal of broken instruments in root canals. *Int Endod J.* 1986;19:298-304.
42. Brady JM, Del Rio CE. Corrosion of endodontic silver cones in human: a scanning electron microscope and X-ray microprobe study. *J Endod.* 1975;1:205-10.
43. Ruddle CJ. Nonsurgical endodontic retreatment. In: Cohen S, Burns RC, editors. *Pathways of the pulp.* 8th ed. St. Louis: The C.V. Mosby Company; 2002. p. 875-929.
44. Roig-Greene JL. The retrieval of foreign objects from root canals: a simple aid. *J Endod.* 1983;9:394-7.
45. Masserann J. The extraction of instruments broken in the radicular canal: a new technique. *Acta Odont Stomatol.* 1959;47:265-74.
46. Ruddle CJ. Nonsurgical endodontic retreatment. In: Castellucci A, editor. *Endodontics Vol. III.* Firenze: II Tridente; 2009;998-1075.
47. Kapalas A, Lambrianidis T. Factors associated with root canal ledging during instrumentation. *Endod Dent Traumatol.* 2000;16:229-31.
48. Roda RS, Gittleman BH. Nonsurgical retreatment. In: Hargreaves KM, Berman LH, editors. *Cohen's pathways of the pulp.* 11th ed. St. Louis: Elsevier; 2016. p. 371-3.
49. Jafarzadeh H, Abbott P. Ledge formation: review of great challenge in endodontics. *J Endod.* 2007;33:1155-62.
50. Grossman LI. Guidelines for the prevention of fracture of root canal instruments. *Oral Surg Oral Med Oral Pathol.* 1968;28:746-52.
51. Ruddle CJ. Broken instrument removal. The endodontic challenge. *Dent Today.* 2002;21:70-2.
52. Frank AL. The dilemma of the fractured instrument. *J Endod.* 1983;9:515-6.
53. Jew RCK, Weine FS, Keene JJ, Smulson MH. A histologic evaluation of periodontal tissues adjacent to root perforations filled with Cavit. *Oral Surg Oral Med Oral Pathol.* 1982;54:124-35.
54. Benenati FW, Roane JB, Biggs JT, Simon JH. Recall evaluation of iatrogenic root perforations repaired with amalgam and gutta-percha. *J Endod.* 1986;12:161-6.
55. ElDeeb ME, Eldeeb M, Tabibi A, Jensen JR. An evaluation of the use of amalgam, Cavit, and calcium hydroxide in the repair of furcation perforations. *J Endod.* 1983;8:459-66.
56. Frank AL, Weine FS. Nonsurgical therapy for the perforative defect of internal resorption. *J Am Dent Assoc.* 1973;87:863-8.
57. Lantz B, Persson P. Periodontal tissue reactions after surgical treatment of root perforations in dog's teeth: a histologic study. *Odontol Revy.* 1970;21:51-62.
58. Ruddle CJ. Endodontic perforation repair: using the surgical operating microscope. *Dent Today.* 1994;13:48, 50, 52-3.
59. Kim S, Rethnam S: Hemostasis in endodontic microsurgery. In: *Microscopes in Endodontics, dental clinics of North America.* Philadelphia: W.B. Saunders; 1997, 41:3. p. 499-511.
60. Alhadainy Y HA, Abdalla AI. Artificial floor technique used for the repair of furcation perforations: a microleakage study. *J Endod.* 1998;24:33-5.
61. Pecora G, Baek S, Rethnam S, Kim S. Barrier membrane techniques in endodontic microsurgery. In: *Microscopes in endodontics, dental clinics of North America.* Philadelphia: W.B. Saunders; 1997, 41:3. p. 585-602.

62. Sottosanti J. Calcium sulfate: a biodegradable and biocompatible barrier for guided tissue regeneration. *Compend Contin Educ Dent*. 1992;13:226–8, 232–4.
63. Moloney LG, Feik SA, Ellender G. Sealing ability of three materials used to repair lateral root perforations. *J Endod*. 1993;19:59–62.
64. Nakata TT, Bae KS, Baumgartner JC. Perforation repair comparing mineral trioxide aggregate and amalgam using an anaerobic bacterial leakage model. *J Endod*. 1998;24:184–6.
65. Torabinejad M, Hong CU, McDonald F, Pitt Ford TR. Physical and chemical properties of a new root-end filling material. *J Endod*. 1995;21:349–53.
66. Sarkar NK, Caicedo R, Ritwik P, Moiseyeva AR, Kawashima I. Physicochemical basis of the biologic properties of mineral trioxide aggregate. *J Endod*. 2005;31:97–100.
67. Thomson TS, Berry JE, Somerman MJ, Kirkwood KL. Cementoblasts maintain expression of osteocalcin in the presence of Mineral Trioxide Aggregate. *J Endod*. 2003;29:407–12.
68. Torabinejad M, Higa RK, McKendry DJ, Pitt Ford TR. Dye leakage of four root-end filling materials: effects of blood contamination. *J Endod*. 1994;20:159–63.
69. Bargholz C. Perforation repair with mineral trioxide aggregate: a modified matrix concept. *Int Endod J*. 2005;38:59–69.

Endodontic Microsurgery for Molars

10

Enrique M. Merino

Abstract

For molars that cannot be successfully treated with nonsurgical procedures, endodontic microsurgery may offer a promising alternative. This approach relies on technology, such as the operating microscope, ultrasonic instruments, filling materials, knowledge and manual skills on microsurgery, and guided bone regeneration techniques, all in a structured approach. This process includes a thorough diagnostic workup including a CBCT scan, a sequence of planned treatment steps, and appropriate outcome assessment. In the hands of a skilled operator, endodontic microsurgery enjoys high success rates.

Guiding Reference

Setzer FC, Shah SB, Kohli MR, Karabucak B, Kim S. Outcome of endodontic surgery: a meta-analysis of the literature-part 1: comparison of traditional root-end surgery and endodontic microsurgery. *J Endod.* 2010;36:1757–65.

This study investigated the outcome of root-end surgery, specifically when comparing traditional root-end surgery and endodontic microsurgery. The latter was defined to include ultrasonic preparation and filling materials as well as microsurgical instruments, high-power magnification, and illumination. A meta-analysis based on 21 studies indicated that the application of modern microsurgical methods resulted in 95 % success, while traditional methods achieved success only on 59 % of the cases. Therefore, the use of microsurgical techniques is superior for root-end surgery when compared with traditional techniques.

E.M. Merino, MD, DDS
European University, Madrid, Spain
Complutense University, Madrid, Spain

Private Practice, Plaza La Inmaculada, 24001 Leon, Spain
e-mail: enriqueimmerino@gmail.com

10.1 Introduction

As discussed previously in Chaps. 8 and 9, failing endodontic treatments are based in principle on the percolation of bacteria or their by-products from inside the root canal system to the periodontium, where interaction with the host immune system occurs. Therefore, success is related to clinical strategies and techniques that prevent this interaction [1].

Nonsurgical retreatment may provide acceptable clinical outcomes; however, this is only realistic when the clinician can overcome procedural errors that prevent thorough disinfection [2]. Surgical endodontics is then often the last opportunity to save a tooth; the decision to perform a surgery should only be made after all previous nonsurgical attempts have failed or are not feasible. The ultimate goal of endodontic microsurgery is the predictable regeneration of periapical tissues and osseous defects [3]; clinical outcomes with this strategy are clearly superior to conventional apical surgery [4].

10.2 Rationale for Endodontic Microsurgery

This treatment provides healing outcomes when spaces of the root canal system that harbor microorganisms can be readily identified, debrided, and filled with a bio-compatible material.

To this end and in brief, surgical access to the involved root apices is gained and 3 mm of the respective apex is resected under magnification. The granulation tissues are then removed. A retrocavity of 3 mm depth is adequately prepared and sealed with a biocompatible material in each of the sectioned roots. The need of guided bone regeneration techniques must be evaluated before suturing the flap back in place.

10.3 Diagnostic Steps Before Endodontic Microsurgery

Periodontal probing has to be performed for teeth in the areas as it informs about the profile of the bony crest all around the molar, and most importantly, the width and length of any discontinuity of it (Fig. 10.1).

Classic radiographic techniques like periapical and panoramic radiographs are limited in detecting few periapical bone lesions and therefore cone beam computed tomography (CBCT) [5] is now the standard radiographic technique used to prepare a treatment plan in surgical endodontics (see Box 10.1).

10.4 Endodontic Microsurgery Step by Step

10.4.1 Flap Design

Similar to the access cavity in nonsurgical endodontics, which provides access to canal entries and makes the treatment feasible, flap design is the “access cavity” at the soft tissue level that allows good visibility to the bone level. It is also extremely

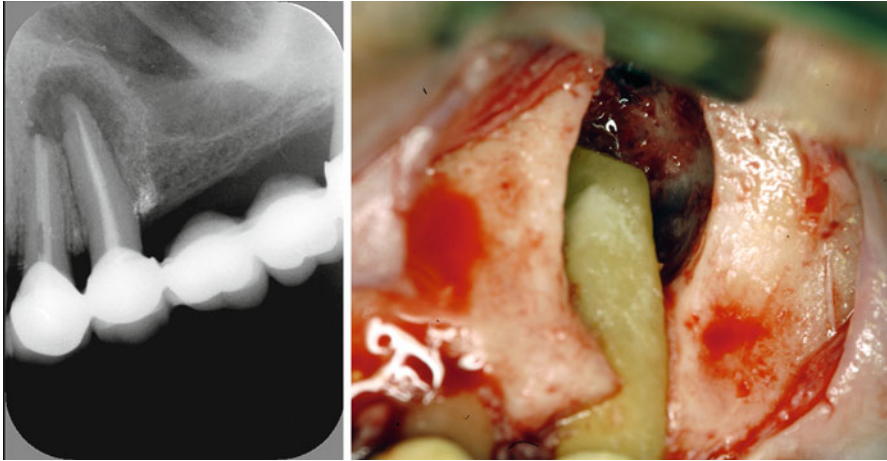


Fig. 10.1 Preoperatively and from the radiograph (*left*), this defect appeared localized and perhaps readily managed. However, after raising the flap (*right*), the full extent of the apicomarginal bone defect became visible (Reprinted from Merino 2009, with permission)

Box 10.1. Diagnosis of Bony Defects

Type of defect	Extent	Periodontal probing	Findings			GBR/ membrane recommended
			Radiographic	CBCT		
“Endo”	Small	Normal	Yes	Yes	No	
	Large	Normal	Yes	Yes	No	
	Through-and-through	Normal	No	Yes	Yes	
“Endo-Perio”	Apicomarginal	Deep	No	Yes	Yes	
	Large periapical	Normal	Yes	Yes	Yes	
Combinations	Large periapical or lateroradicular and Through-and-through	Normal	Yes	Yes	Yes	
		Deep	No	Yes	Yes	

important because it must allow sufficient blood supply to the mobilized and nonmobilized soft tissues [6–10].

Also, all factors, possible incidents, and modifications of the ongoing microsurgery must be taken into consideration before the first incision is made. Therefore, when facing an apicomarginal bone defect, the flap design should be made large enough in order to have the bone donor site under the same flap, moreover, it must allow covering of the bone graft without tension on the flap [11].

Modifications to the flap after the incisions have been made can jeopardize the final result.

Rectangular and triangular flaps are the typical designs for microsurgery in the molar region. The first flap consists of one horizontal sulcular incision and two vertical ones; while the triangular one is similar, but with only one vertical incision.

“*The golden rules of the flap design*” [12] are critical factors the clinician must pay attention to them all the time, in order to perform an easy, fast microsurgery with less complicated post-op for the patient:

- The incision must never cross a bone defect. Incisions should be made away from the lesion if possible.
- Releasing incisions between bone eminences should be over concave bone surfaces and should never cross over convex bone eminences.
- The end of a vertical incision at the gingival crest should finish at the angular line of the tooth (*black line* in Fig. 10.2a), perpendicular to the gingival margin (Fig. 10.2b). The other end should never enter into the mucobuccal fold, so a little inclination of the incision (*blue line* in Fig. 10.2a) is advantageous.
- The base must be as wide as its free edge. Vertical releasing incisions should follow the direction of the vascularization network, which is oriented mainly perpendicular to the occlusal plane in corono-apical direction [13]. Flap blood perfusion is maintained up to the point where the ratio of length to width of the rectangular flap equals 2:1 [14, 15]. Ideally, the shorter the vertical incisions, the larger the horizontal one should be; likewise, the longer the vertical incisions, the shorter the horizontal one.

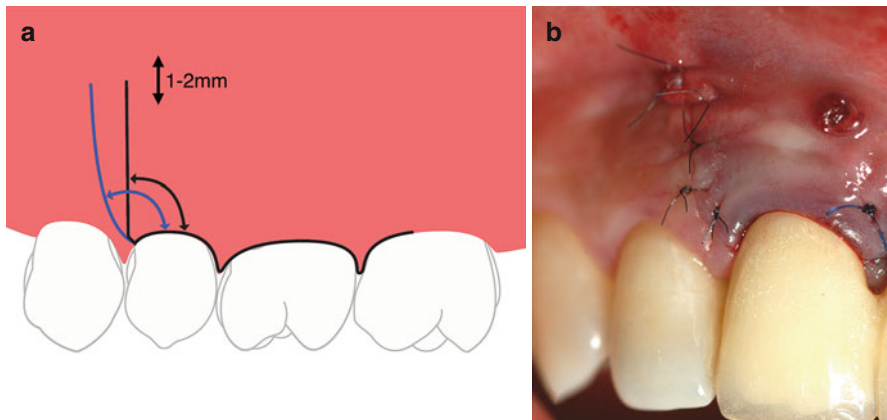


Fig. 10.2 (a) The incision (*black line*) must never finish on thin buccal tissue or in the center line of the papilla, as this can compromise the fine vascularization and may cause tissue necrosis with a poor esthetic result. The incision can be tilted minimally (*blue line*) without crossing the next alveolar bone eminence, in order to open the angle and to keep the incision in attached gingiva. It is advantageous to keep the end incision within the attached gingiva and 1–2 mm away from the mucosa. (b) Placing the incision perpendicular to the marginal gingiva toward the base of the papilla is critical to create space for a stitch that will keep the position of the gingival margin stable during the healing process

- The periosteum must be raised all together with the flap. This makes the suturing procedure easier and speeds up the healing process, diminishing postoperative pain and inflammation.
- The retractor must always rest on bone, never on soft tissues.
- All sutures must start by needle insertion through the upper surface of the released tissue, before passing it through the lower surface of the unreleased tissue.

10.4.2 Incision (Low-Power Magnification)

Standard #15 or #15C blades or microsurgical scalpel blades are used and the “Pencil hold” is the most used hand position (Fig. 10.3a, b). Incisions should be made with a firm and continuous movement of the blade at 90° to the bone so that a full mucoperiosteal flap is elevated.

10.4.3 Elevation of the Flap

The purpose of this step is to raise the already cut flap to allow visibility of the bone. The flap should be elevated in such a way that, when back in place, it will rest passively in the desired position. A sharp, small, straight, or curved elevator, for example Molt 9, P145S, P9HM, or similar (Fig. 10.3c), is placed at the junction of the horizontal and vertical incisions, with its concave surface against the bone (Fig. 10.3d).

10.4.4 Retraction

Retraction is done to maintain the flap allowing maximum access and visibility without causing damage to the flap or neighboring tissues. A correct retraction technique improves ergonomics, reduces the surgery time, and the postoperative pain and inflammation. During surgery, soft tissue management is commonly overlooked because, once the flap is retracted, attention is usually concentrated on the defect (Fig. 10.4a, b).

Retractors are one of the most important instruments for surgical endodontics. They must be:

- Wide enough to hold flap completely (15 mm)
- Thin enough (~0.5 mm) to improve access
- Have a serrated working end to prevent sliding
- Have a matte surface, so light is not reflected

The working end of a retractor should adapt, as far as possible, to the cortical bone plate of the specific surgical area.

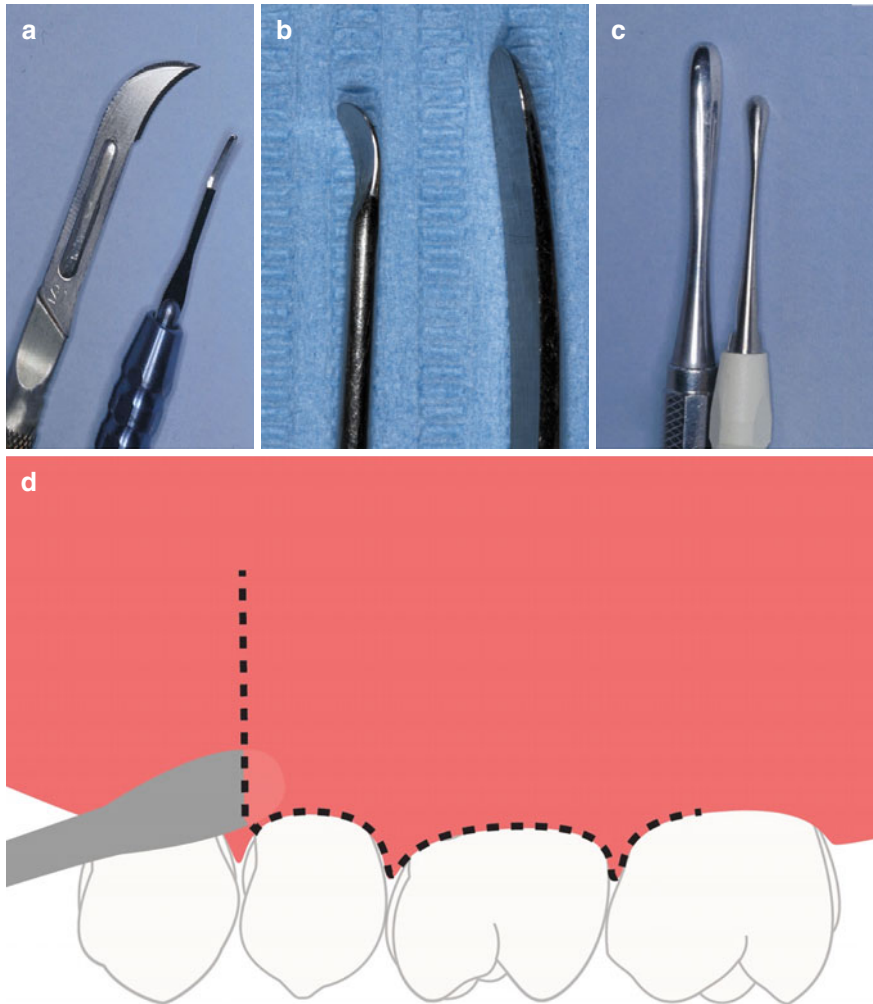


Fig. 10.3 (a) Incisions may be made perpendicularly to bone with a conventional scalpel. Alternatively, a microscalpel (b) may be used when making the incision under the microscope. (c) Prichard or Molt curettes are appropriate to initiate flap elevation. (d) Elevation may be started by inserting the elevator at the junction of the vertical and horizontal incisions; vertical force is then applied with a slow, firm, and controlled peeling motion, following closely the cortical bone contour, in order to release the flap to a level completely revealing the extent of the osseous lesion

10.4.5 Osteotomy Window (Low-Power Magnification)

An osteotomy window approximately 5 mm diameter has to be made in order to allow easy access for instruments and devices to the apex. A round tungsten bur or a 5 mm trephine may be used to create the “access cavity” at the hard tissue level, to the involved molar apices.

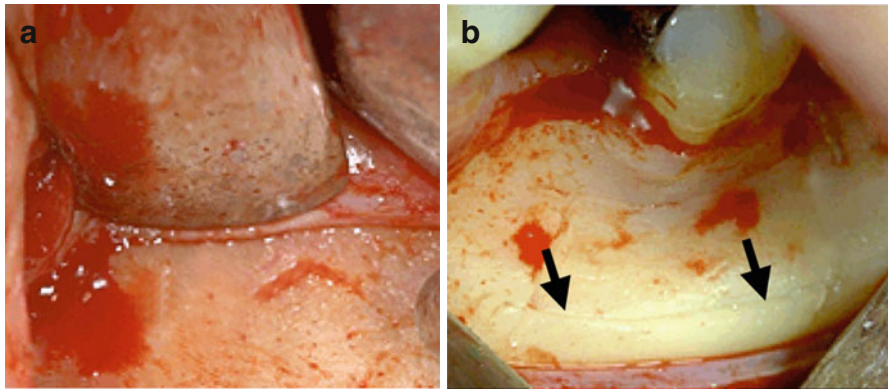


Fig. 10.4 (a) If a retractor rests on the flap, pressure will compromise the perfusion and causes ischemia within the flap, and causes more postoperative pain and inflammation. (b) Another important detail to pay attention to is the tension on the flap produced by the retractor. This tension also prevents flap perfusion; in order to decrease this tension, changes need to be made intraoperatively, for example a notch can be prepared in bone to secure retractor placement (*arrows*)

The endodontic surgeon can now encounter three different clinical situations:

- Intact cortical bone table
- Perforation of the cortical bone plate without periosteum
- Perforation of the cortical bone plate with periosteum

10.4.6 Curettage (Medium-Power Magnification)

To remove pathological tissues, foreign bodies, and bone particles from the periradicular or lateroradicular areas, curettage provides visibility and accessibility to the apex or lateral canal. Curettage should be performed as clean and fast as possible because the surgical hemostasis is directly related to a complete curettage. Lingual/palatal bone crypt walls are the most difficult areas to clean. A Lucas bone curette, 33 L spoon excavator, and Molt curettes can be used for medium and large lesions. Alternatively, Columbia #13/14, Molt, or Jaquette 34/35 curettes may be used for small lesions and lingual-palatal bone crypt walls (see Fig. 10.5).

10.4.7 Hemostasis (Medium-Power Magnification)

Clearly, hemostasis is an indispensable factor for microsurgery because a dry surgical field provides better visualization of the microanatomy, dramatically improves the surgical efficiency, and minimizes root-end filling contamination. Anesthesia (see Chap. 3 in this book) is essential in providing effective presurgical hemostasis; specifically, solutions with 1:50,000 epinephrine should be used if there are no medical contraindications. Both block and buccal/lingual-palatal injections are required

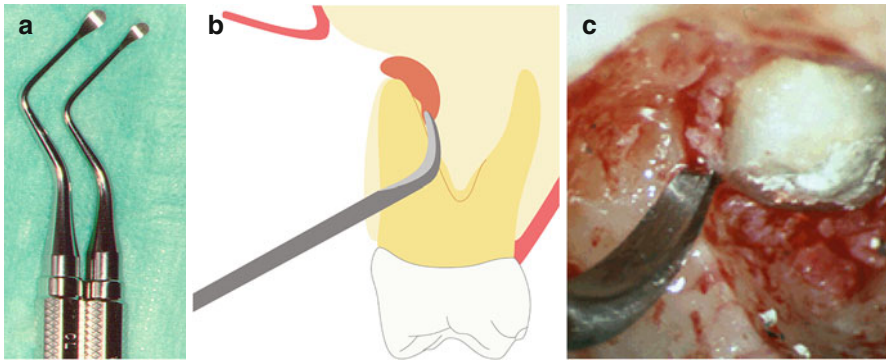


Fig. 10.5 (a) Frequently, just removing granulation tissues with a Lucas curette (sharp edge with concave and convex surfaces) is sufficient to achieve good access to the apex without removing any bone. (b, c) Jaquette 34/35 curette is specially designed to peel away the granulation tissues situated between the root and the palatal-lingual walls of the bone crypt

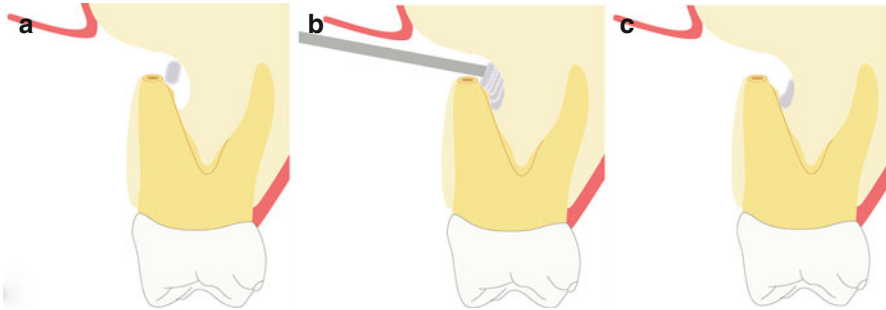


Fig. 10.6 Hemostasis in the surgical crypt may be achieved with the epinephrine pellet technique. (a) The first cotton pellet is applied against the bony crypt bottom walls. (b) Several more pellets are placed after until the bone cavity is totally filled. Pressure is applied for 4 min. (c) Then all pellets are removed subsequently, except the very first one that remains in place until final irrigation. This first pellet has two critical functions: it prevents the nicked vessels from reopening during surgery and also it prevents operative debris from lodging into the palatal/lingual bone wall of the crypt that is otherwise difficult to remove

to get effective hemostasis. The use of anesthetics during surgery to get surgical hemostasis is typically ineffective.

Topical hemostatic may be achieved with cotton pellets with or without epinephrine (Fig. 10.6) in the osseous crypt; ferric sulfate pellets can be used to achieve hemostasis outside the crypt when applied to bleeding sites on the buccal bone.

10.4.8 Apicoectomy (Low-Power Magnification for Apicoectomy and Medium- to High-Power Magnification for Inspection)

The apical 3 mm of the root(s) involved are resected (Fig. 10.7), where more complex anatomy exists; this has for example been shown histologically in extracted

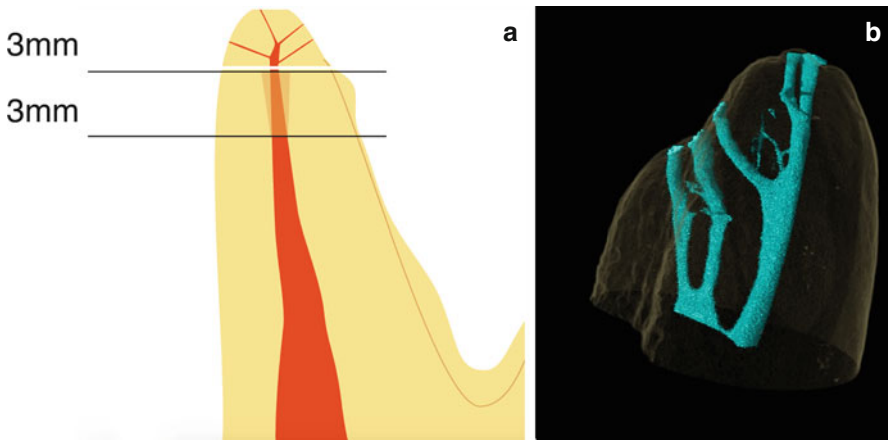
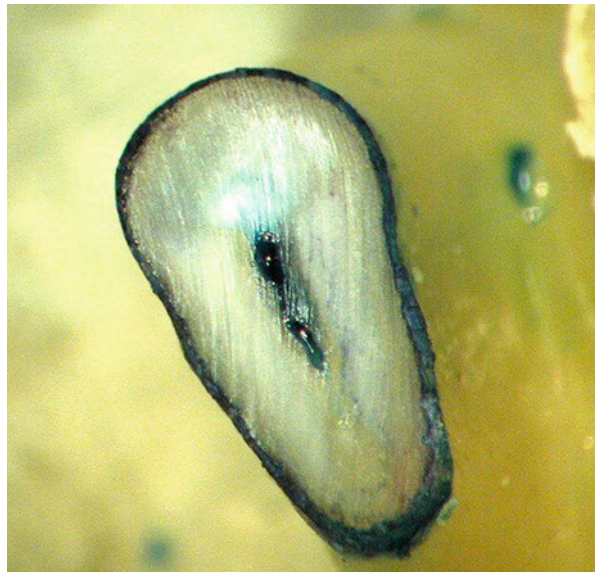


Fig. 10.7 (a) “Rule of threes”: The goal is to remove the apical 3 mm of each involved root by the apicoectomy and another 3 mm of the canal is instrumented and sealed by the retrofill. The final 6 mm of the canal is treated to eliminate or block most frequent communications at the apical third area between main canal and the periodontium. (b) Micro-computed tomography rendering of the mesio-buccal apex of a maxillary molar with multiple apical ramifications, indicating the complex anatomy that may be present in the apical portion of any molar root (Image B courtesy of Dr. O. Peters)

Fig. 10.8 Staining the resected apex with methylene blue dye discloses the presence of connective tissue and can serve to demonstrate that the cut of the root has been complete (360° continuously stained outline) or incomplete (broken outline). This staining step is also important to detect otherwise undiscovered canals, isthmuses, apical fractures, and craze lines



molars, in electron microscopic studies, and micro-computed tomography data (see also Chap. 1 in this book). Preferably there should be a 0° bevel and a fluted carbide or Lindemann bur should be used with an Impact Air handpiece, under copious irrigation. Current microinstruments like micromirrors, small ultrasonic tips, and micropluggers permit to work with such a small bevel. After resecting the apical root segment, methylene blue dye is used to ensure the resection is complete and for canals and isthmus inspection (Fig. 10.8).

10.4.9 Isthmus

One small detail left uncorrected can render the whole procedure ineffective. In this context, the “micro tissue” within the isthmus is as important as the “macro tissue” of the main canals.

Although an isthmus is an important structure in endodontic microsurgery, it was ignored in dental textbooks or scientific literature until 1983 [16]. It represents the communications that normally exist, at different levels, between two canals inside a root (Fig. 10.9a), but surgically exposed at the resected apex root area. It contains pulp tissue and should be treated in the same way as the pulp tissue of the canals. Figure 10.9b illustrates schematically how the isthmus should be prepared.

10.4.10 Root-End Preparation

In order to create a clean and well-defined Class 1 cavity into the already sectioned root it must have walls that are parallel to the major axis and well centered within the root, so as not to weaken the root walls, and deep enough to retain the biocompatible material of obturation (Fig. 10.10). The retrocavity should have at least 3 mm depth according to the “Rule of Threes” (see Fig. 10.7). Retrocavity preparation has been dramatically improved since ultrasonic (US) microtips and micromirrors were

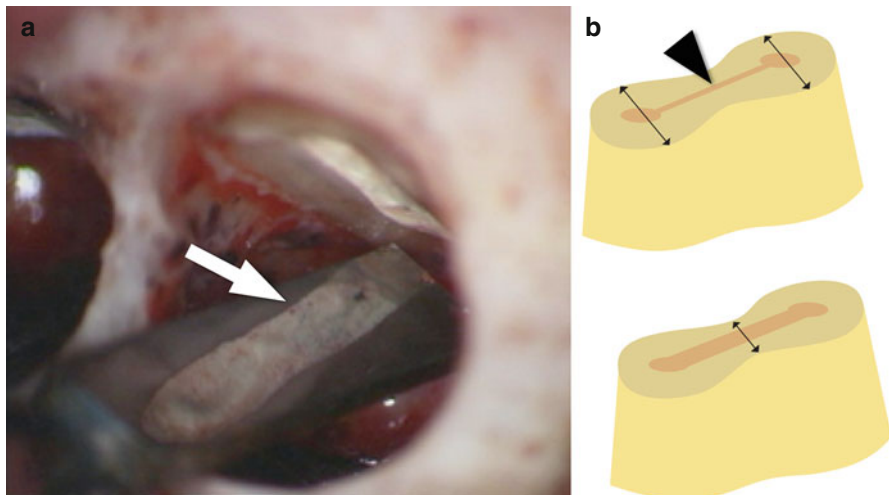


Fig. 10.9 (a) Clinical view of high-power magnification of a prepared isthmus (*arrow*) in a mesial root of a mandibular molar. Only the complete but dentin-preserving preparation of an isthmus permits adequate disinfection. (b) After the main canals are retrogradely prepared, the isthmus (*arrowhead*) must be prepared and cleaned with either a round or potentially a blade-shaped ultrasonic tip. Care has to be taken to retain sufficient dentin wall thickness (*arrows*), specifically along the isthmus in roots with figure-eight cross-sections such as the mesiobuccal roots in maxillary molars and the mesial roots in mandibular molars

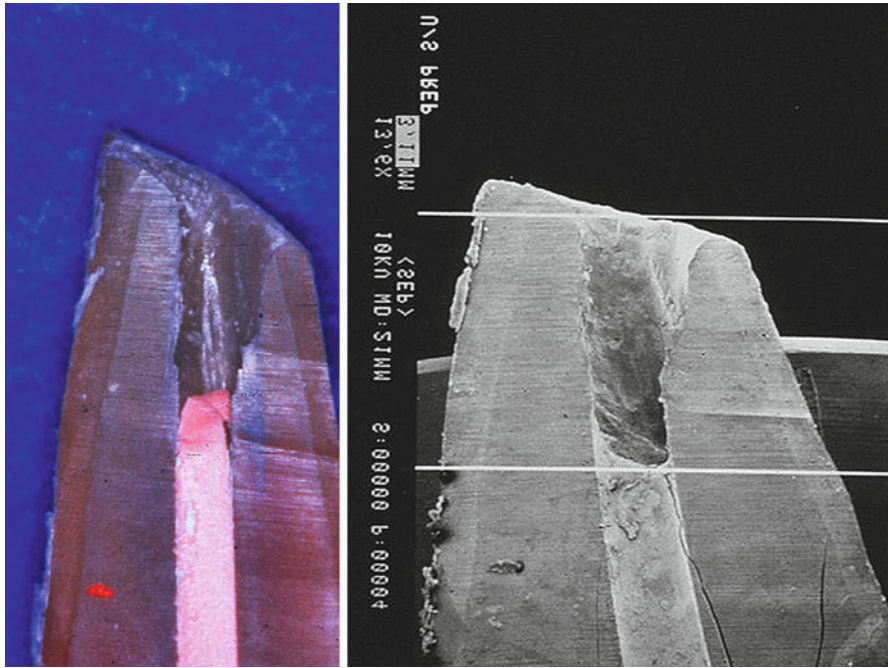


Fig. 10.10 Light-microscopic and scanning electron-microscopic images of a root after apicoectomy and preparation. The retrograde preparation must create a Class 1 cavity with clean walls and sufficient depth (Image courtesy Dr. M. Torabinejad)

introduced [17]. Low-power magnification (4×) should be used for microtip alignment with the long axis of the root (Fig. 10.11); poor alignments can produce root perforations. Medium-power magnification (10–16×) should be used for retrocavity preparation, while high-power magnification (20–25×) is used for the final inspection of the retrocavity.

Properly designed ultrasonic microtips, ideally with abrasive coating, should be used at the correct power setting and with adequate irrigation, in order to prevent microfractures at the tooth apex.

In order not to overly thin out the radicular wall, there should be a relationship between the size of the microtip and the wall thickness, so that thinner microtips are selected for buccal roots of upper molars and mesial roots of lower molars; conversely larger tips may be selected for palatal roots of upper molars and distal ones of lower molars (Fig. 10.12).

10.4.11 Drying of the Preparation (Medium-Power Magnification)

The retrocavity has to be cleaned and dried before filling it. Air can be used with the Stropko's syringe, except in a through-and-through bone defect, perforating the

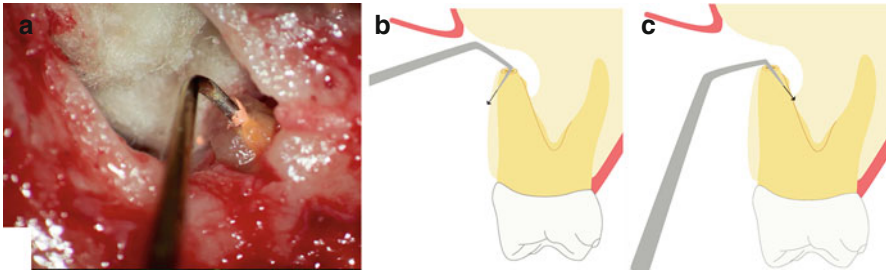


Fig. 10.11 (a) The ultrasonic tip must follow the canal trajectory to prevent thinning of radicular structure or perforation. Proper alignment of a zirconium oxide microtip in relation to the long root axis seen at low-power microscope magnification. (b, c) Incorrect angulations may lead to perforation toward the buccal or lingual direction

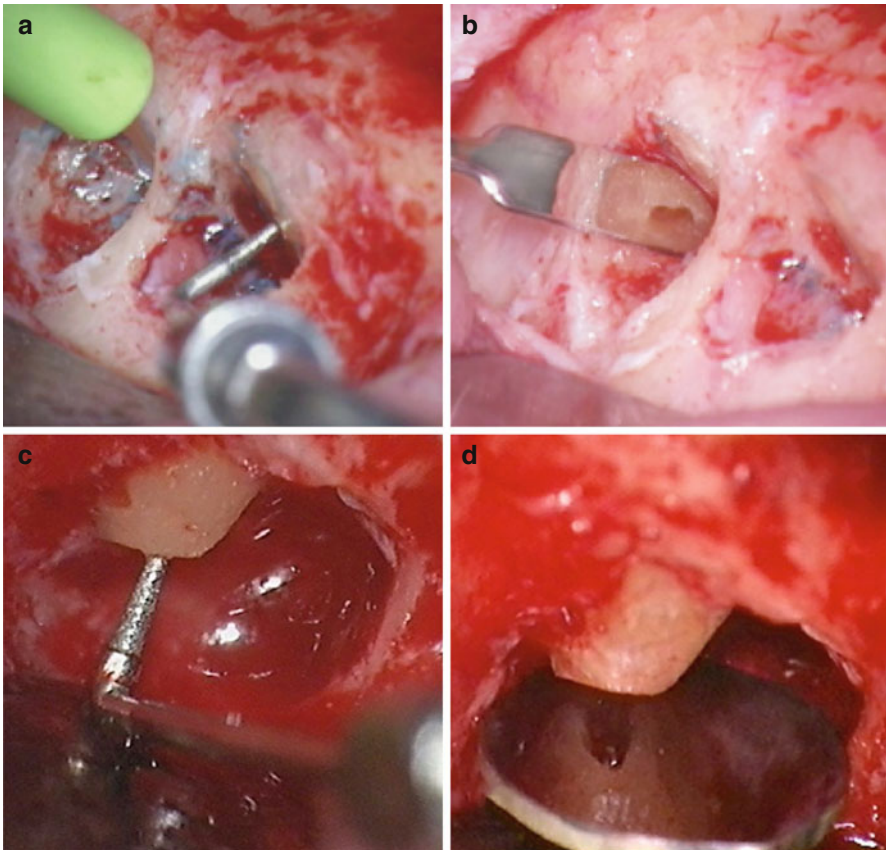


Fig. 10.12 Adequate retrograde tips must be selected to prepare different root cross-sections in molars (a, b) to avoid excessive thinning of the radicular structure and possible sequelae such as vertical root fracture. Round cross-sections such as in maxillary anteriors are amenable to larger retrograde tips due to the bulkier root cross-section (c, d) (Courtesy Dr. C. Peters)

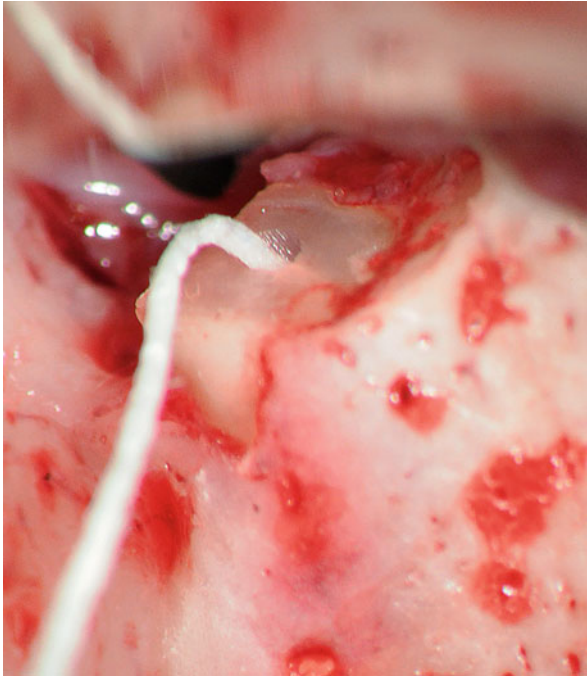


Fig. 10.13 After preparation, the cavity has to be dried. The use of paper points is not a reliable method for this, because residual blood, debris and moisture may prevent the filling material from forming an adequate retrocavity seal, which could cause the case to fail. But in a case like this one, with a perforation of the buccal bone plate and the sinus membrane too, air should not be blown into the retrocavity because it could introduce necrotic material from the retrocavity into the sinus cavity (Reprinted from Merino 2009, with permission)

maxillary sinus membrane where the use of paper points is mandatory (Fig. 10.13, see also bone defect classification in Box 10.1 and further below).

10.4.12 Retrograde Fill (Medium-Power Magnification)

A biocompatible material is used to produce a stable hermetic seal that can prevent the percolation of bacteria or their products between root canal system and periradicular tissues. Mineral-trioxide aggregate or MTA currently is the standard cement for retrograde fills because of its biocompatibility, sealing ability, and dimension stability (Fig. 10.14). Other bioceramic materials such as root repair putty (RRM) may provide similar healing rates [18, 19].

Cited disadvantages of MTA are that, although moisture is required for setting, during packing, isolation is critical because excess moisture can remove the filling from the retrocavity. Also, there are no final wash and polish phases and its setting time is very long while radiopacity is not high. Newer materials provide shorter setting times [19–22].

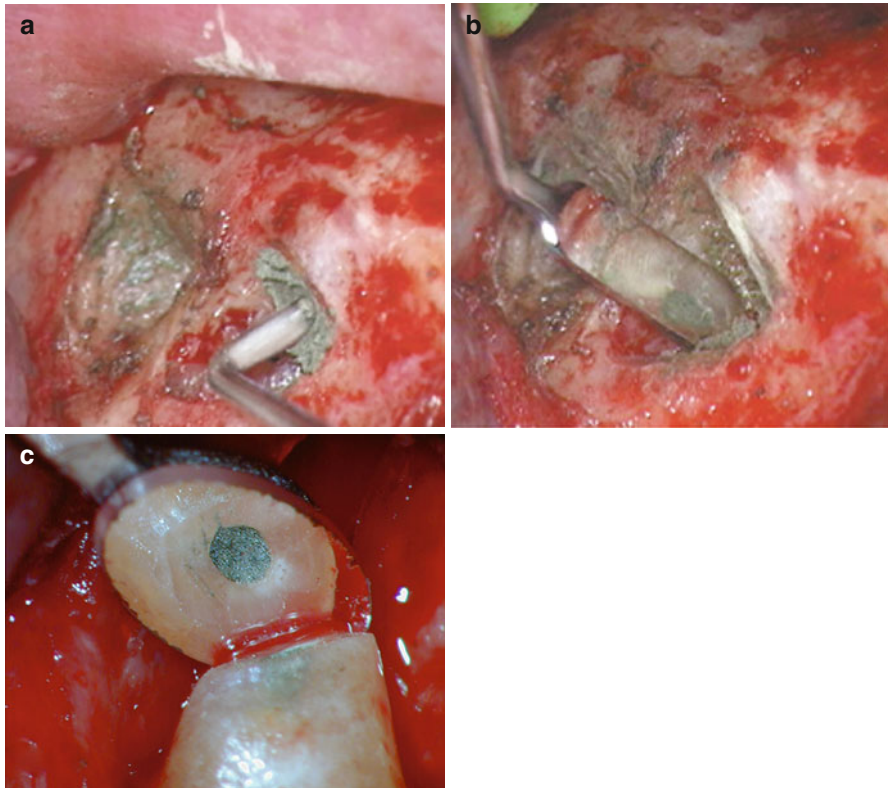


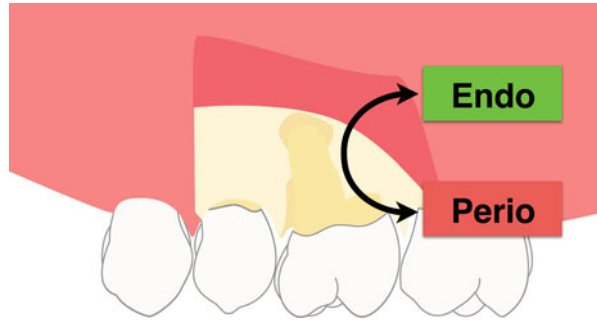
Fig. 10.14 (a) In a mesiobuccal root of a maxillary molar, placement of gray MTA (Dentsply) retrofill material using a microplugger. (b) Clinical view at medium-power magnification. (c) Apical view of a distal root of a maxillary molar after MTA retrofill at high-power magnification (a, b Courtesy of Dr. C. Peters)

10.5 Bone Defect Classification

Classic studies of endodontic surgery [23, 24] noticed that some failures originated not from the surgical technique itself, but from the size of the lesion and the configuration of cortical bone being perforated at the time of the surgery. Although every step of endodontic microsurgery has dramatically improved over the last few years, comparatively little attention has been paid to the bone defect topography underlying the soft tissue.

The shapes, sizes, and locations of the bone defects encountered during endodontic microsurgery differ substantially. However, bone defect topography dictates the long-term prognosis of microsurgery, independent of the perfectly performed steps of the microsurgery itself [3].

Fig. 10.15 In an apicomarginal bone defect we find two different areas: the endo (*green*) or periapical part and the perio part (*red*), or cervical part, which manifests as root dehiscence



The areas of interest in apical surgery can be divided into two major classes, the apical endodontic area (green) and the cervical or periodontal area (red) (Fig. 10.15). Then clinically osseous defects may be classified in endo lesions, endo-perio lesions, and a combination of them (see Box 10.1). Specific clinical conditions associated with these bone defects are listed below:

- **Small bone defects**
A localized defect around the periapical area, related to the main apical foramina or major accessory canals localized in the periapical area (Fig 10.16.).
- **Large bone defects**
These defects can cause collapse of the periosteum over the root surface; or if they are close to the bone crest, to invagination of the dentogingival junction into the furcation area (Fig. 10.16b).
- **Through-and-through bone defect**
There is a close relationship between the apices of the upper molars and the maxillary sinus. This is the reason for the fact that an inflamed sinus membrane is an early radiological sign for a periapical infection starting in the apical area [25] (Fig. 10.16c). Also, after the root canal treatment, the return to its normal width is an early sign of a successful treatment. The spatial position of the buccal roots (and their foramina with relation to the root apices) of the upper molars and the maxillary sinus inside the bone compartment, and the amount of bacterial toxins leached out to the periodontium, produces a simple bone lesion contained inside the bone compartment, or perforates one of the cortical bone or two cortical walls ending up in a complex osseous defect (Fig. 10.16d). Typically, through-and-through defects require a specific surgical strategy:

If the root canal treatment or retreatment cannot stop the infection, then the surgical intervention will consist of both on a standard endodontic microsurgery (to prevent the bacterial percolation) and the application of guided bone regeneration procedure, to regenerate the bony compartment.

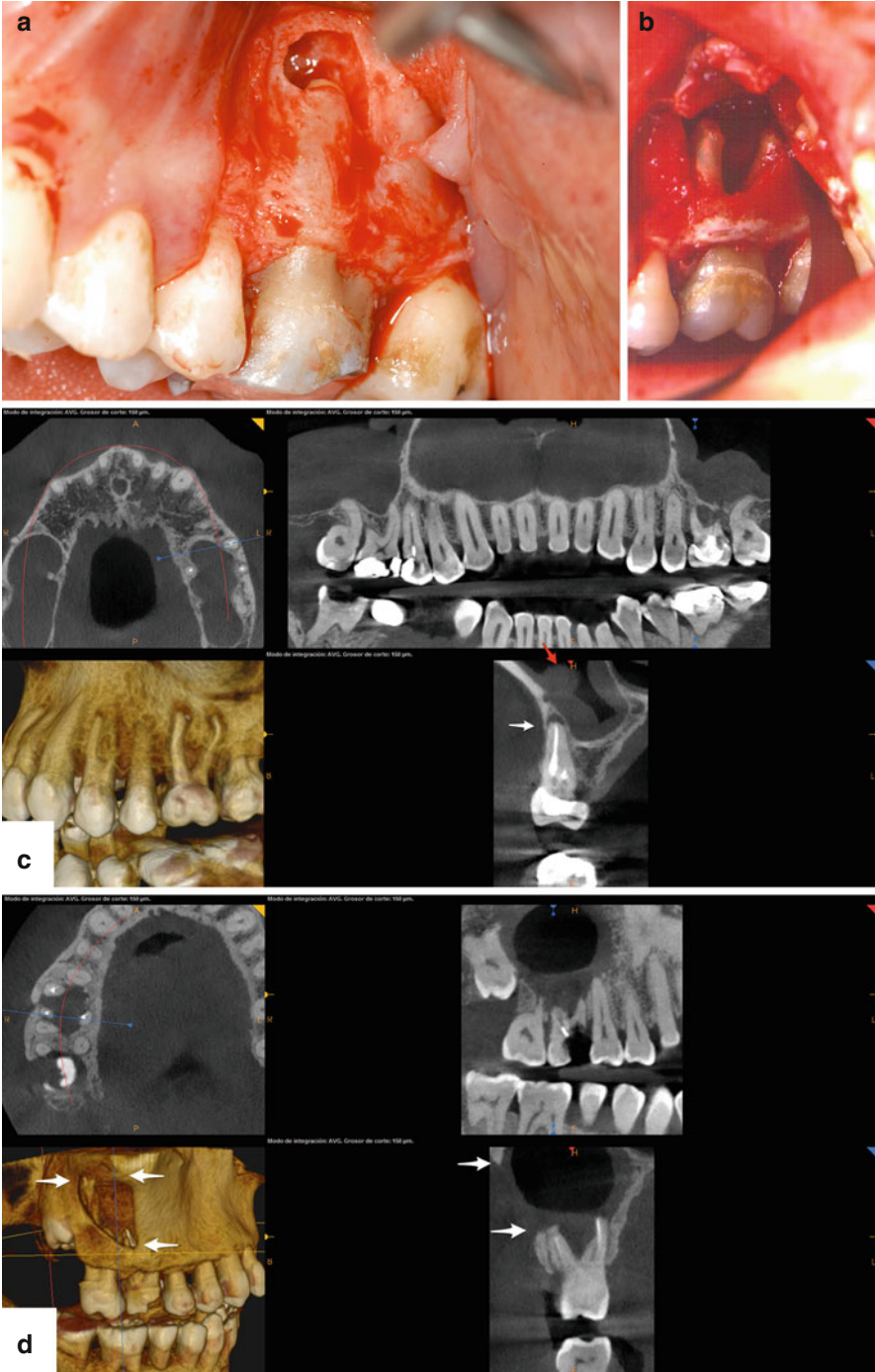


Fig. 10.16 (a) This small periapical and lateroradicular bone defect is far away from the bone crest. (b) This large periapical bone defect affects two roots and the furcation area. (c) Early periapical bone lesion on the mesiobuccal root of this first upper left molar with the cortical plate intact (*white arrow*). However, the sinus membrane is already inflamed (*red arrow*). (d) Right first maxillary molar with a large osseous defect requiring apical surgery. There is a large through-and-through bone defect with total destruction of the buccal and sinus bone cortical plates (*white arrows*) related to the tooth in question (Reprinted from Merino 2009, with permission)



If the root canal treatment or retreatment can stop the infection, then the final surgical intervention may consist of only guided bone regeneration, in order to reconstruct the lost periodontium.

- Apicomarginal bone defect
This condition can be seen as a mix of two bone defects: a periapical bone defect plus a total root dehiscence. Due to the structural differences between bone maxilla and mandible, root dehiscences in the maxilla tend to be larger overall and wider than the ones encountered in the mandible.

Although the diagnosis of an apicomarginal defect can be easily made after reflection of the mucoperiosteal flap, clinical and radiographic data obtained beforehand [20] can advance us to this point and allow the patient to be informed about the special surgery, increased budget, and longer surgery time.

The prognosis of endodontic microsurgery in the presence of an apicomarginal defect depends on the following:

- Crown/root ratio
- Width of the dehiscence at the bone crest
- Thickness of the proximal bone margins

Regardless, a successful treatment outcome depends more on the control of the epithelial downgrowth, that is, epithelial proliferation, at the crestal level than on the management of the periapical defect (see Fig. 10.15).

- Combination of Apicomarginal and Through-and-through defects
This condition can be seen frequently in maxillary molars (Fig. 10.17). A schematic approach to the diagnosis of bone defects can be seen in Box 10.1. Most of the lesions encountered need guided tissue regeneration techniques in order to be successfully managed.

Materials and techniques to treat the different bone defects are listed in Box 10.2. Autologous bone is the only material that promotes regeneration, while a xenograft material should be used as a space maintaining material while membranes prevent soft tissue interference in the bone regeneration process. All three materials must be used when the root is protruding out of the osseous envelope.

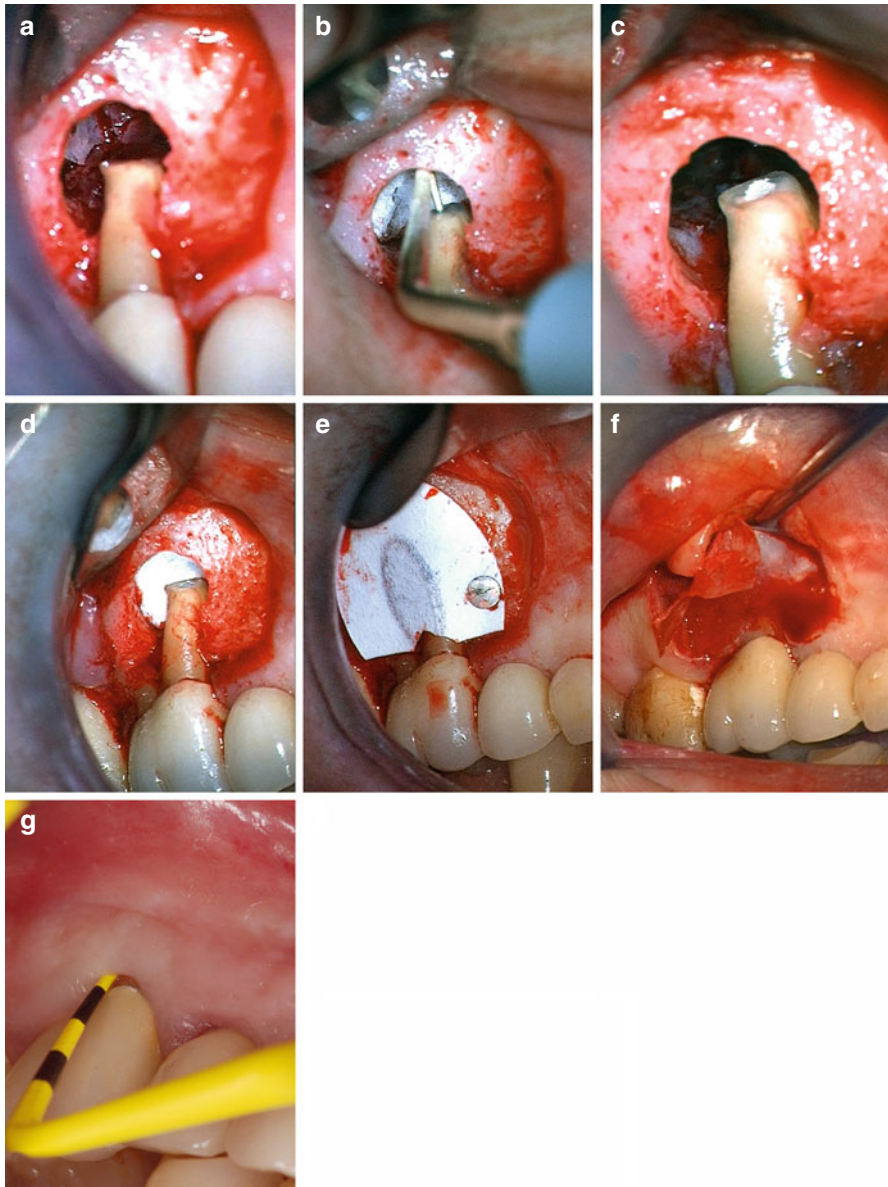


Fig. 10.17 (a) Apical surgery for the mesiobuccal root of a maxillary first molar. A total dehiscence of the mesiobuccal root was evident after raising the flap and the apical part of the bone defect has destroyed the cortical bone of the maxillary sinus floor, with bone visible in lower power magnification. (b) In order to prevent operational debris from getting into the sinus during retrograde preparation and fill, a collagen piece was inserted between the root apex and the sinus membrane. (c) Retrocavity was filled with SuperEBA (Bosworth) cement and the collagen piece was removed. (d) Before placement of a membrane, a new piece of collagen is inserted into the crypt. (e) A Gore-Tex nonresorbable membrane No. GT4, selected to function as an external barrier, was trimmed to adapt to the root dehiscence at the bone crest and fixed using a titanium tag. Bone chips were used to cover the root dehiscence and the membrane were fixed in its final position. (f) No dehiscence was detected in the area when titanium tags and membrane were removed. (g) Clinical condition and probing at a 5-year follow-up (Reprinted from Merino 2009, with permission)

Box 10.2. Treatment Techniques for Bony Defects

Extent of defect	Materials		GBR/membrane recommended
	Augmentation	Membrane	
Apical 1/3	No	Yes	No
Apical and middle 1/3	Bone xenograft	Yes	Resorbable, one side
Through-and-through	Variable	Yes	Resorbable, two sides
Apicomarginal			
- intraosseous; space-making	Autologous graft	Yes	Resorbable
- extraosseous; non-space-making	Autologous (first layer), xenograft (second layer)	Yes	Nonresorbable fixed

10.6 Intentional Replantation

Intentional replantation is defined as the “insertion of a tooth into its alveolus after the tooth has been extracted for the purpose of performing treatment, such as root-end filling (s) or perforation repair” [26]. This is not a mysterious or exotic procedure but a safe and standard clinical technique to retain an otherwise untreatable tooth, with a high success rate [27–31].

10.6.1 Potential Indications

- Difficult access, for example to apices of second or third mandibular molars is extremely difficult and apicoectomy is typically contraindicated (Fig. 10.18).
- Anatomical limitations, for example close proximity of the apices of premolars or molars to the inferior alveolar nerve (Fig. 10.18) or occasionally the maxillary sinus. Here, less experienced clinicians may choose intentional replantation instead of surgical standard approach.
- Difficult access to perforation or resorption areas.
- An intraradicular post cannot be removed neither nonsurgically nor surgically.
- Previously attempted and failing retreatment.
- Previous attempted and failing apicoectomy.
- Severe periodontal problem and/or removal of bone to gain surgical access, which would leave the patient with an untreatable periodontal problem.
- Patient limitations: Medical or geriatric patients who cannot cooperate during the surgery time.

10.6.2 Contraindications

- Medical history with anticoagulation medication or compromised healing.
- Nonrestorable tooth.
- Large periodontal lesions that compromise the tooth stability.
- Difficult extraction with high risk of bone cortical plate fracture.
- Root fracture during extraction leaving a poor crown-root ratio.

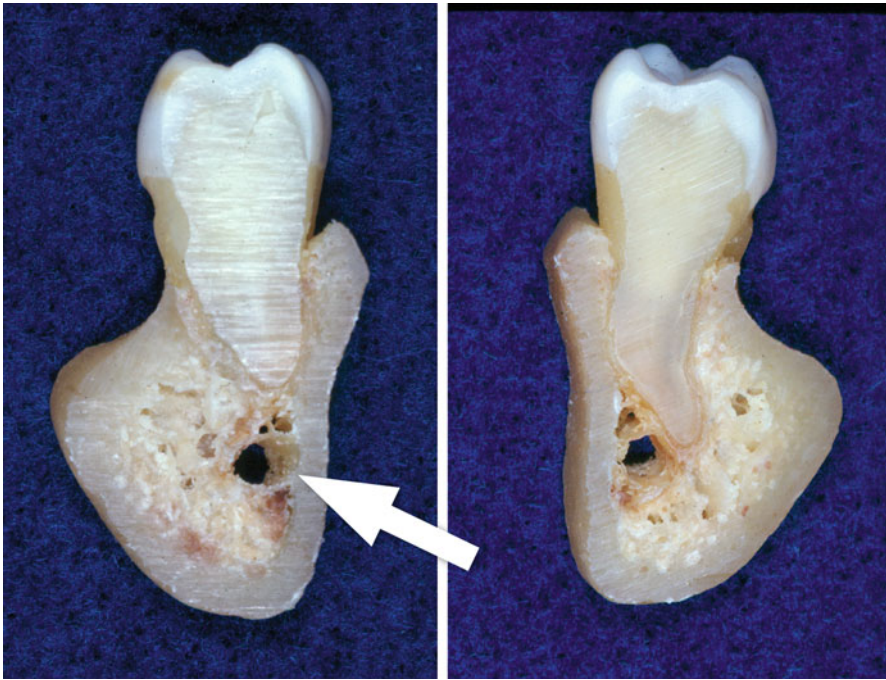


Fig. 10.18 (Left and right) The external oblique ridge complicates the surgical access to the apex of second and third molars. In many cases, the distance is too large for a buccal approach. Also structures such as the inferior alveolar never are close to the lingual cortical bone as shown in this specimen (Image courtesy of Dr. J. Gutmann)

10.6.3 Clinical Case Selection

Apart from the technique procedure itself, case selection is the most important factor in replantation prognosis. A clinical case is shown in Fig. 10.19; here the inability to debride and prepare via an orthograde approach necessitated the surgery and the access was too close to the mandibular canal.

10.6.4 Technique

Replantation is biologically based on the viability of the cells and fibers of the periodontal ligament after it's stay outside of the socket. It was previously believed that a tooth that was outside of the alveolar socket will suffer from resorption or ankylosis upon replantation but current data overwhelmingly show that this depends on the viability of the cells of the periodontal ligament: the longer the root is outside of the socket, the more readily resorption and ankylosis will occur [31–34]. This is the reason that, before the extraction, the clinical team must rehearse all the surgical steps, so that once the tooth has been removed, the procedure can be carried out efficiently and in minimum time [30].

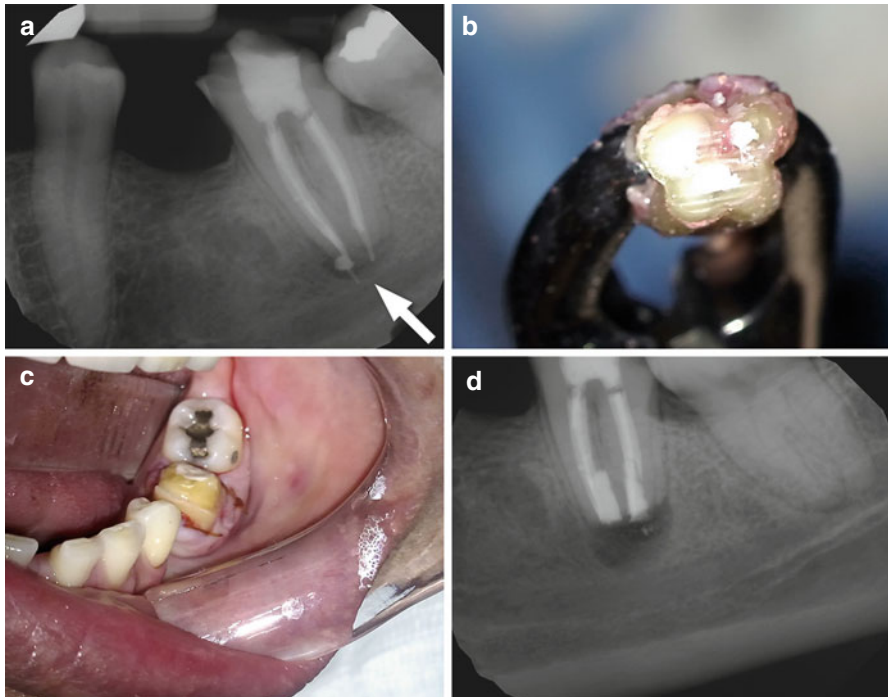


Fig. 10.19 (a) After crown preparation and root canal treatment with significant overextension of root canal filling, this patient complained about persistent pain. (b) During intentional replantation, the tooth was gently lifted out of the socket and retrograde prepared. Care was taken to keep the periodontal ligament moist and the retrograde cavities were filled with Root Repair Material (Brasseler). (c, d) Clinical and radiographic condition immediately after replantation. The postoperative course for this patient was uneventful

10.6.5 Recommendations

- Intentional replantation is the last resort to maintain a tooth; therefore, case selection is critical.
- Crown or root fracture is always a possibility of replantation procedure termination and the patient must be informed orally and in writing in the informed consent form.
- A fast procedure is significantly related to success. Therefore, “ergonomics is everything.”
- Gentle extraction without touching the root surface compressing neither of the alveolus walls promoted periodontal healing.
- The extraction forceps handles should be grabbed aided with a rubber band.
- Root inspection should be done at maximum-power magnification, and preparation and obturation of cavities at medium-power magnification.
- The tooth should be rinsed constantly with saline, serum, or tissue culture solution.

- Do not curette the socket, rather aspirate socket clot without touching the walls.
- The shorter the time the tooth is out of the socket, the better. Maximum extraoral time is about 5–10 min.
- A gentle reinsertion should be done. If there is too much pressure in any area, the periodontal fibers will lack vascularization and resorption will start.
- Rigid stabilization is typically not needed; if necessary, maximum duration will be 1 week's time.

As shown, the scope of contemporary apical microsurgery includes more than apicoectomies; however, procedures such as hemisections and root amputations have largely fallen into disfavor, since long-term outcomes do appear to compare favorably with implant therapy [35]. Regardless, the overall success rate of endodontic microsurgery is according to the literature and with modern techniques in the range of nonsurgical root canal treatment [4, 36].

References

1. Siqueira Jr JF. Aetiology of root canal treatment failure: why well-treated teeth can fail. *Int Endod J.* 2001;34:1–10.
2. Gorni FG, Gagliani MM. The outcome of endodontic retreatment: a 2-yr follow-up. *J Endod.* 2004;30:1–4.
3. Merino E. Endodontic microsurgery. Quintessence Pub; 2009; Chapter 6: Treatment of bone defects in apical microsurgery, Berlin. p. 176.
4. Setzer FC, Shah SB, Kohli MR, Karabucak B, Kim S. Outcome of endodontic surgery: a meta-analysis of the literature-part 1: comparison of traditional root-end surgery and endodontic microsurgery. *J Endod.* 2010;36:1757–65.
5. Patel S, Durack C, Abella F, Shemesh H, Roig M, Lemberg K. Cone beam computed tomography in endodontics-a review. *Int Endod J.* 2015;48:3–15.
6. Gutmann JL, Harrison JW. Flap design and incisions. In: *Surgical endodontics*. Boston: Blackwell; 1991. p. 162–75.
7. Carr G, Bentkover S. Surgical endodontics. In: Cohen S, Burns R, editors. *Pathways of the pulp*. St Louis: Mosby; 1998. p. 608–56.
8. Mörmann W, Meier C, Firestone A. Gingival blood circulation after experimental wounds in man. *J Clin Periodontol.* 1979;6:417–24.
9. Kim S. Principles of endodontic microsurgery. *Dent Clin North Am.* 1997;41:481–97.
10. Velvart P, Peters CI, Peters OA. Soft tissue management: suturing and wound closure. *Endod Top.* 2005;11:179–95.
11. Merino E. Endodontic microsurgery. Quintessence Pub; 2009; Chapter 3: Microsurgery step by step, Berlin. p. 51.
12. Arens DE, Adams WR, De Castro RA. Endodontic surgery. New York: Harper & Row; 1984. p. 102–32.
13. Peters LB, Wesselink PR. Soft tissue management in endodontic surgery. *Dent Clin North Am.* 1997;41(3):513–28.
14. Ohmori S, Kurata K. Experimental studies on the blood supply to various types of skin grafts in rabbits using isotope ³²p. *Plast Reconstr Surg.* 1960;25:547–55.
15. Patterson TJ. The survival of skin flaps in the pig. *Br J Plast Surg.* 1968;21:113–7.
16. Cambuzzi JV, Marshall FJ. Molar endodontic surgery. *J Can Dent Assoc.* 1983;1:61–6.
17. Wuchenich M, Torabinejad M. A comparison between two root end preparations techniques in human cadavers. *J Endod.* 1994;20(6):279–82.

18. Torabinejad M, Pitt Ford TR. Root end fillings materials: a review. *Endod Dent Traumatol.* 1996;12:161–78.
19. Chen I, Karabucak B, Wang C, Wang HG, Koyama E, Kohli MR, Nah HD, Kim S. Healing after root-end microsurgery by using mineral trioxide aggregate and a new calcium silicate-based bioceramic material as root-end filling materials in dogs. *J Endod.* 2015;41:389–99.
20. Rud J, Andreasen JO, Jensen JE. Radiographic criteria for the assessment of healing after endodontic surgery. *Int J Oral Surg.* 1972;1:195–214.
21. Rud J, Andreasen JO. A study of failures after endodontic surgery by radiographic, histologic and stereomicroscopic methods. *Int J Oral Surg.* 1972;1:311–28.
22. Molven O, Halse A, Grung B. Surgical management of endodontic failures: indications and treatment results. *Int Dent J.* 1991;41:33–42.
23. Skoglund A, Persson G. A follow-up study of apicoectomized teeth with total loss of the buccal bone plate. *Oral Surg Oral Med Oral Pathol.* 1985;59:78–81.
24. Hirsch JM, Ahlstrom U, Henrikson PA, Heyden G, Peterson LE. Periapical surgery. *Int J Oral Surg.* 1979;8:173–85.
25. Nunes CA, Guedes OA, Alencar AH, Peters OA, Estrela CR, Estrela C. Evaluation of periapical lesions and their association with maxillary sinus abnormalities on cone-beam computed tomographic images. *J Endod.* 2016;42:42–6.
26. American Association of Endodontists. Glossary of endodontic terms. 2015. Available from <http://www.nxtbook.com/nxtbooks/aae/endodonticglossary2015/>. Accessed 27 Feb 2016.
27. Koenig KH, Nguyen NT, Barkhordar RA. Tooth replantation of mandibular molars and premolars. *Gen Dent.* 1988;36:327–31.
28. Kinsbury BC, Weisenbaught JM. Tooth replantation of mandibular molars and premolars. *J Am Dent Assoc.* 1971;83:1053–7.
29. Lindeberg RW, Girardi AF, Troxell JB. Tooth replantation: management in contraindicated cases. *Compend Contin Educ.* 1986;7:248–58.
30. Caffesse RG, Nasjleti CE, Castelli WA. Long-term results after intentional tooth reimplantation in monkeys. *Oral Surg.* 1977;44:666–78.
31. Roos WJ. Tooth replantation: an alternative. *Compend Contin Educ.* 1985;6:735–9.
32. Andreasen JO. Relationship between cell damage in the periodontal ligament after replantation and subsequent development of root resorption: a time-related study in monkeys. *Acta Odontol Scand.* 1981;39:15–25.
33. Andreasen JO. Effect of extra-alveolar period and storage media upon periodontal and pulpal healing after replantation of mature permanent incisors in monkeys. *Int J Oral Surg.* 1981;10:43–53.
34. Andreasen JO. The effect of pulp extirpation or root canal treatment on periodontal healing after replantation permanent incisors in monkeys. *J Endod.* 1981;7:245–52.
35. Cho GC. Evidence-based approach for treatment planning options for the extensively damaged dentition. *J Calif Dent Assoc.* 2004;32:983–90.
36. Danin J, Strömberg T, Forsgren H, Linder LE, Ramsköld LO. Clinical management of non-healing periradicular pathosis. Surgery versus endodontic retreatment. *Oral Surg Oral Med Oral Pathol Oral Radiol Endod.* 1996;82:213–7.

Index

A

- Accessory canal, 18–20
- Accidental pulp exposure, 100, 103–104
- Adhesive dentistry, 174–175
- Ankylosis, 69–70
- Anterior superior alveolar (ASA), 81
- Anxiety, 36
- Apical periodontitis
 - asymptomatic, 214–215
 - inflammatory resorption, 68, 69
 - radiological signs, 216
 - success and failure
 - clinical decisions, 221–222
 - controversies, 217–218
 - indication, 216
 - local spread of disease, 219
 - meticulous analysis, 215–216
 - naturalist theory, 219–220
 - normativist theory, 219–220
 - patient values, 221
 - persistent pain, 218–219
 - prevalence, 218
 - radiographic evaluation, 217
 - systemic effects, 219
 - time factor, 216–217
 - triad of disease, illness, and sickness, 220–221
 - symptomatic, 215
 - tooth retention over time, 222–223
- Apicoectomy, 276–277
- ASA. *See* Anterior superior alveolar (ASA)

B

- Barrier-type technique, 262–264
- Bone defect classification
 - apical endodontic area, 283
 - apicomarginal bone defect, 285, 286
 - cervical/periodontal area, 283
 - large bone defects, 283–285

- shapes, sizes, and locations, 282
- small bone defects, 283–285
- through-and-through bone defect, 283–285
- treatment techniques, 285, 287

C

- Cardiac pain, 35
- Cement-dentinal junction (CDJ), 141
- Cemento-enamel junction (CEJ), 119–120
- Ceramics, 197–198
- Chlorhexidine (CHX), 148
- Chronic orofacial pain, 32
- Cold testing, 44
- Concomitant lesion, 40
- Cone beam computed tomography (CBCT), 49, 50, 53, 217
- C-shaped canal system, 20–21
- Cuspal fracture, 61–62

D

- Debridement
 - accessory anatomy, 151–152
 - apical size, 147
 - intracanal microorganisms, 146
 - irrigation, 148–149
 - NaOCl and CHX, 147–148
 - radicular walls, 148
 - smear layer, 150–151
 - systematic approach, 146–147
- Depression, 36
- Diagnosis
 - ankylosis, 69–70
 - cracked/fractured teeth, 62
 - craze lines, 59, 61
 - fractured cusp, 61–62
 - split tooth, 62
 - VRF, 63–65

- Depression (*cont.*)
- endodontic–periodontal lesion, 40–41
 - external surface resorption, 67
 - extraoral exam, 36–37
 - inflammatory resorption
 - apical periodontitis, 68, 69
 - cervical external root resorption, 67–68
 - irritation, 67
 - MIEARR, 68–69
 - root apex, 67, 68
 - internal resorption, 66
 - intraoral exam, 37–38
 - pathologies, external resorption, 66–67
 - patient interview
 - chief complaint, 29–30
 - dental history, 30
 - medical history, 30–31
 - periradicular test
 - biting test, 47–48
 - normal assessment, 59–61
 - percussion test, 47
 - pulpal testing
 - accuracy, 45–46
 - asymptomatic irreversible pulpitis, 55, 56, 58
 - dentin hypersensitivity, 55, 56, 58
 - endodontic therapy, 57, 58
 - EPT, 44–45
 - histological studies, 42–43
 - pulp necrosis, 57, 58
 - radiographic assessment, 59–61
 - reversible pulpitis, 55, 56, 58
 - symptomatic irreversible pulpitis, 57, 58
 - thermal testing, 43–44
 - radiography
 - abnormal structures, 53
 - bitewing radiographs, 48–49
 - CBCT, 49, 50, 53
 - children, 54–55
 - digital radiography, 49
 - mandibular first molar tooth, 51
 - maxillary antrum, 51, 52
 - radiolucent variations, 52
 - radiopaque variations, 52
 - structures, 49–50
 - restoration, 38–40
 - sinus tract, 41–42
 - tooth resorption, 65–66
- Digital technology, 175
- Distobuccal (DB), 7
- Distolingual root, 13–16
- E**
- Electric pulp testing (EPT)
 - diagnosis, 44–45
 - mandibular anesthesia, 78
- Endodontic microsurgery
 - apicoectomy, 276–277
 - bone defect classification
 - apical endodontic area, 283
 - apicomarginal bone
 - defect, 285, 286
 - cervical/periodontal area, 283
 - large bone defects, 283–285
 - shapes, sizes, and locations, 282
 - small bone defects, 283–285
 - through-and-through bone defect, 283–285
 - treatment techniques, 285, 287
- curretage, 275
- diagnosis, 270, 271
- drying preparation, 279, 281
- flap design
 - access cavity, 270–271
 - rectangular and triangular flaps, 271–272
 - rules of, 272–273
- flap elevation, 273, 274
- hemostasis, 275–276
- incision, 273, 274
- intentional replantation
 - clinical case, 288, 289
 - contraindications, 287
 - definition, 287
 - indications, 287, 288
 - recommendations, 289–290
 - technique, 288
- isthmus, 278
- osteotomy window, 274–275
- rationale for, 270
- retraction, 273, 275
- retrograde fill, 281–282
- root-end preparation, 278–280
- Endodontic treatment, 38–40
- Ethylenediamine tetraacetic acid (EDTA), 150–151
- F**
- Facial pain, 36
- First mesiobuccal (MB1)
 - canal, 10
- Flap design, 270–273

G

- Glide path preparation, 142
- Gutta-percha
 - filling, 156, 157, 159
 - master cones, 153–155
 - outcome, 134

H

- Headaches, 34
- Heat testing, 44
- Hemostasis, 275–276
- Herpetic neuritis, 35

I

- Inferior alveolar nerve (IAN), 78
- Inferior alveolar nerve block (IANB), 77–78
- Intentional pulp exposure, 100–101, 105–106
- Intentional replantation
 - clinical case, 288, 289
 - contraindications, 287
 - definition, 287
 - indications, 287, 288
 - recommendations, 289–290
 - technique, 288
- Intraligamentary (PDL) injection, 86–87
- Intraosseous injection (IO), 87–89
- Intrapulpal injection, 89–90
- Irreversible pulpitis
 - asymptomatic, 55, 56, 58
 - inflammation, 98
 - symptomatic, 57, 58
- Isthmus, 21–23, 278

J

- “J-shaped” radiolucency, 65

K

- K-files, 124, 142, 145, 254

L

- Lateral canals, 18–20, 151, 152
- Local anesthesia
 - checklist, 90
 - IANB injection, 85
 - inflammatory change, 76
 - intraosseous injection, 87–89

- intrapulpal injection, 89–90
- mandibular anesthesia
 - block technique, 78–80
 - compounds, 80
 - IANB, 77–78
- mandibular buccal infiltration injection, 85–86
- maxillary anesthesia
 - compounds, 82–83
 - infiltration technique, 81–82
- PDL injection, 86–87
- periapical changes, 76
- pulpal anesthesia, 83–84
- supplemental anesthetic techniques, 84
- topical anesthesia, 76–77

M

- Mandibular anesthesia
 - block technique, 78–80
 - compounds, 80
 - IANB, 77–78
- Mandibular molars
 - accessory and lateral canals, 18–20
 - apical ramifications, 18–20
 - C-shaped canal system, 20–21
 - danger zone, 12, 13
 - distal root, 16, 18
 - distolingual root, 13–16
 - intra canal communications, 21–23
 - isthmi, 21–23
 - middle mesial root canal, 16–18
- Maxillary anesthesia
 - compounds, 82–83
 - infiltration technique, 81–82
- Maxillary molars
 - MB1 canal, 10
 - MB2 canal
 - CBCT imaging, 9
 - challenge, 11
 - cross-sectional shape, 11, 12
 - C-shaped canal system, 11
 - distobuccal, 7
 - micro-computed tomography, 6–7
 - occurrence, 11
 - orifice, 10
 - prevalence, 6, 9
 - pulp horns and pulp chamber, 7, 8
 - ultrasonic tips/long-shank round burs, 10
 - MB3 root, 10, 11
- Middle superior alveolar (MSA), 81

- Mineral trioxide aggregate (MTA), 263–265
- Molar access
- CEJ, 120, 129
 - locating canal orifices, 121
 - mandibular first molar
 - distal root, 124–126
 - lingual and buccal canal walls, 126–127
 - mesial root, 124–127
 - three-rooted configuration, 127
 - mandibular second molars, 127–128
 - maxillary first molars
 - blockage or transportation, 124
 - distobuccal canal entrance, 123
 - identification and instrumentation, 125
 - mesiobuccal canal entrance, 123
 - palatal canal entrance, 123
 - root morphology, 124
 - maxillary second molars, 124
 - patient-specific variables, 118
 - restorations, 128–129
 - root canal system anatomy, 128
 - straight-line access, 121–123, 125–127, 129
 - tooth-specific variables, 118
- Molar root canal anatomy
- classification, 2–5
 - components, 2–4
 - intraradicular microflora, 2
 - kidney-shaped roots, 3–4
 - mandibular molars
 - accessory and lateral canals, 18–20
 - apical ramifications, 18–20
 - C-shaped canal system, 20–21
 - danger zone, 12, 13
 - distal root, 16, 18
 - distolingual root, 13–16
 - intra canal communications, 21–23
 - isthmi, 21–23
 - middle mesial root canal, 16–18
 - maxillary molars (*see* Maxillary molars)
 - nickel-titanium instruments, 4–5
- Multiple idiopathic external root resorption (MIEARR), 68–69
- Muscle disorder pain, 33
- N**
- Neuropathic pain, 34–35
- Non-odontogenic pain
- cardiac pain, 35
 - muscular, 33
 - neoplasia, 35–36
 - neuropathic pain, 34–35
 - neurovascular, 34
 - non-somatoform, 36
 - vs. odontogenic pain, 31–33
 - sinus/nasal structures, 33
- Non-somatoform pain, 36
- Nonsurgical retreatment
- altered root canal morphology, 243
 - bypassing ledges
 - buccolingual projection, 252
 - canal entrance, 252, 253
 - C+Files, 254
 - false canal, 249–250
 - false pathway, 253–254
 - instrument tip, 252–253
 - mesial canal, 254
 - proximal projection, 252
 - three-dimension, 251–252
 - cause of failure, 241–242
 - coronal seal
 - lack of, 244, 246
 - loss of, 240, 242
 - definition, 234, 235
 - eliminating ledges, 254–255
 - epidemiological study, 237–238
 - etiology, 250
 - filling material removal, 247–248
 - implantology, 237
 - inadequate root canal filling, 238
 - incomplete treatment, 238, 239
 - instrument fragment removal
 - broken instrument, 256–258
 - prognosis, 256
 - re-intervention, 256
 - staging platform, 258
 - straight-line radicular access, 256, 258
 - locating ledges, 251
 - maxillary molar, 234, 236
 - microtube removal methods, 258–259
 - operating microscope, 246
 - pastes, 248
 - patient expectations, 246
 - perforation repair
 - apical one-third, 260–261
 - collacote, 262–264
 - coronal third and bifurcations, 261–262
 - level, location, size and shape, and time, 260
 - materials and techniques, 262
 - middle one-third, 261
 - MTA, 263–265
 - periodontal involvement, 244, 245
 - periradicular radiolucency, 242
 - planning, 238
 - professional experience, 246

- satisfactory quality, 242–243
 sealers, 248
 second mesiobuccal (MB2) canal,
 234–235, 237
 silver point removal, 249
 vs. surgical retreatment, 247
 suspected vertical fracture, 244
 typical situation, 234, 235
 ultrasonic techniques, 258
 vertical fractures, 240, 241
- O**
- Obturation
 canal drying and sealer application,
 154–156
 factors, 152–153
 filling (*see* Root canal filling)
 master cones, 153–155
 materials and techniques, 152–154
 quality, 159–160
 timing, 153, 154
- Outcome assessment
 apical periodontitis (*see* Apical
 periodontitis)
 clinical course, 211–212
 clinical studies, 229
 natural history, 210–211
 pathosis, 208
 prognosis, 208–210
 pulp necrosis, 214–215
 retreatment
 accessibility, 224, 226–227
 bone destruction, 223
 clinician and patient preferences, 225
 cost of treatment, 225
 restorative requirements, 224–225
 surgical/nonsurgical retreatment, 223
 technical quality, 223–224
 technological development, 225, 227
 tooth-supporting bridge, 228
 symptomatic pulpitis, 214
 vital pulp therapies
 indirect pulp capping, 212
 primary dentin, 212
 pulp exposure, 213–214
 stepwise excavation, 212
- P**
- Percussion test, 47
 Periapical index (PAI), 218
 Posterior superior alveolar (PSA), 81, 82
 Pulpal anesthesia, 83–84
- Pulpal testing
 accuracy, 45–46
 asymptomatic irreversible
 pulpitis, 55, 56, 58
 dentin hypersensitivity, 55, 56, 58
 endodontic therapy, 57, 58
 EPT, 44–45
 histological studies, 42–43
 pulp necrosis, 57, 58
 radiographic assessment, 59–61
 reversible pulpitis, 55, 56, 58
 symptomatic irreversible pulpitis, 57, 58
 thermal testing, 43–44
- Pulp necrosis, 214–215
- Q**
- QuickSleeper system, 87, 88
- R**
- Radix entomolaris, 13–16
 Resin-based composites, 197, 199
 Restoration, 171–174
 adhesive dentistry, 174–175
 “bio”-materials, 176
 bonding system
 cast post, 185–188
 clinical evidence, 192–193
 fiber post, 185–188
 limitation, 184–185
 metal post, 186
 retention, 189–190
 cuspal coverage, 194–196
 digital technology, 175
 direct/indirect
 restoration, 197–199
 endocrown
 advantages, 192
 bond strength, 190–191
 clinical study, 191–192
 pulp chamber, 190, 191
 in vitro data, 190
 full-crown, placement
 of, 193–194
 multi-unit restorations, 200–201
 repair of, 199–200
- Reversible pulpitis, 55, 56, 58, 98
 Root canal filling
 apical portion
 lateral compaction, 155–157
 vertical compaction, 156–158
 completion, 157–159
 paste, 248

S

- Second mesiobuccal (MB2) canal
 - CBCT imaging, 9
 - challenge, 11
 - cross-sectional shape, 11, 12
 - C-shaped canal system, 11
 - distobuccal, 7
 - micro-computed tomography, 6–7
 - occurrence, 11
 - orifice, 10
 - prevalence, 6, 9
 - pulp horns and pulp chamber, 7, 8
 - ultrasonic tips/long-shank round burs, 10
- Shaping
 - analysis, 136
 - canal preparation, 135
 - canal scouting, 136–137
 - coronal modifications, 137–138
 - desired size, 142–143
 - foramen, apical adjustment, 144–146
 - glide path preparation, 142
 - high complexity, 162–164
 - low complexity, 160–161
 - moderate complexity, 161–162
 - patency
 - advantages, 139
 - conditions, 140–141
 - recommendations, 138–139
 - watch-winding, 139–140
 - working length, 141–142
- Sinus tract, 41–42
- Sodium hypochlorite (NaOCl), 147–148
- Somatoform pain, 36
- Stabident system, 88–89

T

- Temporomandibular pain, 33
- Tertiary dentinogenesis, 96–97
- Third mesiobuccal (MB3) root canal, 10, 11
- Tooth resorption, 65–66
- Topical anesthesia, 76–77
- Trigeminal neuralgia, 34–35

V

- Vertical root fracture (VRF)
 - vs. advanced crack, 63–65
 - definition, 63
- Vertucci's classification, 2–3
- Vital pulp therapy
 - apexogenesis, 95
 - capping agents, 103–104
 - classification, 94
 - controversy, 94
 - deep caries, 94, 95
 - direct pulp capping Class I, 100, 103–104
 - direct pulp capping Class II, 100–101, 105–106
 - “emergency” pulpotomy, 103
 - factors controlling prognosis, 110–111
 - “full” pulpotomy, 103, 106–107
 - indications, 99, 111–112
 - indirect pulp therapy
 - partial excavation, 109–110
 - stepwise exaction, 107–109
 - inflammation
 - clinical evaluation, 98–99
 - and tertiary dentin, 97
 - outcome assessment
 - indirect pulp capping, 212
 - primary dentin, 212
 - pulp exposure, 213–214
 - stepwise excavation, 212
 - “partial” pulpotomy, 102, 105–106
 - stepwise exaction, 107–108
 - tertiary dentinogenesis, 96–97

W

- Working length (WL), 141–142

X

- X-Tip system, 87–89